Billedanatomi: Truncus

Michel Bach Hellfritzsch
Overlæge
Røntgen og Skanning, Aarhus Universitetshospital



1

Truncus

Del 1:

Introduktion til columna
og columna cervicalis

2

Hvirvlen

3

Hvirvlens opbygning

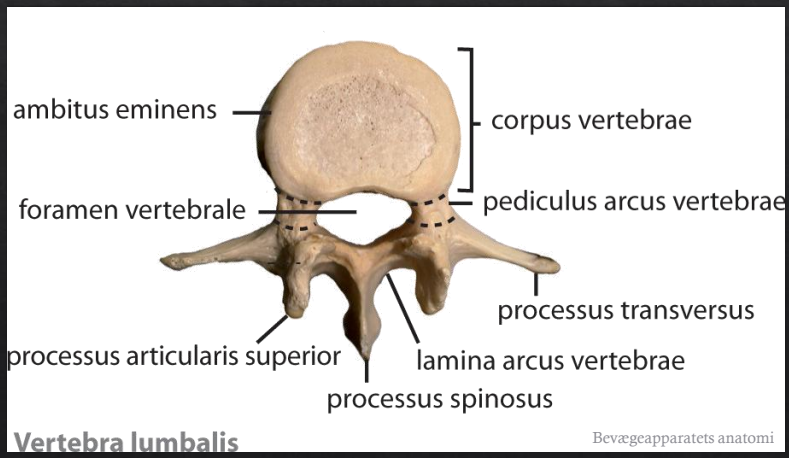

4

CT skanning

L3

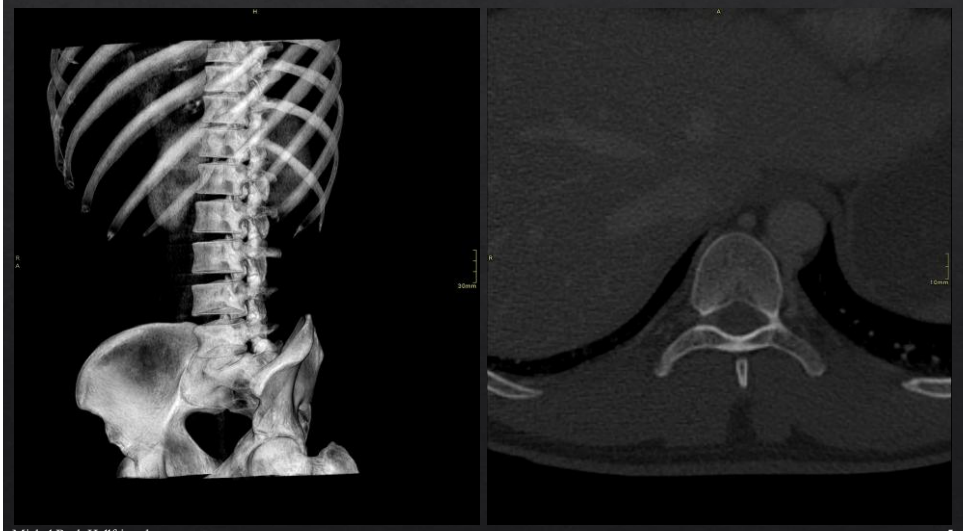

5

Columna vertebralis krumninger

Overordnet

6

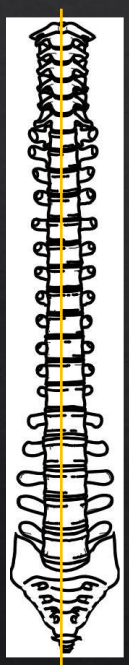

Frontalt ses ingen krumning

Thorakal kyfose

(Primær)

Hvorfor er kyfoserne primære?

Sakral kyfose

(Primær)



Cervikal lordose

(Sekundær)

Lænde lordose

(Sekundær)

Michel Bach Hellfritzsch 7

7

Oversigt over abdomen, kvinde 32 år med gemelli

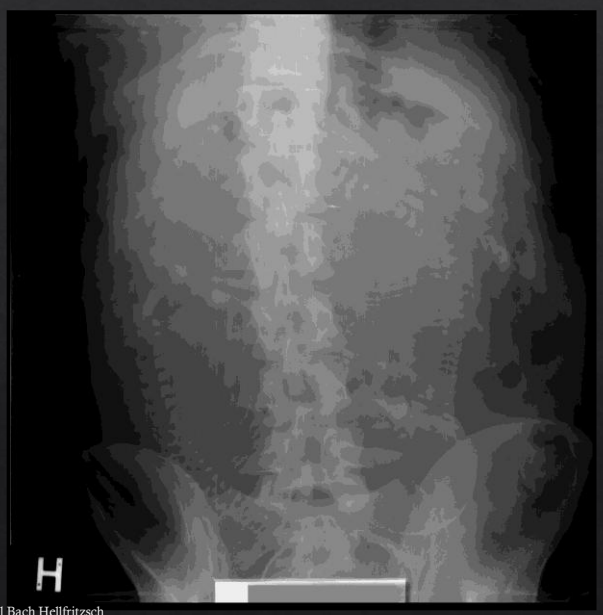

Kyfoser:
Primære

Michel Bach Hellfritzsch 8

8

Oversigt over abdomen, kvinde 32 år med gemelli

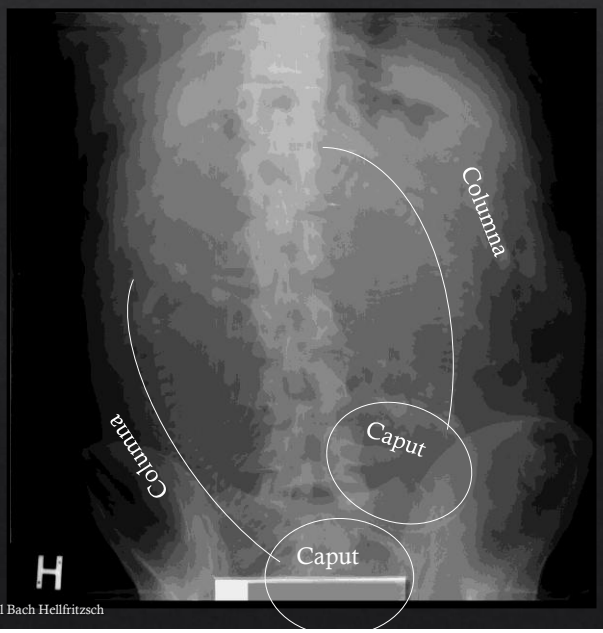

Kyfoserne er primære, idet fosteret i livmoderen ligger rullet sammen, således columna udgør en lang kyfose.
På billedet til venstre ses tvillinger (gemelli), med markering af hovedet og columna.
Knoglerne i arme og ben kan også ses.
Røntgenbilledet er fra før ultralyd var tilgængelig, denne undersøgelse udføres ikke længere hos gravide.

9



7 mdr. gammel pige.

6 uger: Barnet smiler

9-10 uger: Ruller fra siden til ryggen

3-4 måneder: Løfter hovedet og skuldrene, når det ligger på maven

6 måneder: Sidder med støtte

9 måneder: Kan sætte sig op

9-10 måneder: Siger enkle tostavelsesord som "mor" og "far"

12 måneder: Forstår enkle kommandoer

12 måneder: Kan stå uden støtte i et sekund eller to

18 måneder: Forsøger at spise med ske

18 måneder: Går uden hjælp

18 måneder :Kan stable 3-4 klodser

2-3 år: Kan have kontrol over urin og afføring

3 år: Taler i enkle sætninger

3 år: Klæder sig af og på med lidt hjælp

5 år: Kan tegne en figur med hoved, krop, arme og ben

https://www.sundhed.dk/borger/patienthaandbogen/boern/sygdomme/vaekst-og-udvikling/boerns-udvikling-milepaele/

10

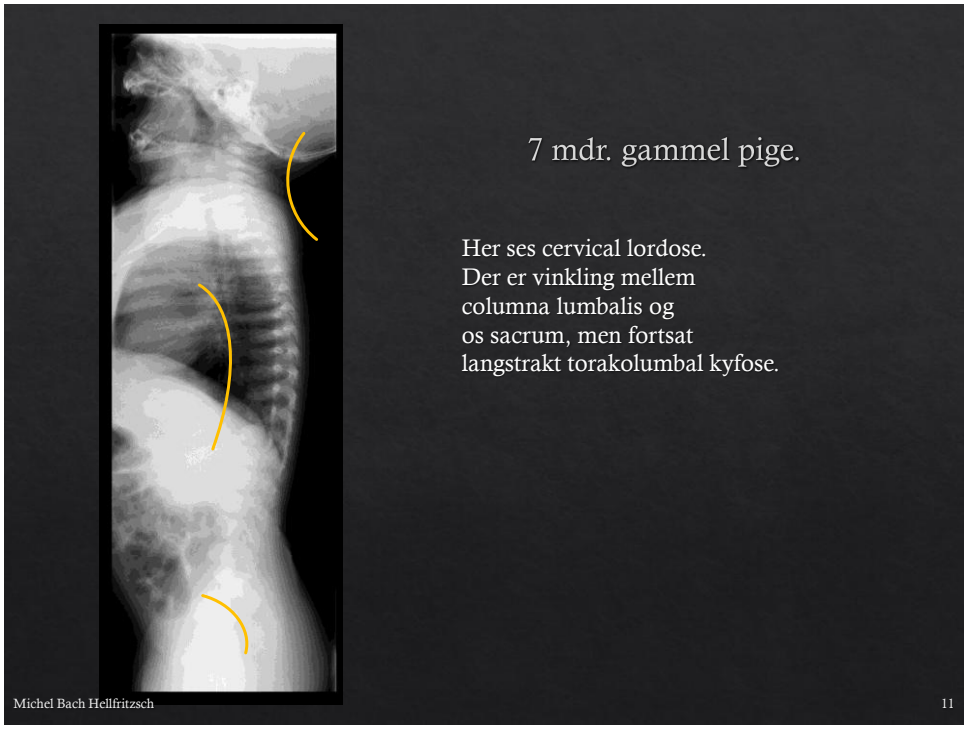
7 mdr. gammel pige.
Her ses cervical lordose.
Der er vinkling mellem
columna lumbalis og
os sacrum, men fortsat
langstrakt torakolumbal kyfose.
Michel Bach Hellfritzsch
11

11

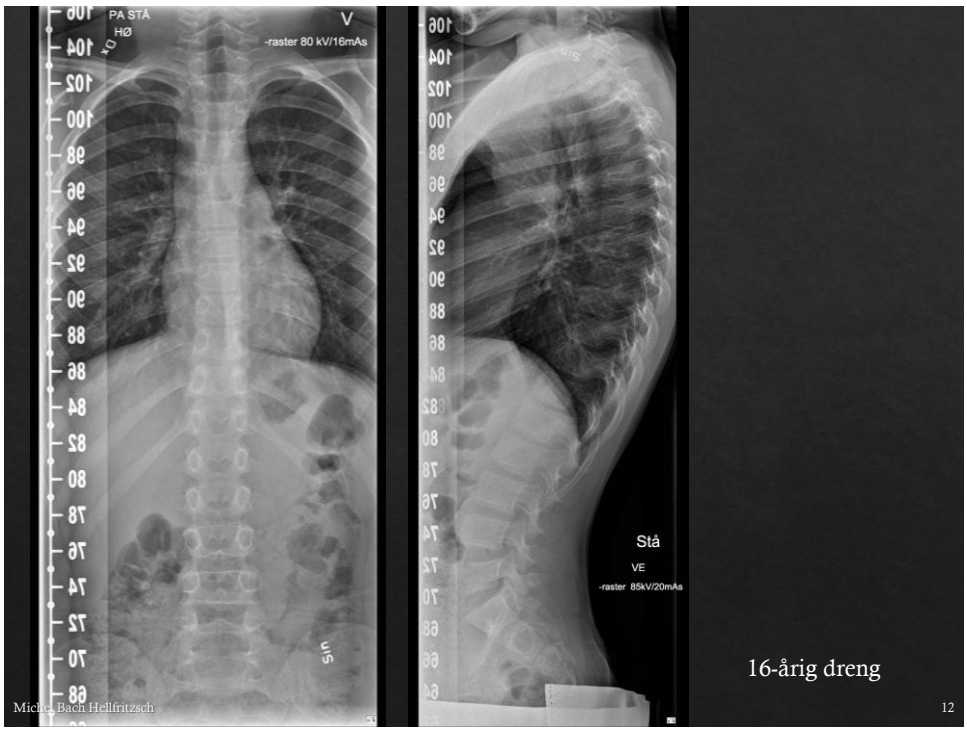
PA STÅ
HØ
V
-raster 80 kV/16mAs
Stå
VE
-raster 85kV/20mAs
16-årig dreng
Michel Bach Hellfritzsch
12

12

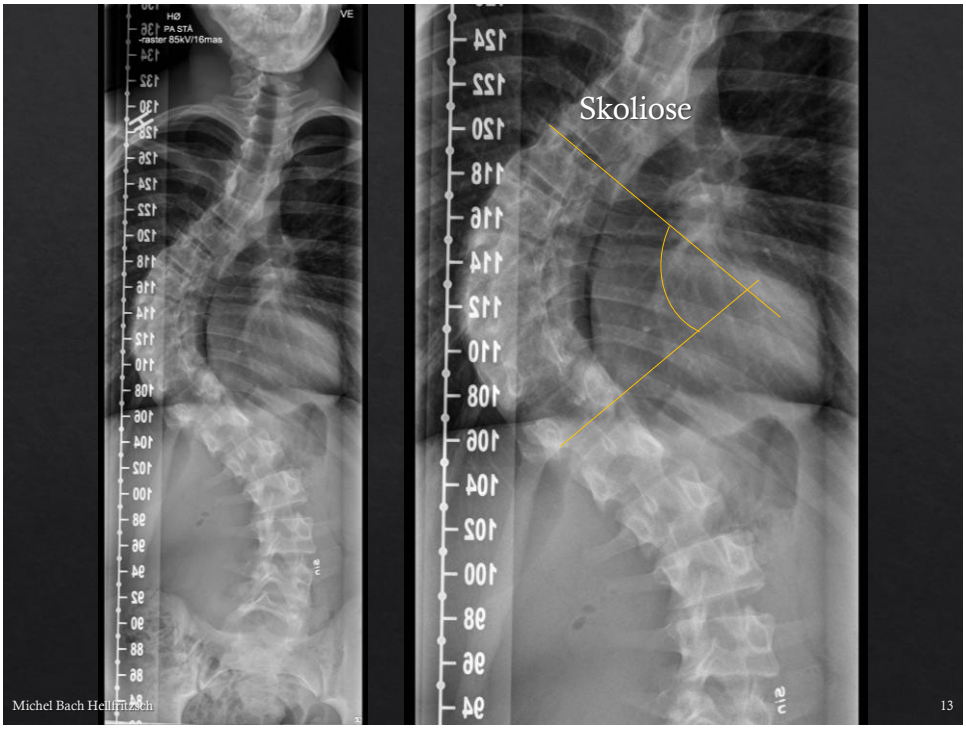
Skoliose
Michel Bach Hellfritzsch
13

13

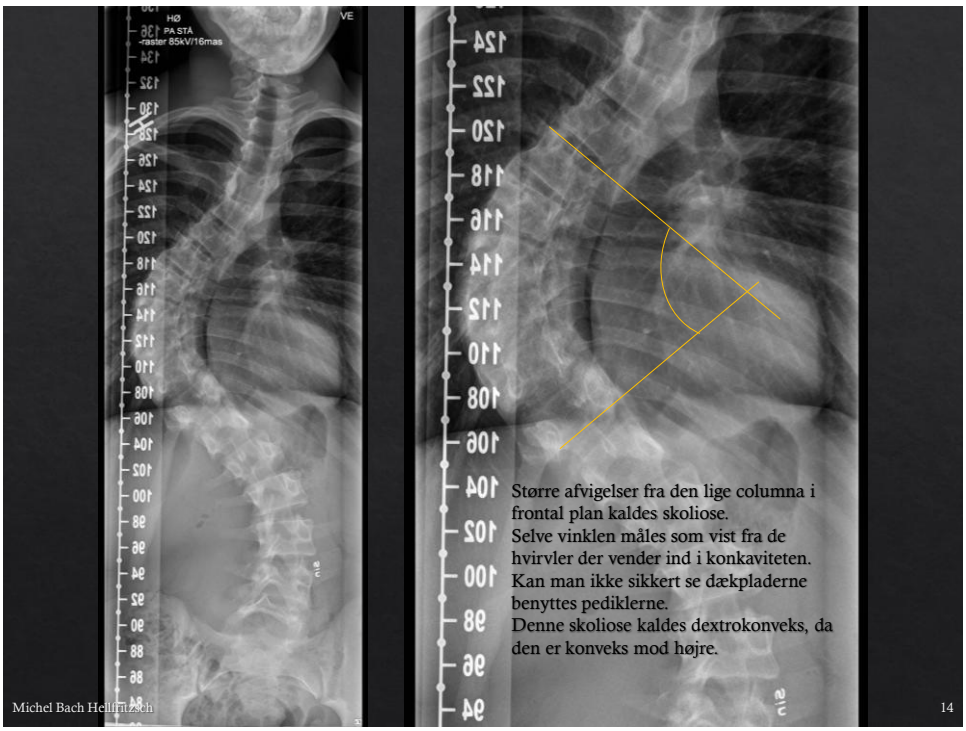
Større afvigelser fra den lige columna i frontal plan kaldes skoliose.
Selve vinklen måles som vist fra de hvirvler der vender ind i konkaviteten.
Kan man ikke sikkert se dækpladerne benyttes pediklerne.
Denne skoliose kaldes dextrokonveks, da den er konveks mod højre.
Michel Bach Hellfritzsch
14

14

Columna vertebralis

Hvivlernes udvikling

15

Udvikling

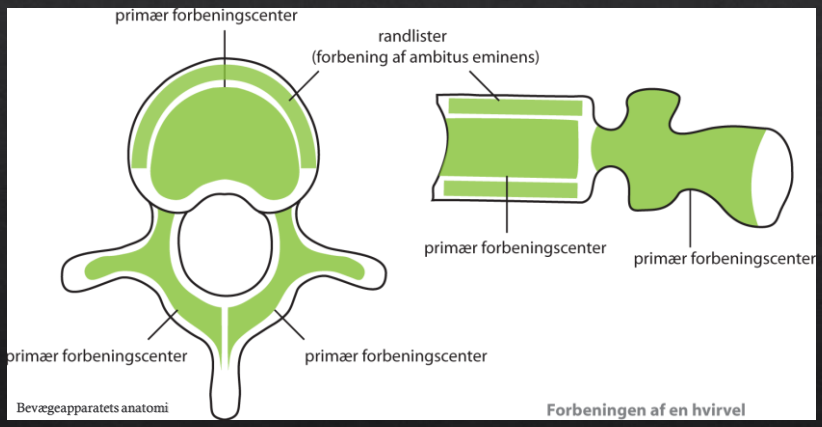

16


6 mdr. gammel pige.
Michel Bach Hellfritzsch
17

17


6 mdr. gammel pige.
Arcus anterior atlantis er endnu ikke ossificeret hos dette barn. Det er den hos 20% ved fødslen og hos resten sker det i løbet af det første leveår
C1
C2
C3
C4
C5
Dens axis endnu ikke fusioneret med corpus af C2
Michel Bach Hellfritzsch
18

18

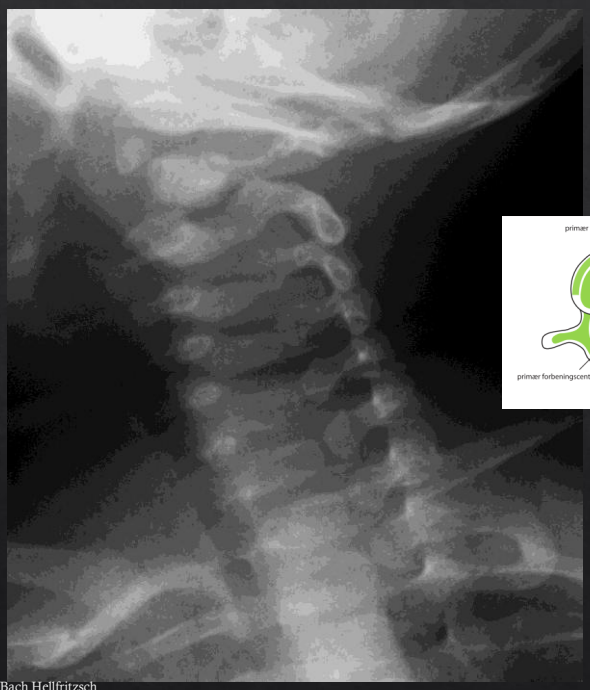

7 mdr. gammel pige.

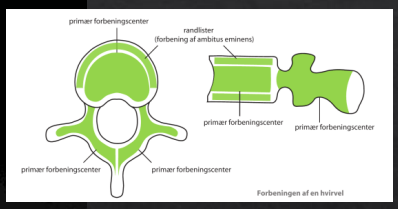

Bevægeapparatets anatomi, 13. udg.

19

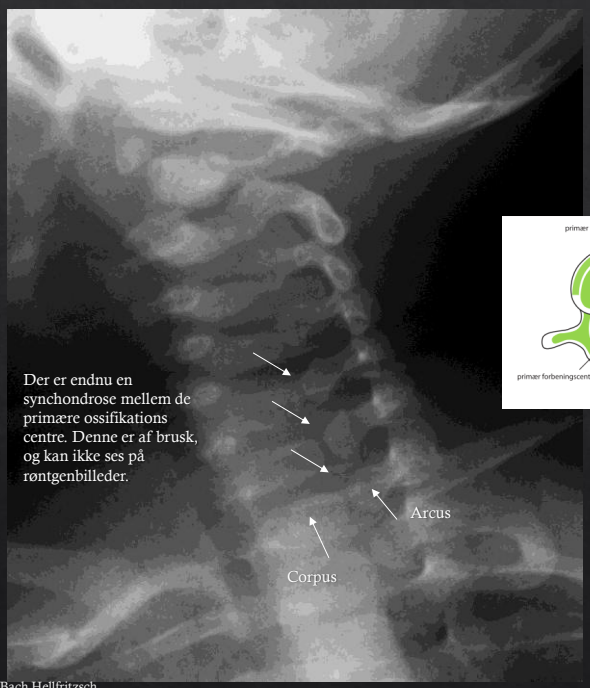

7 mdr. gammel pige.

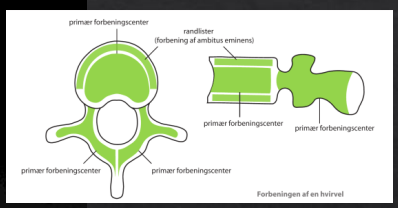

Bevægeapparatets anatomi, 13. udg.

Der er endnu en synchondrose mellem de primære ossifikations centre. Denne er af brusk, og kan ikke ses på røntgenbilleder.

Arcus

Corpus

20

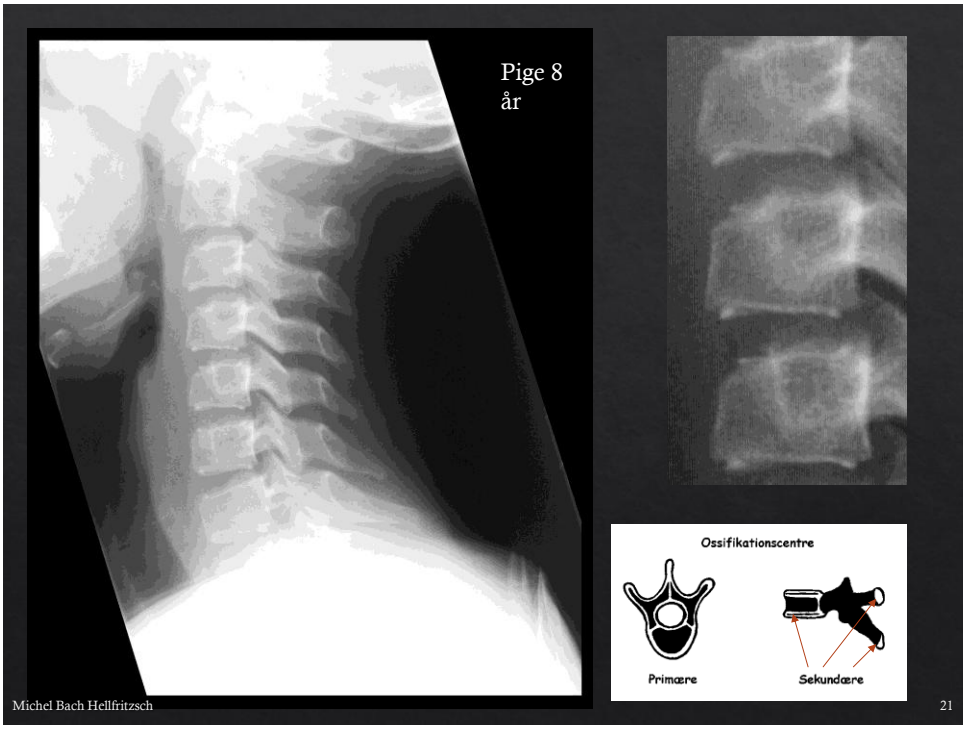
Pige 8 år
Ossifikationscentre
Primære
Sekundære
Michel Bach Hellfritzsch
21

21

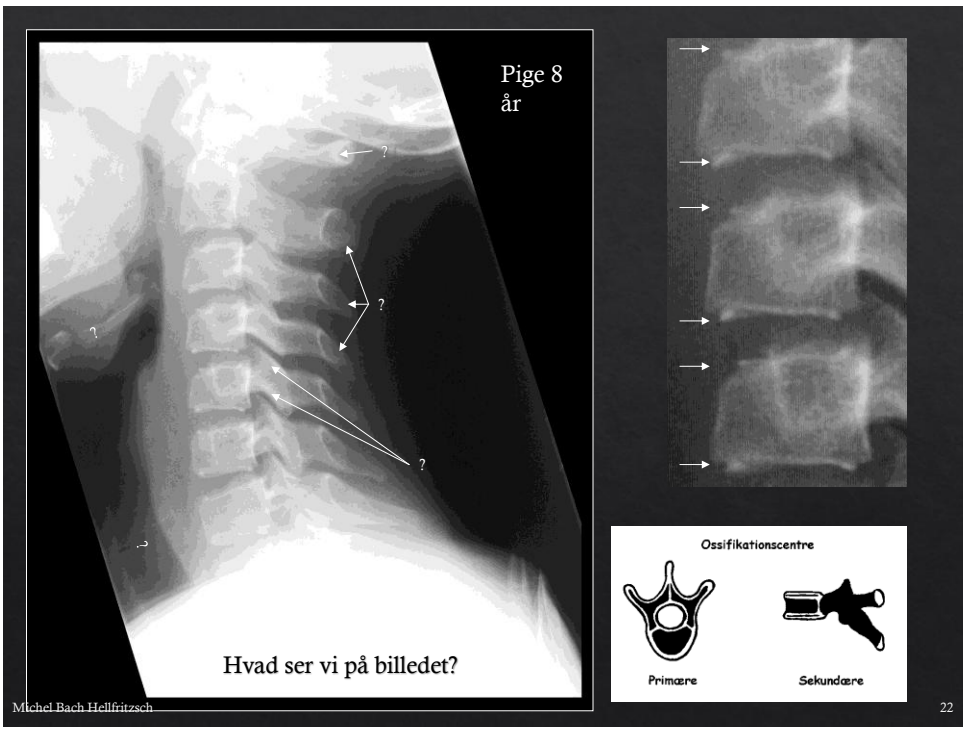
Pige 8 år
Hvad ser vi på billedet?
Ossifikationscentre
Primære
Sekundære
Michel Bach Hellfritzsch
22

22

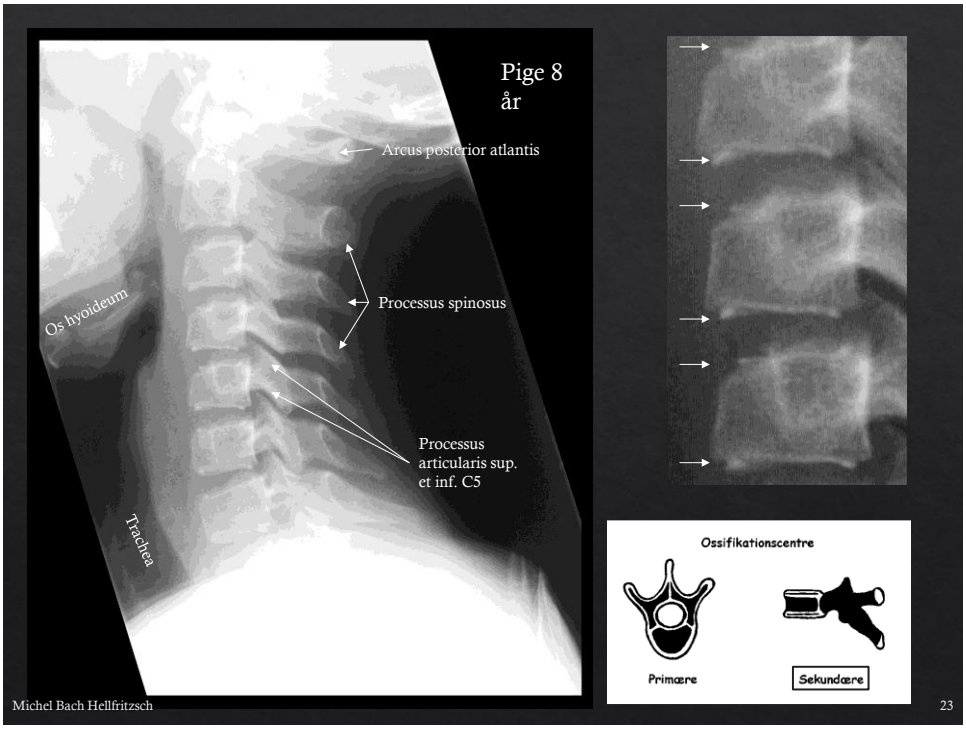
Pige 8 år
Arcus posterior atlantis
Os hyoideum
Processus spinosus
Processus articularis sup. et inf. C5
Trachea
Ossifikationscentre
Primære
Sekundære
Michel Bach Hellfritzsch
23

23

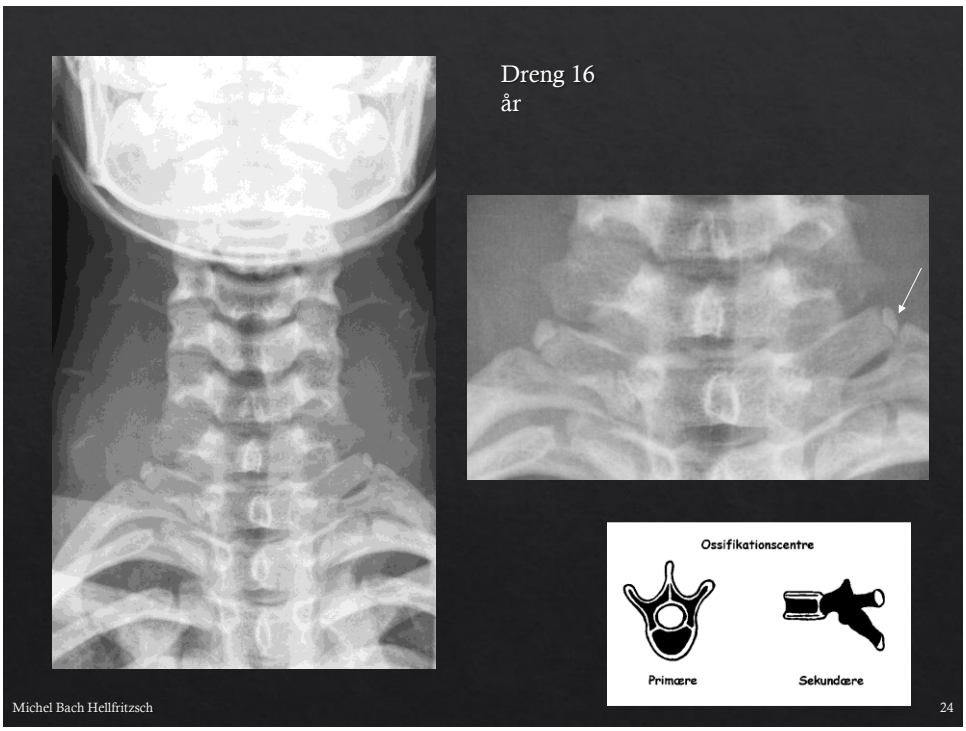
Dreng 16 år
Ossifikationscentre
Primære
Sekundære
Michel Bach Hellfritzsch
24

24

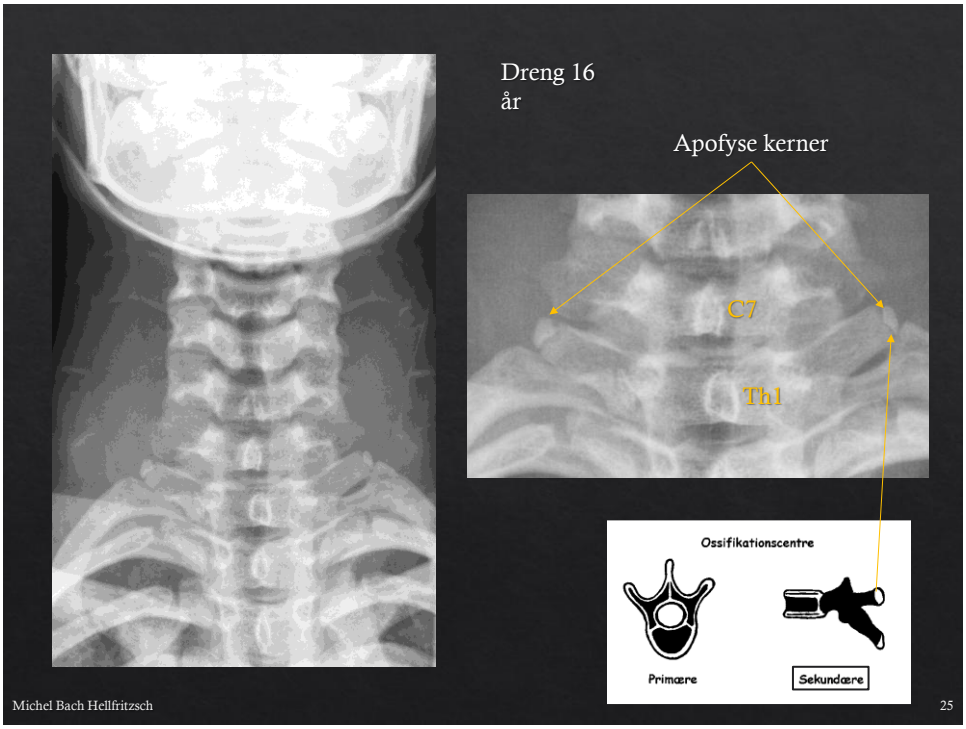
Dreng 16 år
Apofyse kerner
C7
Th1
Ossifikationscentre
Primære
Sekundære
Michel Bach Hellfritzsch
25

25

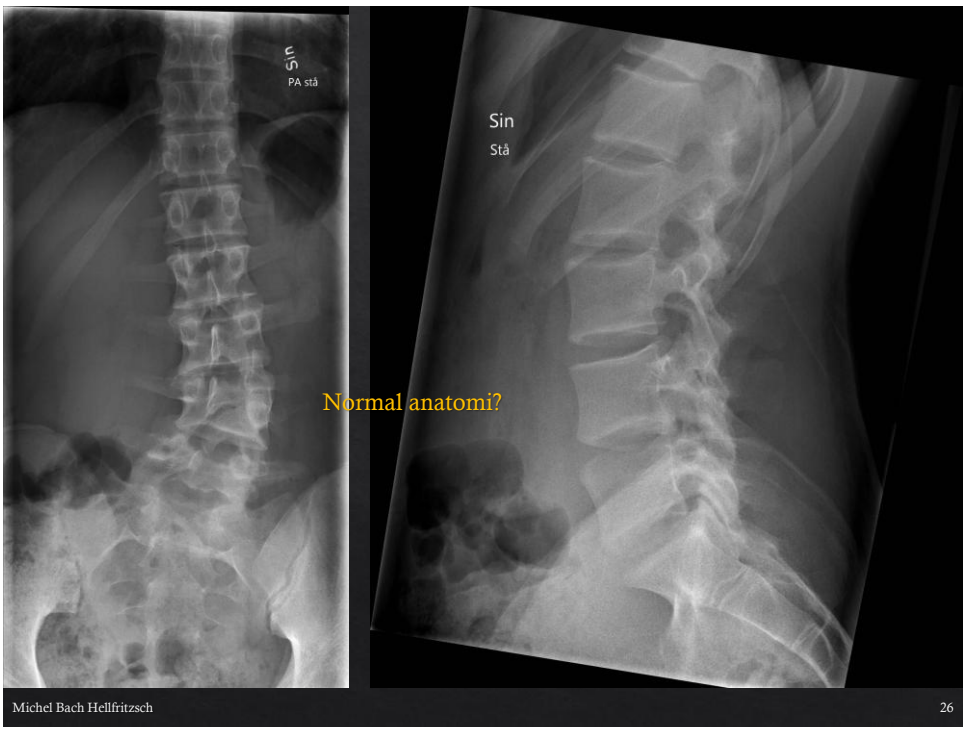
Sin
PA stå
Sin
Stå
Normal anatomi?
Michel Bach Hellfritzsch
26

26

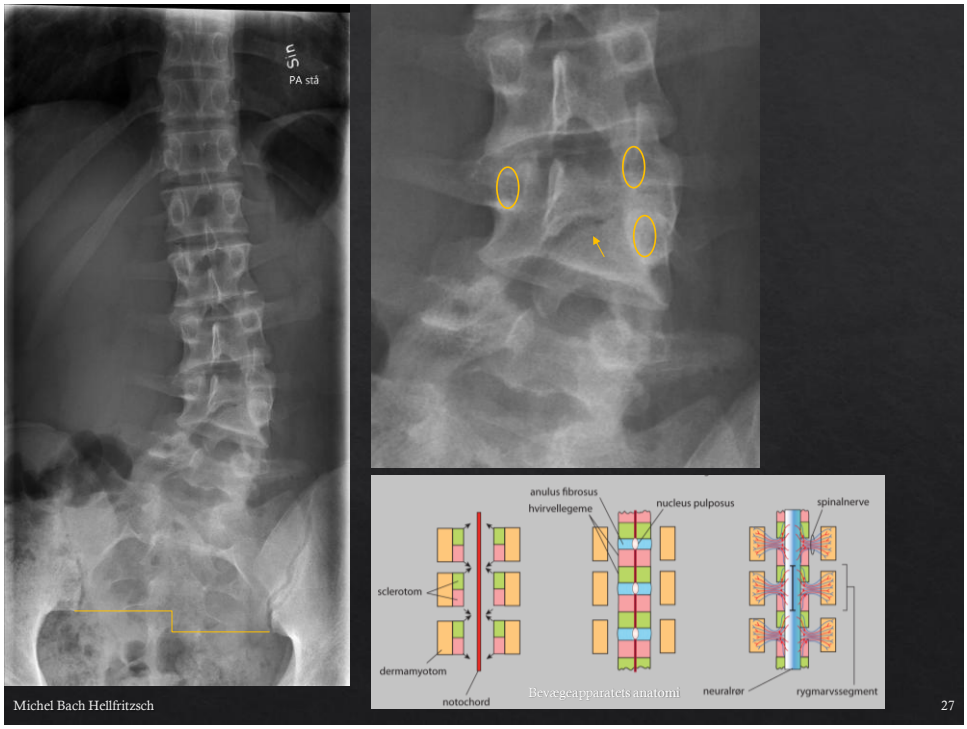

27

Columna cervicalis

28

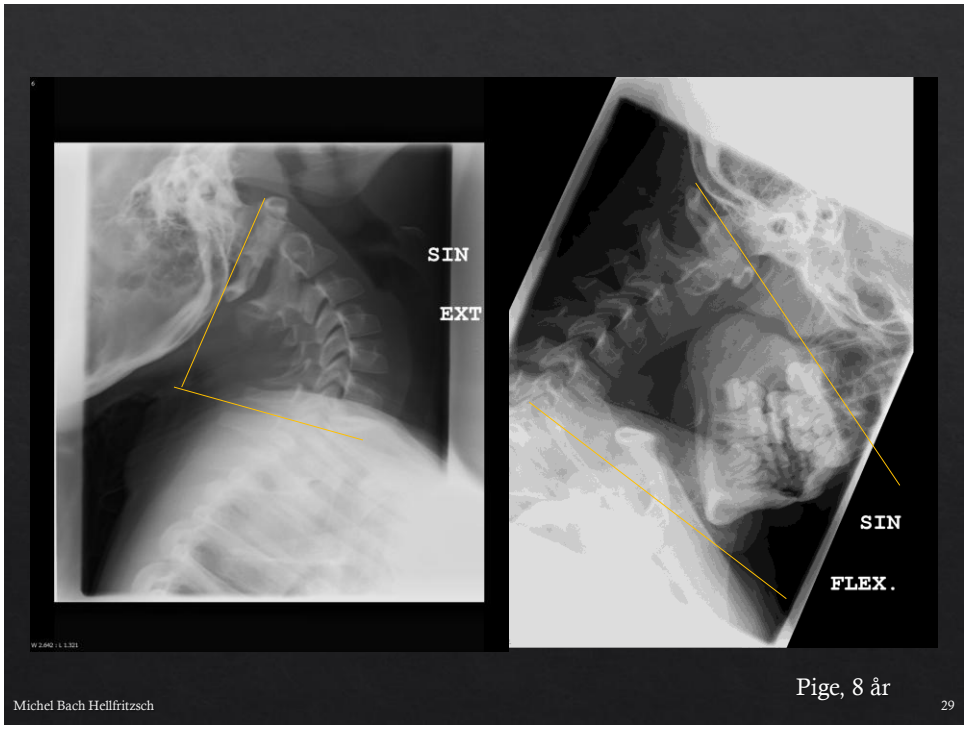
SIN
EXT
SIN
FLEX.
Pige, 8 år
Michel Bach Hellfritzsch
29

29

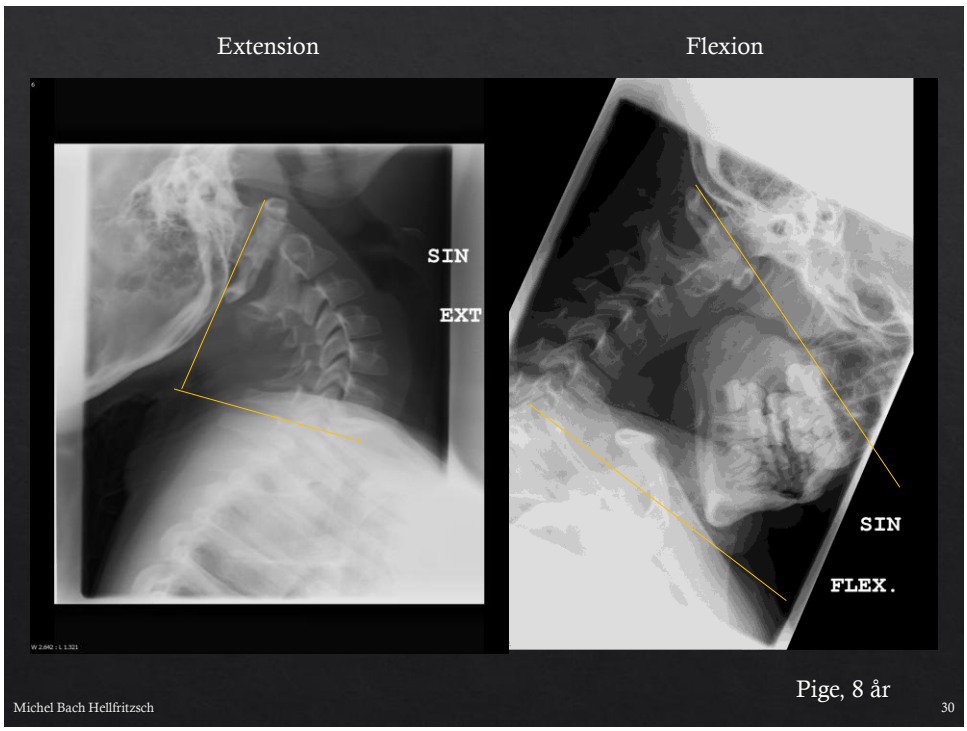
Extension
Flexion
SIN
EXT
SIN
FLEX.
Pige, 8 år
Michel Bach Hellfritzsch
30

30

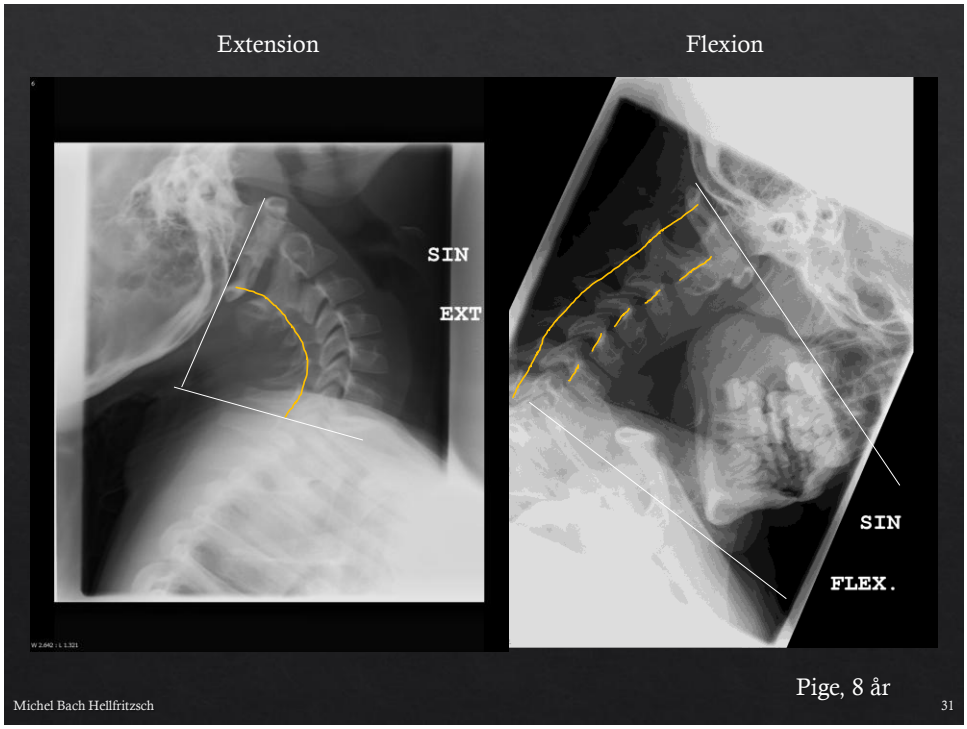
Extension
Flexion
SIN
EXT
SIN
FLEX.
Pige, 8 år
Michel Bach Hellfritzsch
31

31

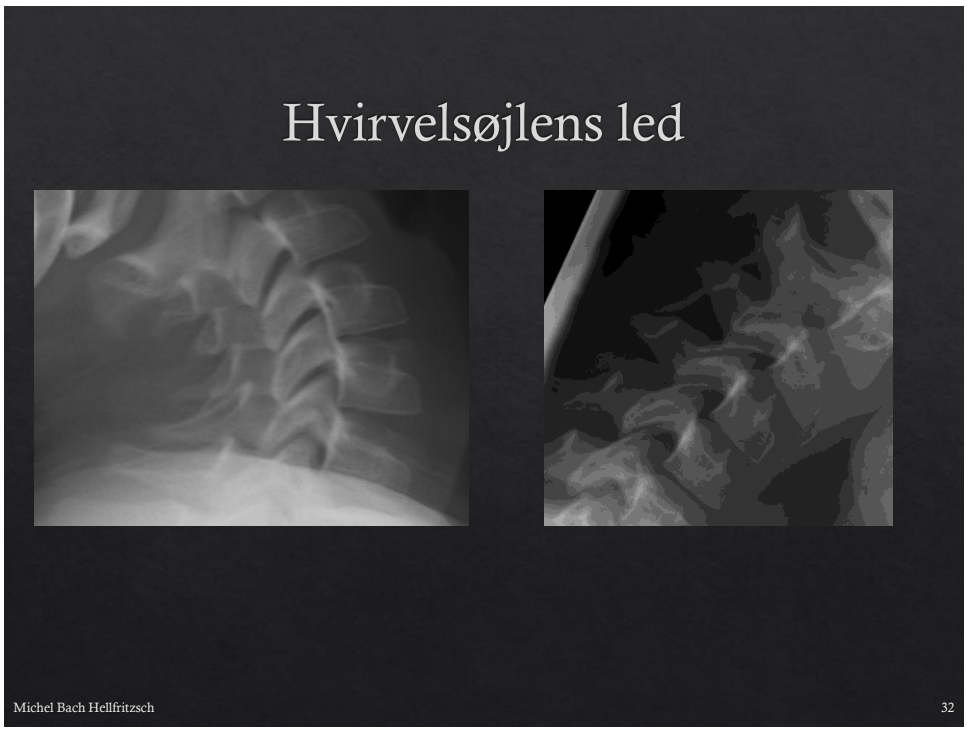
Hvirvelsøjlens led
Michel Bach Hellfritzsch
32

32

Hvirvelsøjlens led

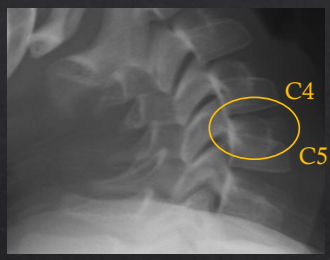

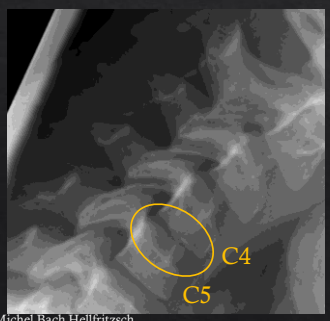

- Leddene mellem hvirvellegemerne
  - Discus intervertebralis
- Leddene mellem hvirvelbuerne
  - Articulationes zygapophysiales / Facetled (ægte led)
  - Syndesmoser

33

Hvirvelsøjlens led

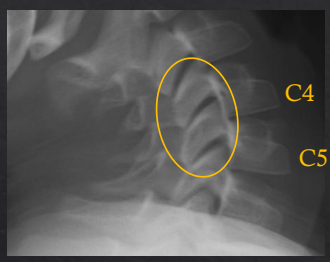

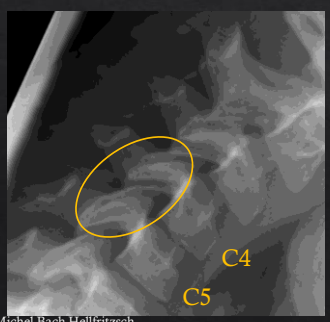

- Leddene mellem hvirvellegemerne
  - Discus intervertebralis
- Leddene mellem hvirvelbuerne
  - Articulationes zygapophysiales / Facetled (ægte led)
  - Syndesmoser (ses ej på Rtg.)

34

Atlas og axis

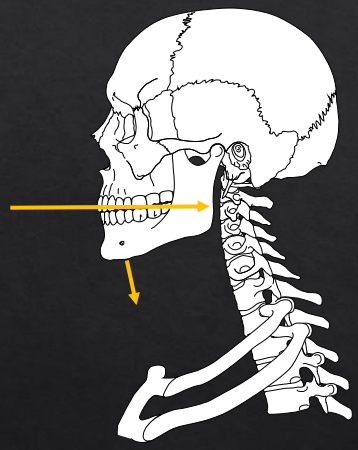





35

Atlas og axis

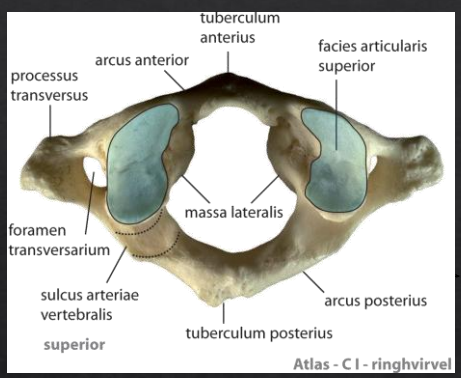





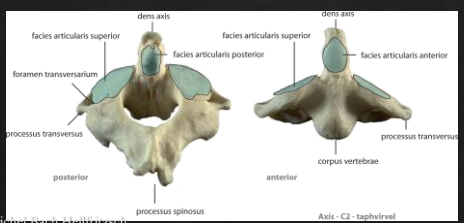

36

Atlas og axis

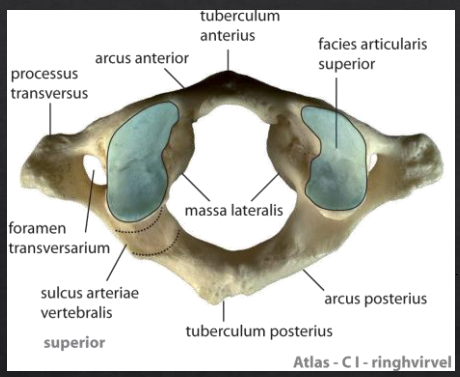



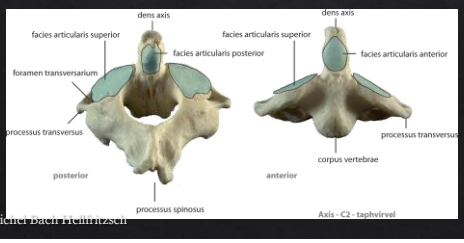



37

Atlas og axis

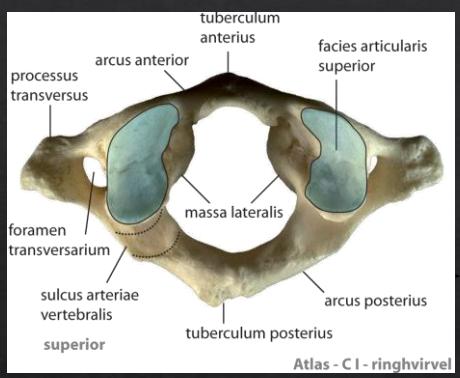

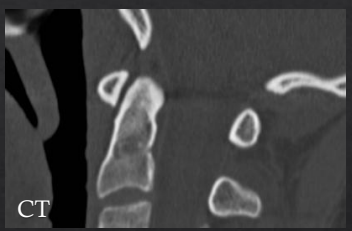

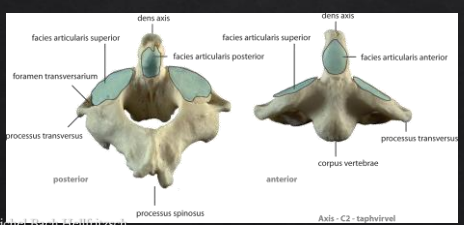



38

Atlas og axis



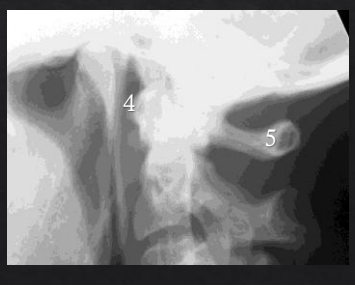

Michel Bach Hellfritzsch 39

39

Atlas og axis





1) Dens axis
2) Massa lateralis atlantis
3) Processus transversus CI
4) Arcus anterior atlantis
5) Arcus posterior atlantis

Michel Bach Hellfritzsch 40

40

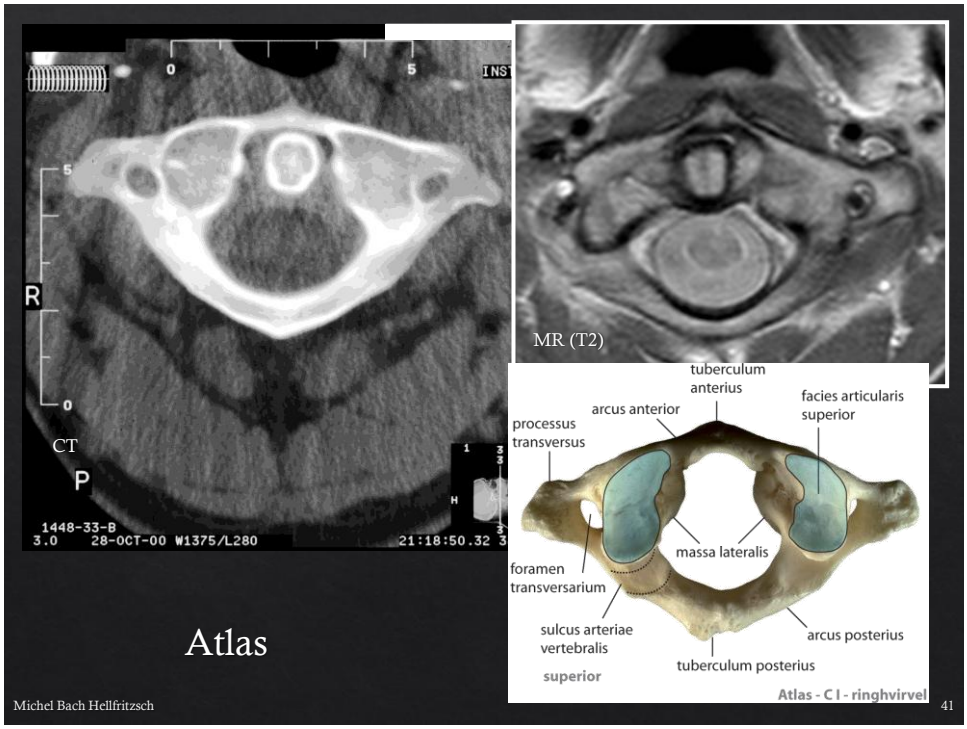
CT
MR (T2)
tuberculum anterius
arcus anterior
facies articularis superior
processus transversus
massa lateralis
foramen transversarium
sulcus arteriae vertebralis
arcus posterius
tuberculum posterius
superior
Atlas - C I - ringhvirvel
Atlas
Michel Bach Hellfritzsch
41

41


CT
MR (T2)
Michel Bach Hellfritzsch
42

42



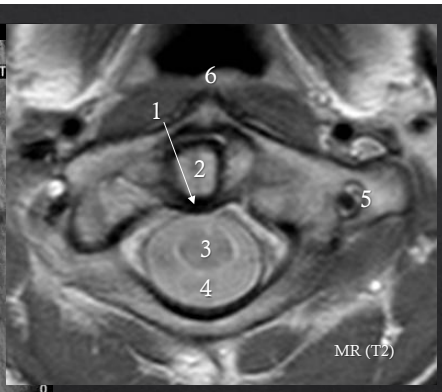

1) Ligamentum transversum atlantis
2) Dens axis
3) Medulla spinalis
4) Liquor cerebrospinalis
5) Foramen transversarium (med a. vertebralis – sort på MR billedet)
6) Tuberculum anterius
7) Tuberculum posterius

Michel Bach Hellfritzsch 43

43



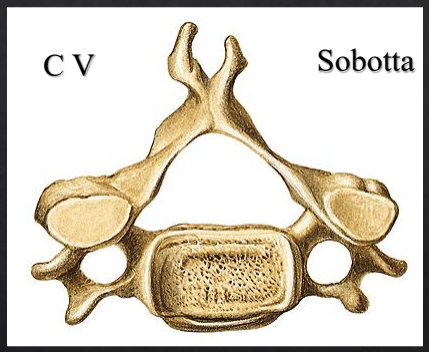

Michel Bach Hellfritzsch 44

44



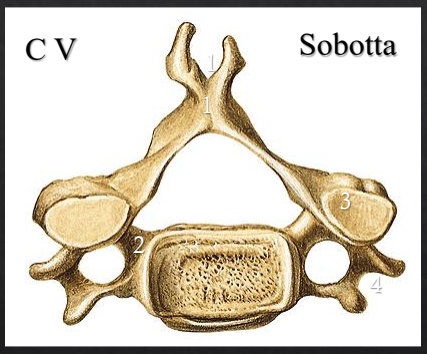

Michel Bach Hellfritzsch 45

45



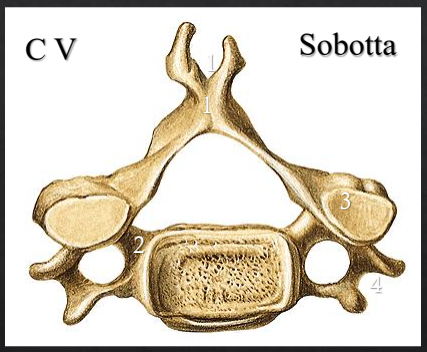

1) Processus spinosus
2) Pediculus
3) Processus articularis (inf. et sup.)
4) Processus transversus

Michel Bach Hellfritzsch 46

46


Sobotta
Michel Bach Hellfritzsch
47

47


Sobotta
3
2
1
1
2
3
4
Michel Bach Hellfritzsch
48

48

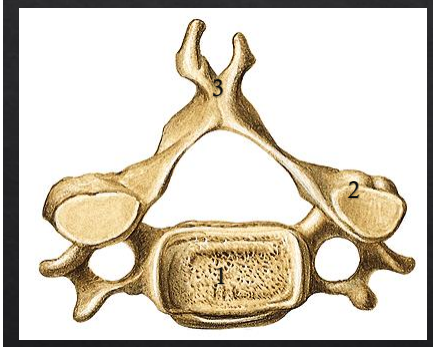



1) Corpus vertebrae C V
2) Articulatio zygapophysialis (Facetled) CIV/CV
3) Processus spinosus vertebrae C IV
4) Discus intervertebralis C VI/VII

Michel Bach Hellfritzsch 49

49



CT 3D

www.radiology.dk

Michel Bach Hellfritzsch 50

50

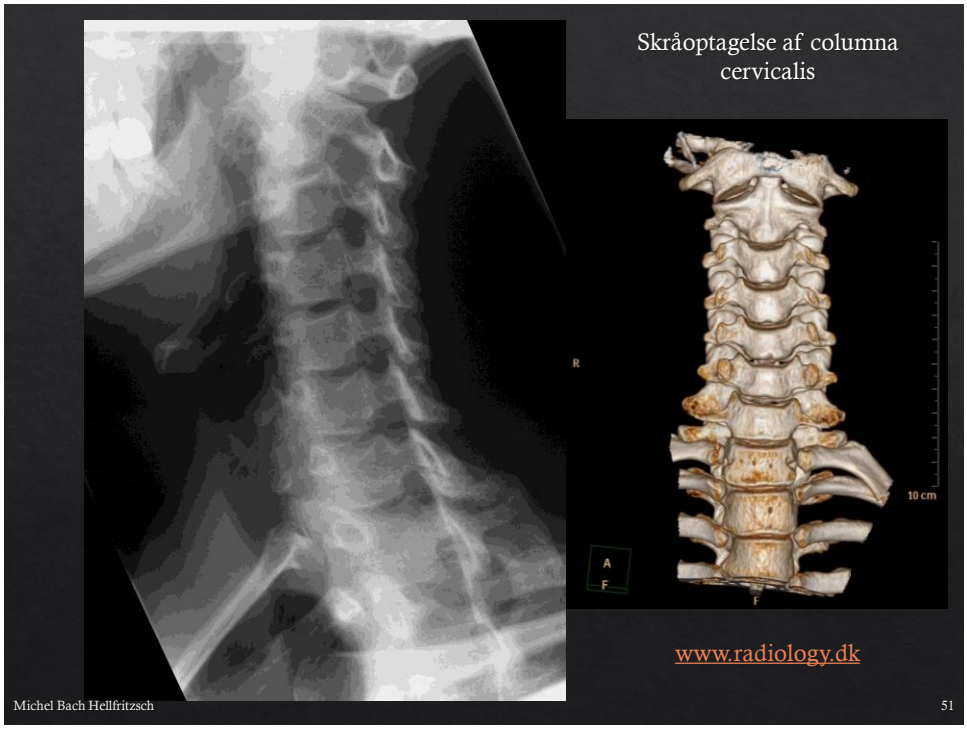
Skråoptagelse af columna cervicalis
R
10 cm
A
F
www.radiology.dk
Michel Bach Hellfritzsch
51

51

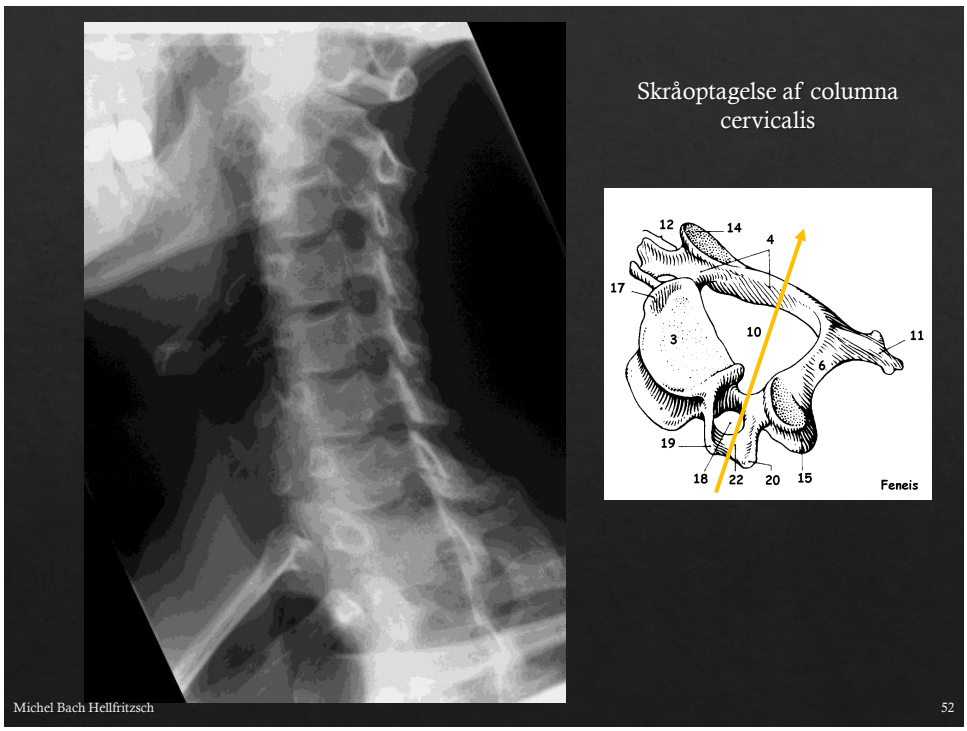
Skråoptagelse af columna cervicalis
12
14
4
17
3
10
11
6
19
18
22
20
15
Feneis
Michel Bach Hellfritzsch
52

52

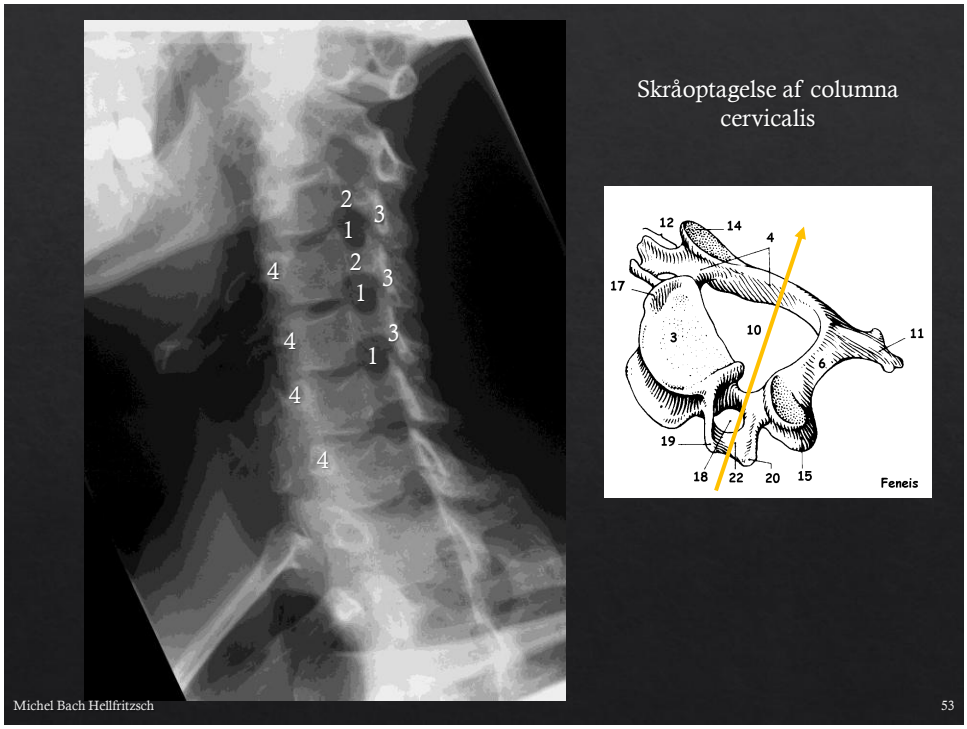
Skråoptagelse af columna cervicalis
2
3
1
2
4
3
1
4
3
1
4
4
12
14
4
17
3
10
11
6
19
18
22
20
15
Feneis
Michel Bach Hellfritzsch
53

53

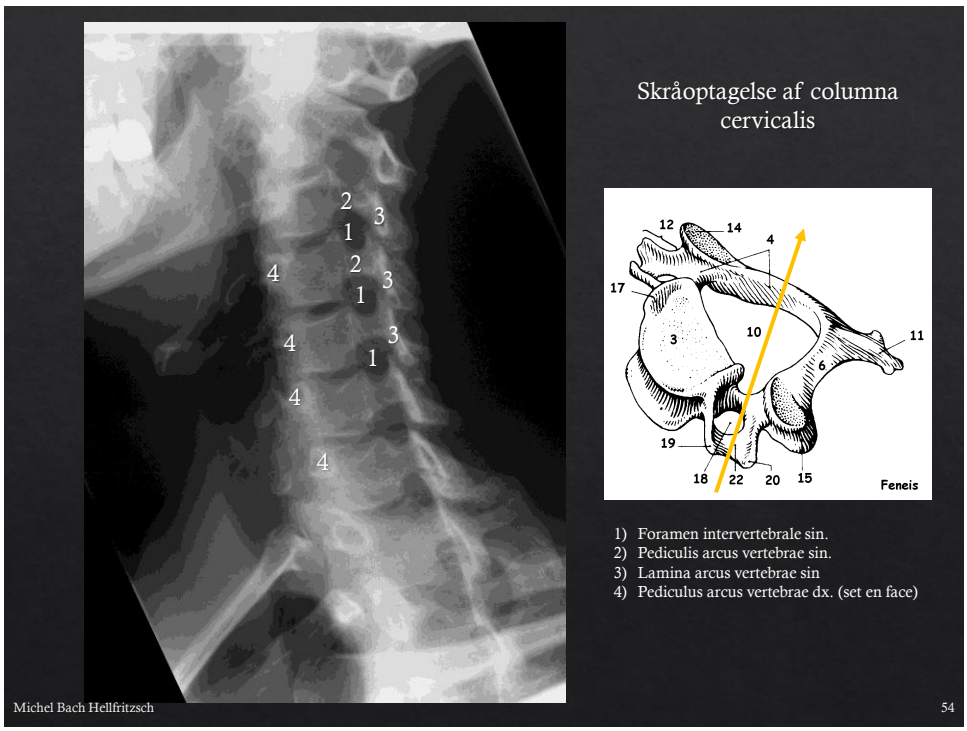
Skråoptagelse af columna cervicalis
2
3
1
2
4
3
1
4
3
1
4
4
12
14
4
17
3
10
11
6
19
18
22
20
15
Feneis
1) Foramen intervertebrale sin.
2) Pediculis arcus vertebrae sin.
3) Lamina arcus vertebrae sin
4) Pediculus arcus vertebrae dx. (set en face)
Michel Bach Hellfritzsch
54

54

Costa cervicalis

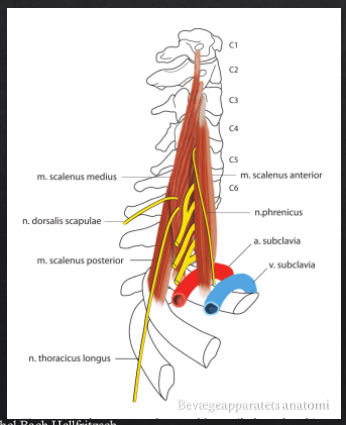

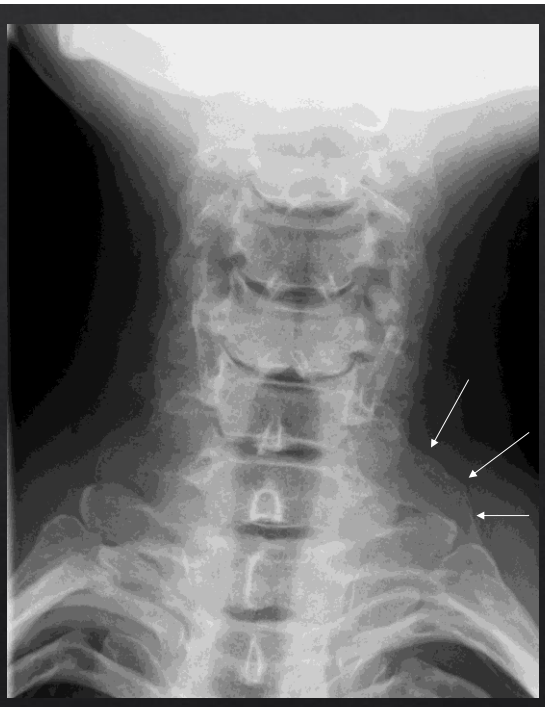

Michel Bach Hellfritzsch 55

55

Costa cervicalis
Et langt costa cervicalis kan give tryk på nabostrukturerne, eksempelvis a. subclavia.

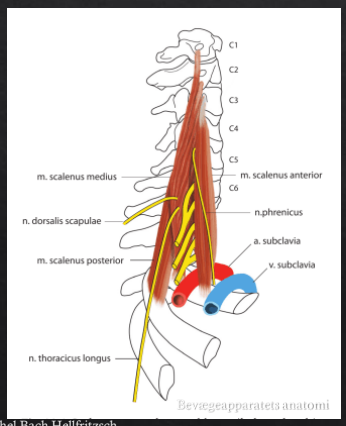

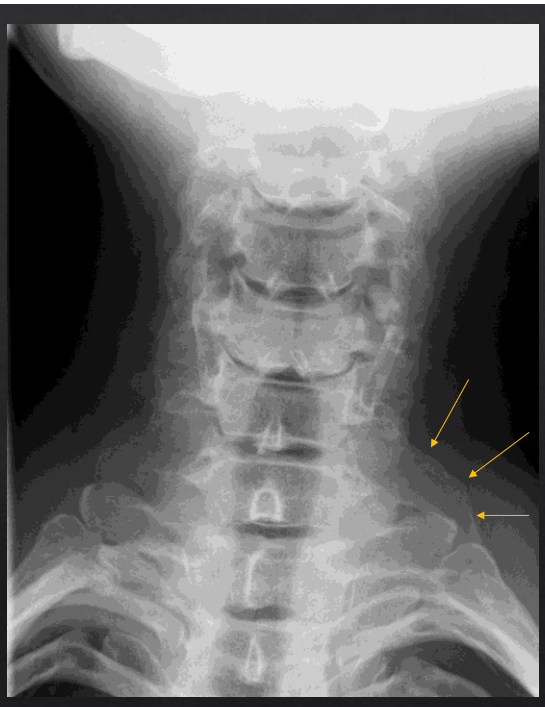

Michel Bach Hellfritzsch 56

56

73-årig mand med slidforandringer i cervikal columna

Michel Bach Hellfritzsch 57

57

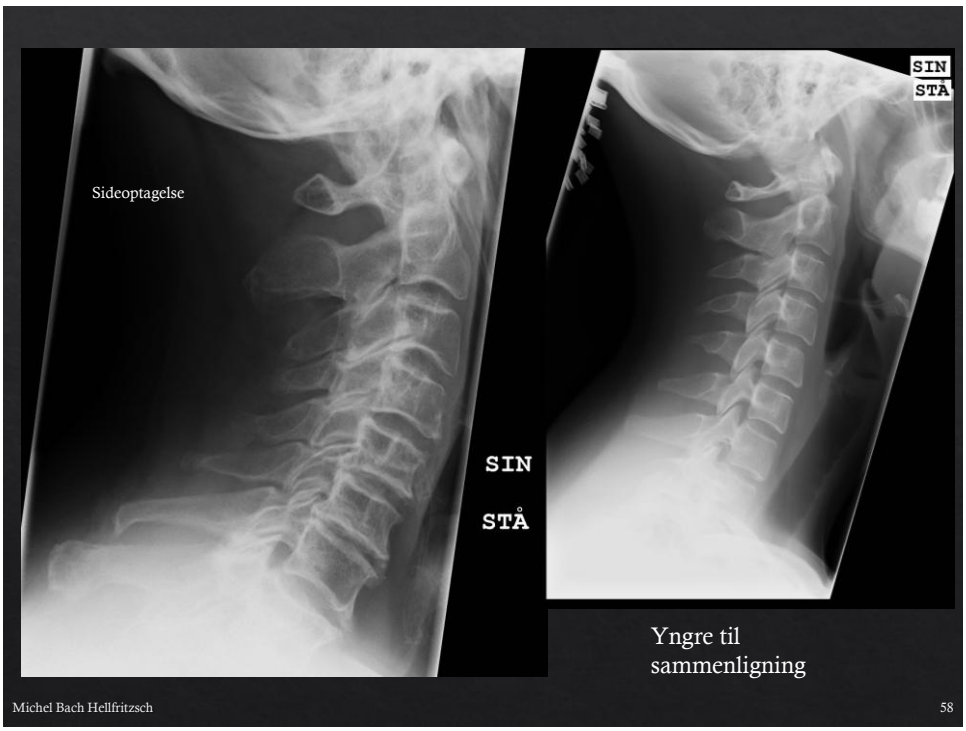

Michel Bach Hellfritzsch 58

58

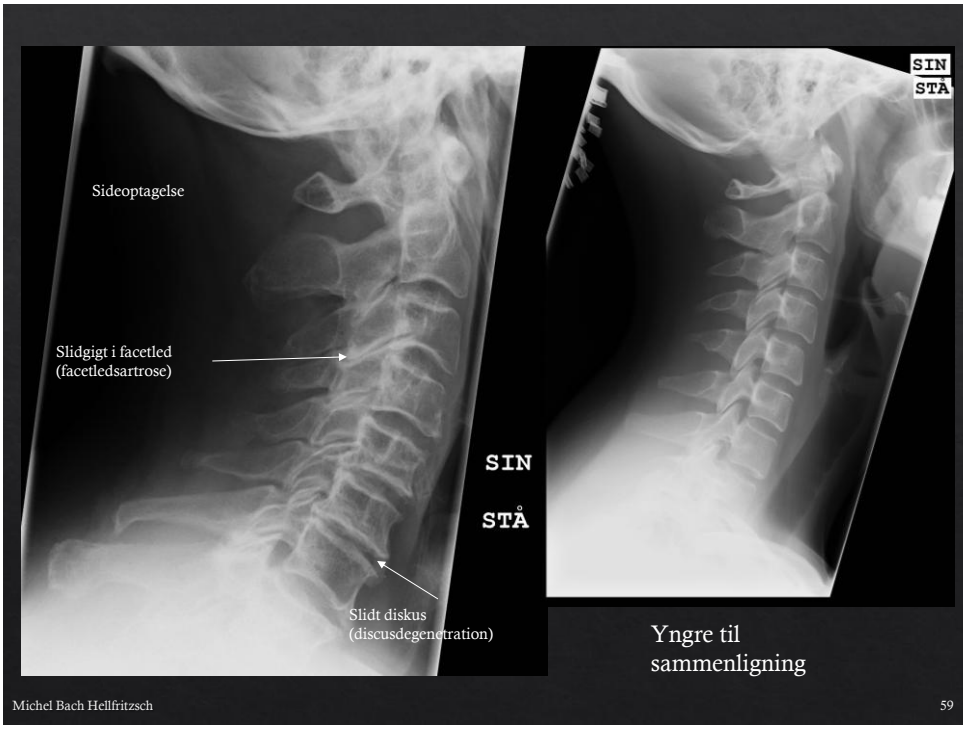
Sideoptagelse
Slidgigt i facetled
(facetledsartrose)
SIN
STÅ
Slidt diskus
(discusdegeneration)
SIN
STÅ
Yngre til
sammenligning
Michel Bach Hellfritzsch
59

59

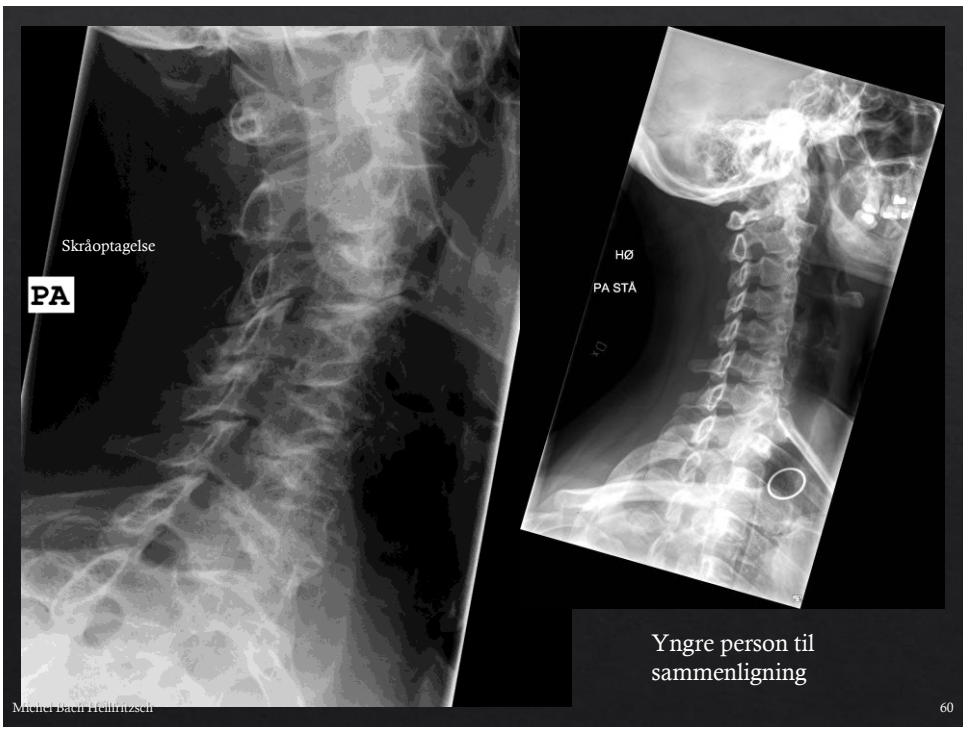
Skråoptagelse
PA
HØ
PA STÅ
Yngre person til
sammenligning
Michel Bach Hellfritzsch
60

60

Spinalkanalen

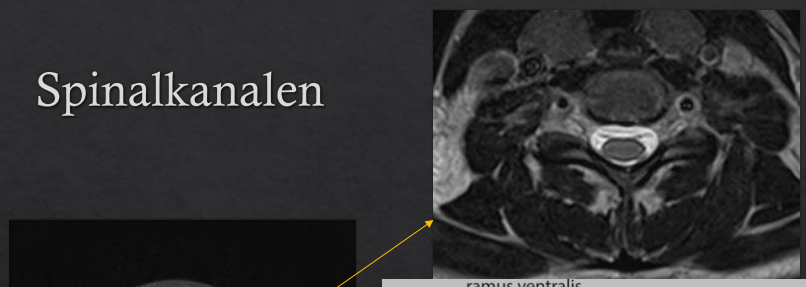

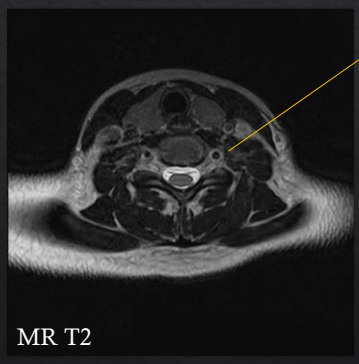

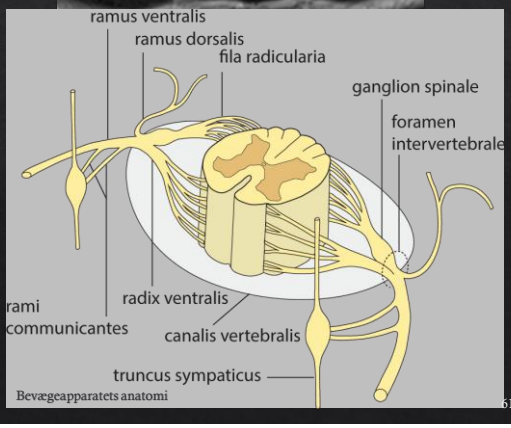

61

Spinalkanalen

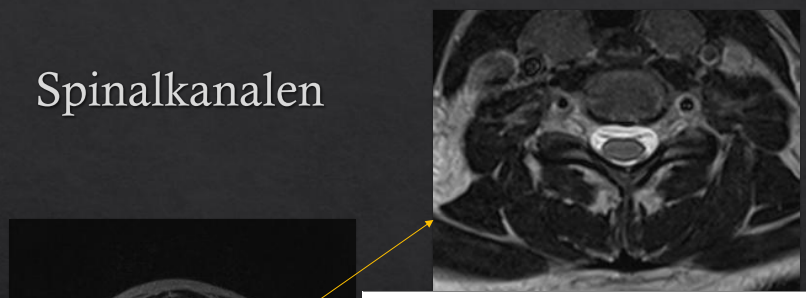

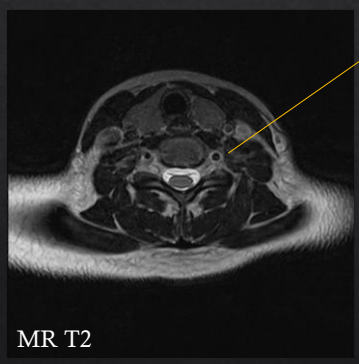

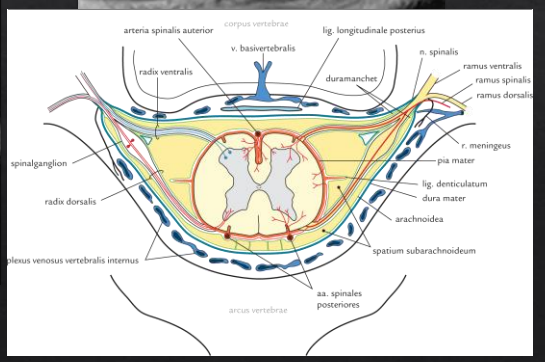

62

MR af columna cervicalis

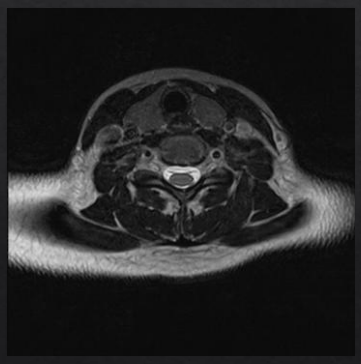

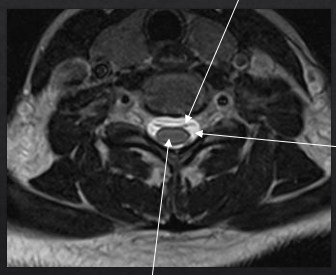

Michel Bach Hellfritzsch 63

63

Cervical discus prolaps

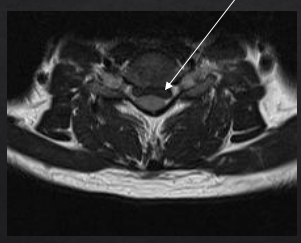

Michel Bach Hellfritzsch 64

64

Cervical discus prolaps

De følgende MR snit er lavet som skrå frontale snit, se billedet til højre.

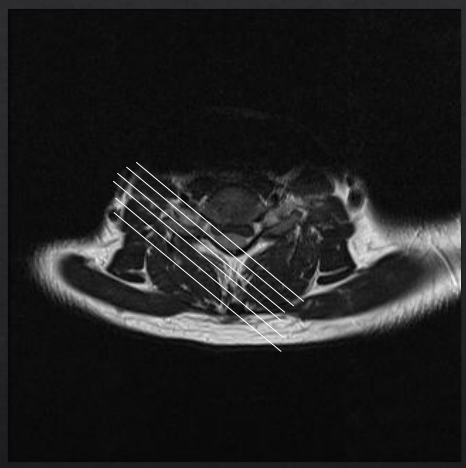

65

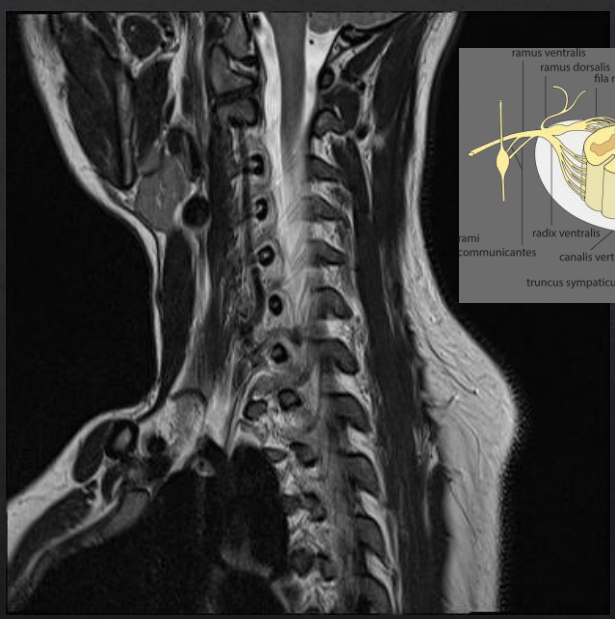

66


1
2
3
4
5
Michel Bach Hellfritzsch
67

67

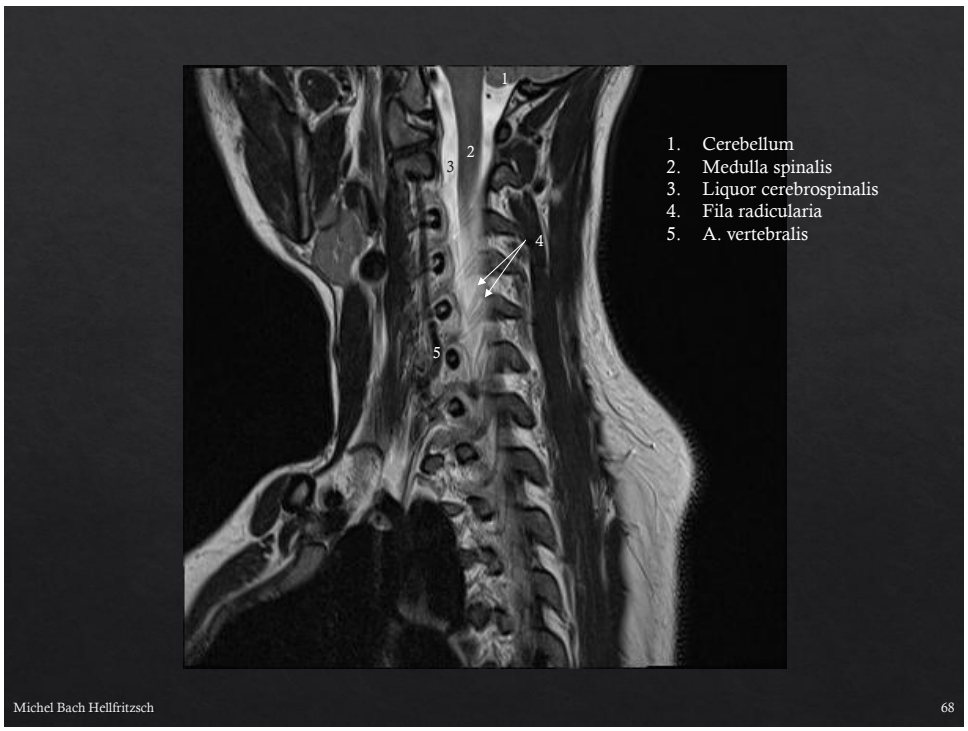
1
2
3
4
5
1. Cerebellum
2. Medulla spinalis
3. Liquor cerebrospinalis
4. Fila radicularia
5. A. vertebralis
Michel Bach Hellfritzsch
68

68

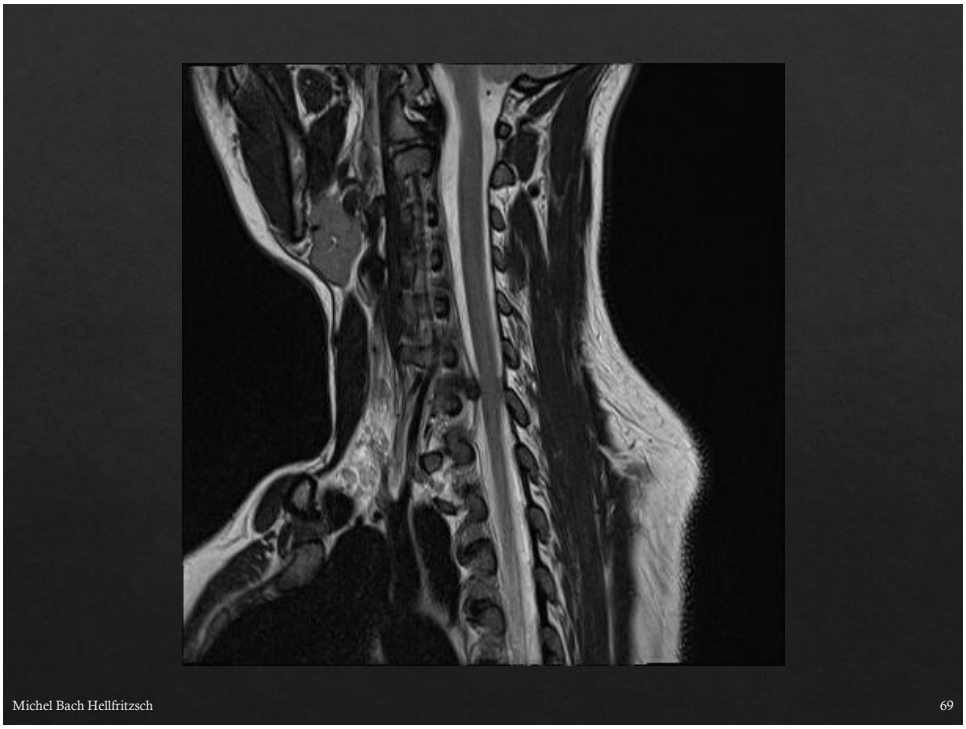

69

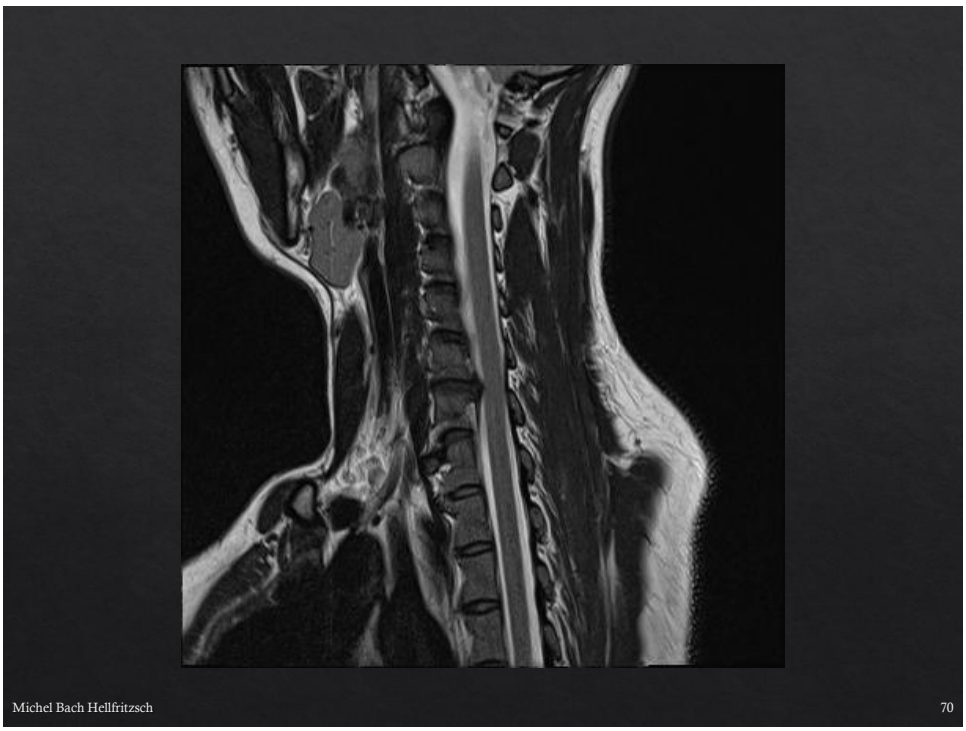

70



71



72

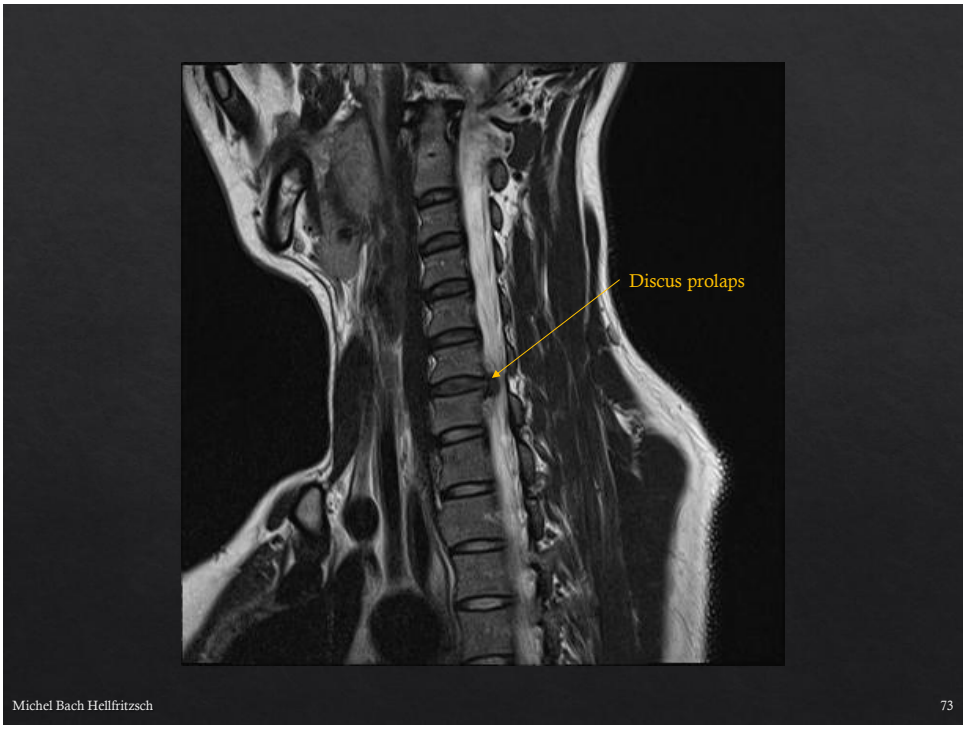
Discus prolaps
Michel Bach Hellfritzsch
73

73


Michel Bach Hellfritzsch
74

74

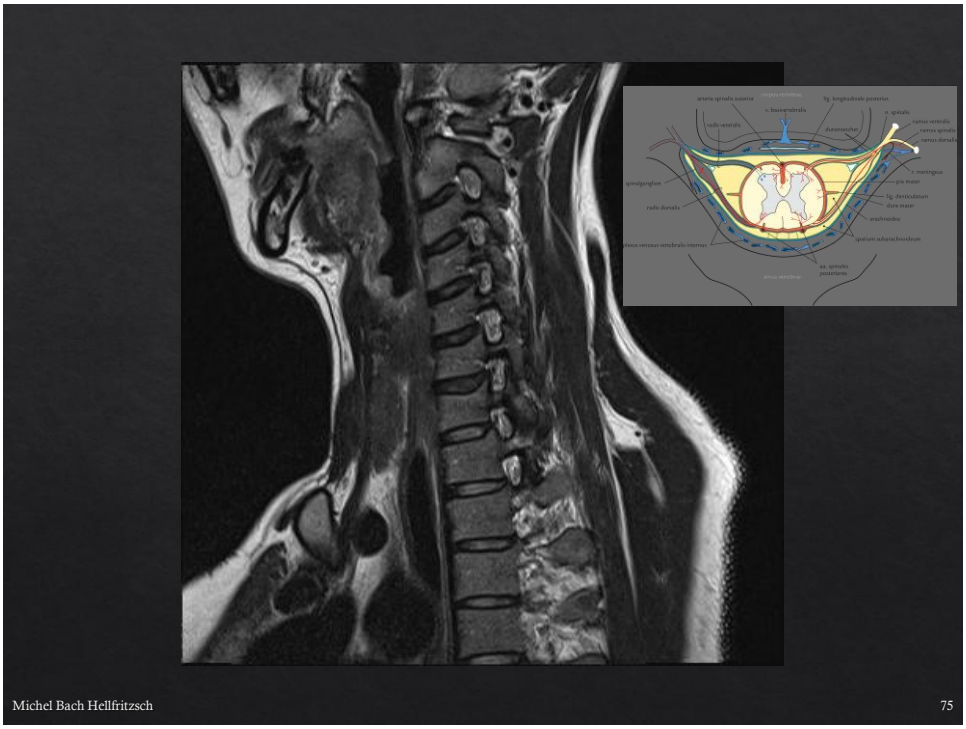

75



76



77

Truncus

Del 2:

Columna lumbalis

Knoglemarv

78

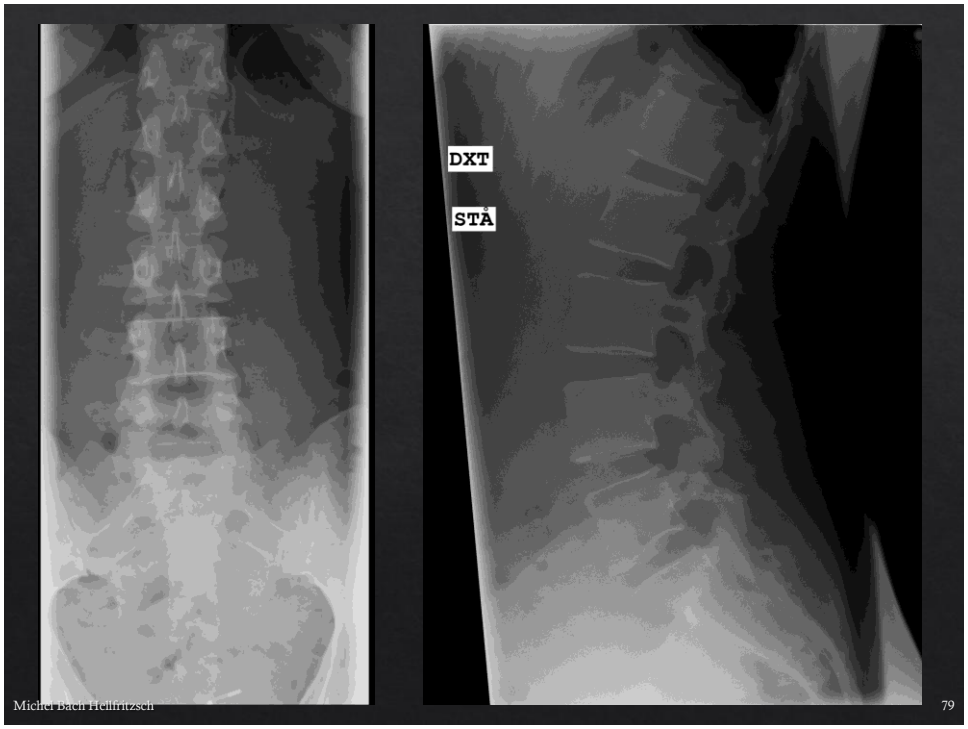
DXT
STÅ
Michel Bach Hellfritzsch
79

79

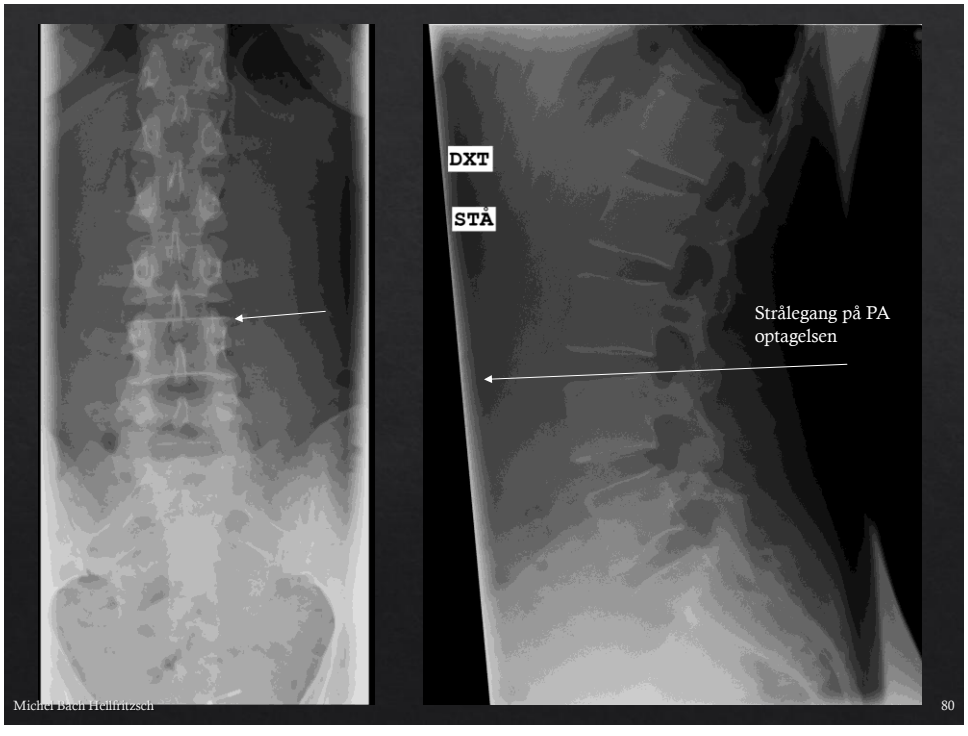
DXT
STÅ
Strålegang på PA optagelsen
Michel Bach Hellfritzsch
80

80


DXT
STÅ
Michel Bach Hellfritzsch
81

81

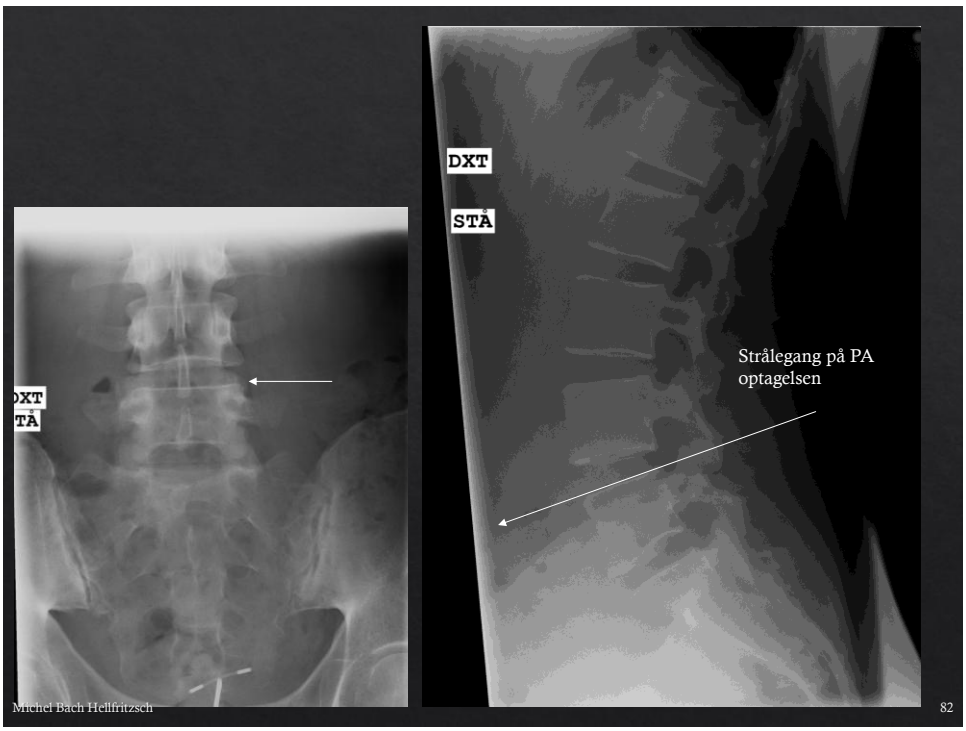
DXT
STÅ
Strålegang på PA optagelsen
Michel Bach Hellfritzsch
82

82

Lumbosakral overgangshvirvel

83

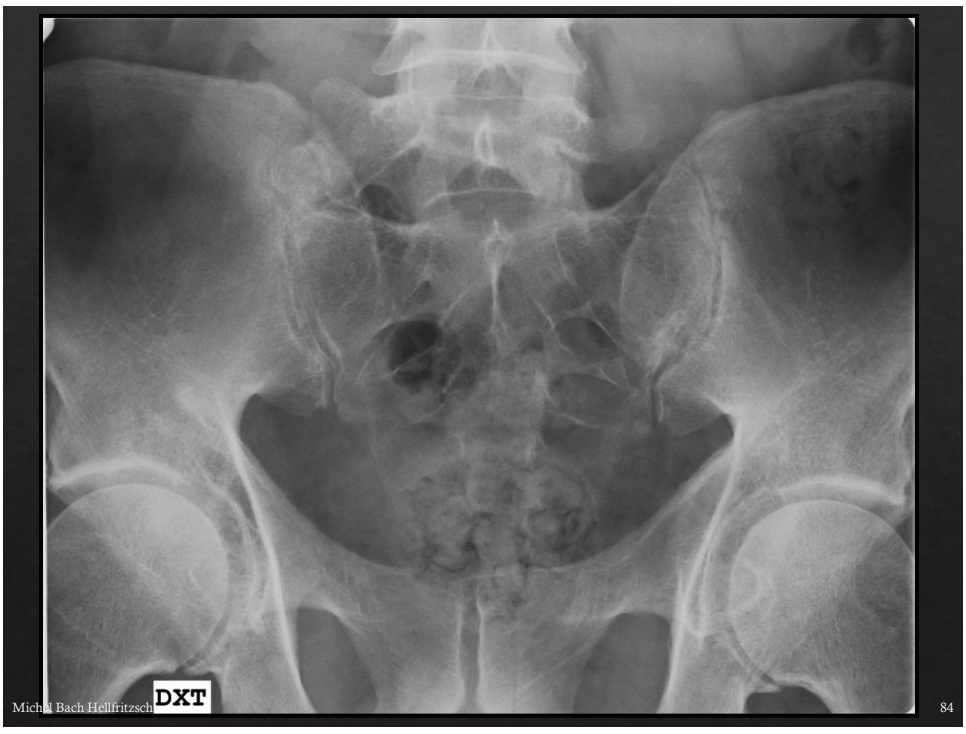

84

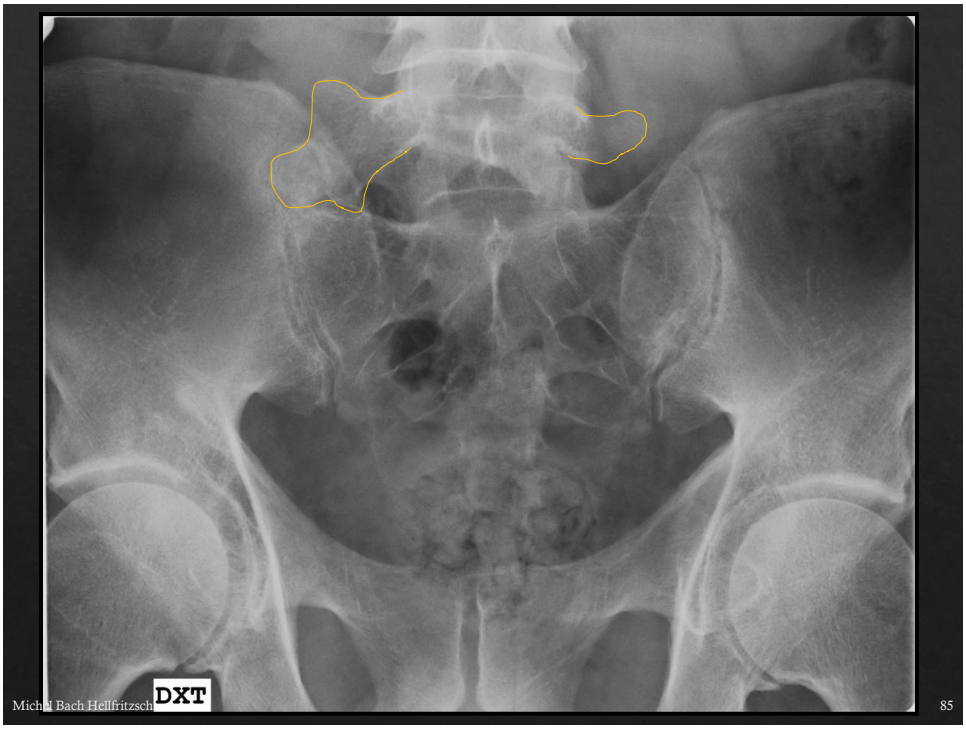

85

Columnas blodforsyning

86

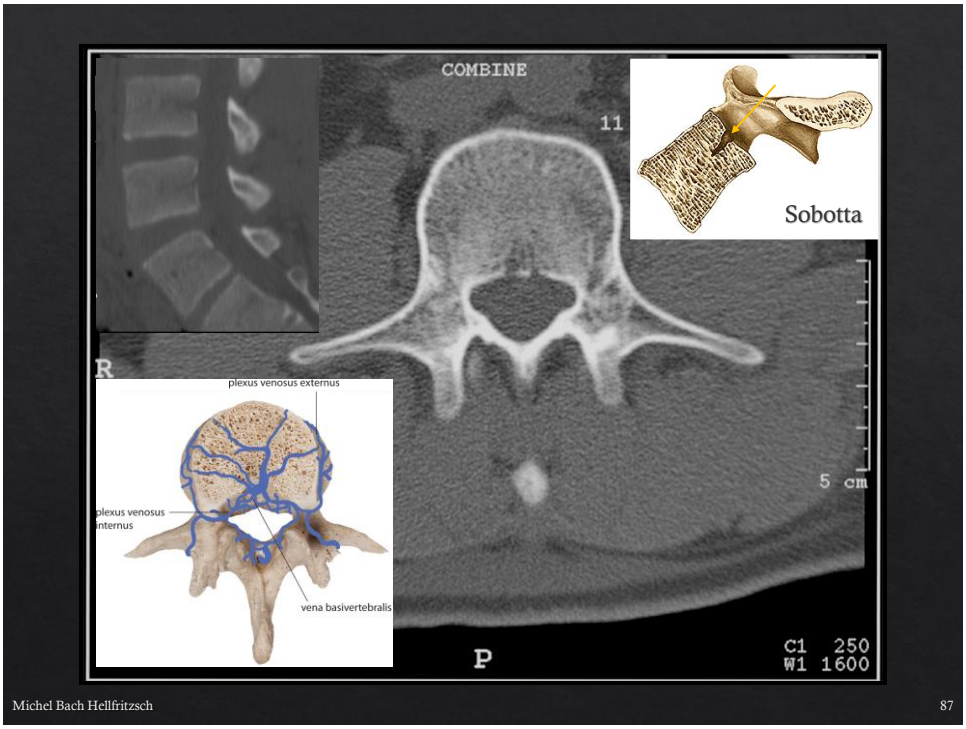

87

Knoglemarven

88


Rtg
CT
MR: T1
Michel Bach Hellfritzsch
89

89

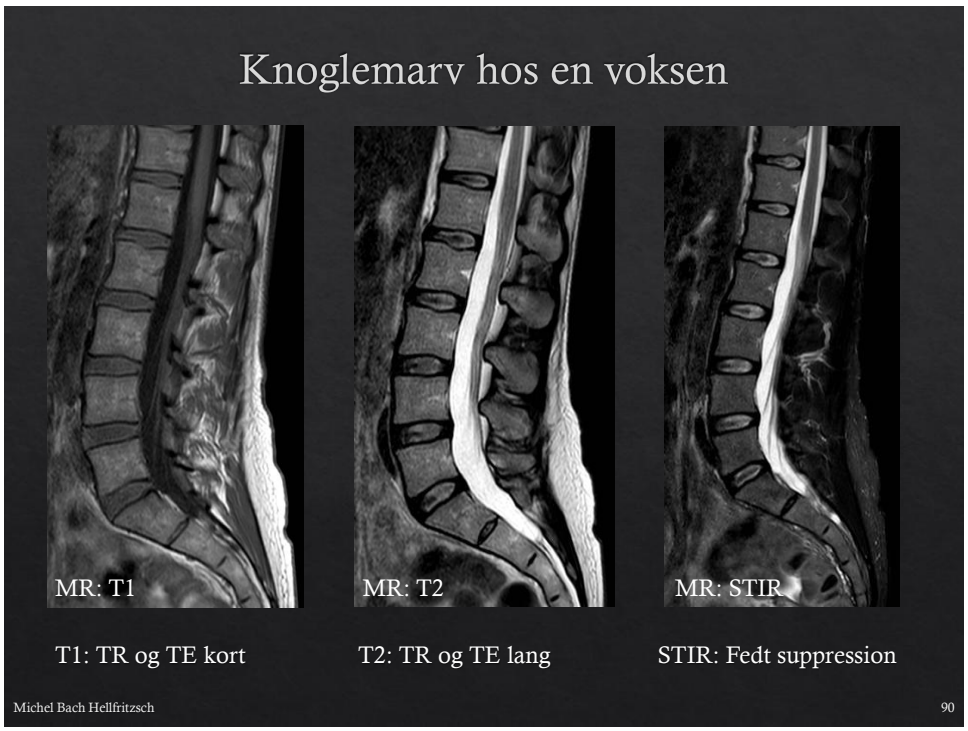
Knoglemarv hos en voksen
MR: T1
MR: T2
MR: STIR
T1: TR og TE kort
T2: TR og TE lang
STIR: Fedt suppression
Michel Bach Hellfritzsch
90

90

Knoglemarv hos en voksen



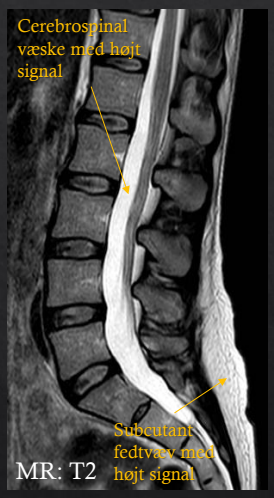



T1: TR og TE kort

T2: TR og TE lang

STIR: Fedt suppression

91



Yngre barn

Forandringer?

92

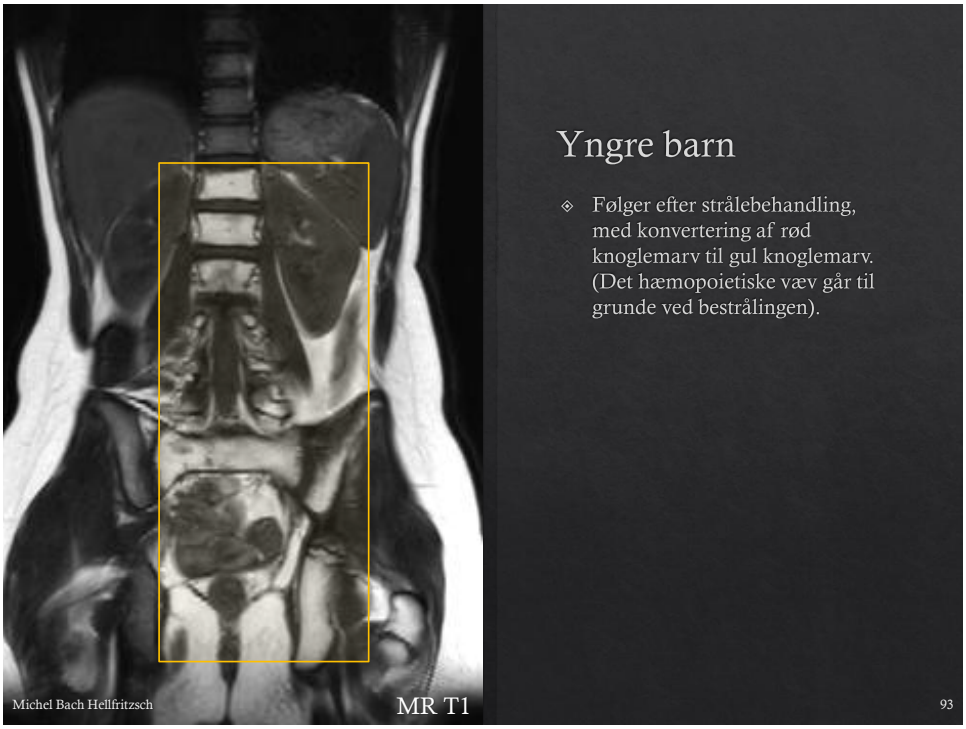
Yngre barn
Følger efter strålebehandling, med konvertering af rød knoglemarv til gul knoglemarv. (Det hæmopoietiske væv går til grunde ved bestrålingen).
Michel Bach Hellfritzsch
MR T1
93

93


Patologisk knoglemarv
T1
STIR
Michel Bach Hellfritzsch
94

94



Marvinfiltration

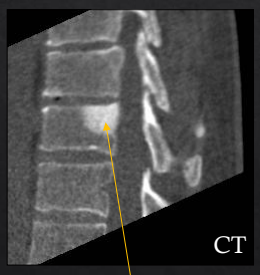

Osteosklerotisk metastase

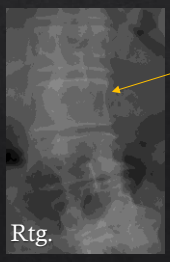

Osteolytisk metastase (pediklet på venstre side er forsvundet)

Michel Bach Hellfritzsch 95

95



Marvinfiltration

Metastaser (fjern spredning af kræft):
Marvinfiltration (Svulstcellerne ligger fokalt i knoglemarven)
Osteolyse (Påvirkning af knoglevævet der fokalt forsvinder)
Osteosklerose (Påvirkning af knoglevævet, der fokalt øges i tæthed)

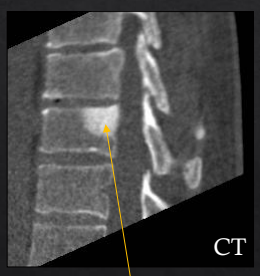

Osteosklerotisk metastase

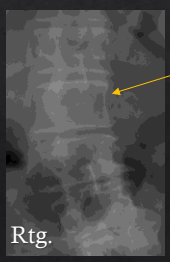

Osteolytisk metastase (pediklet på venstre side er forsvundet)

Michel Bach Hellfritzsch 96

96

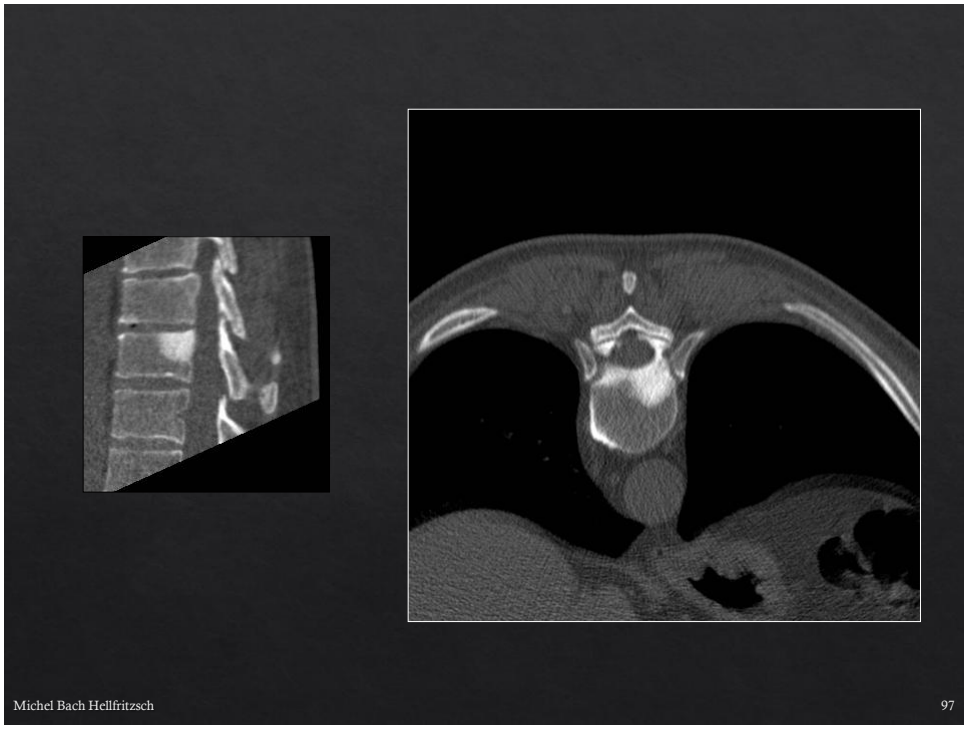
Michel Bach Hellfritzsch
97

97

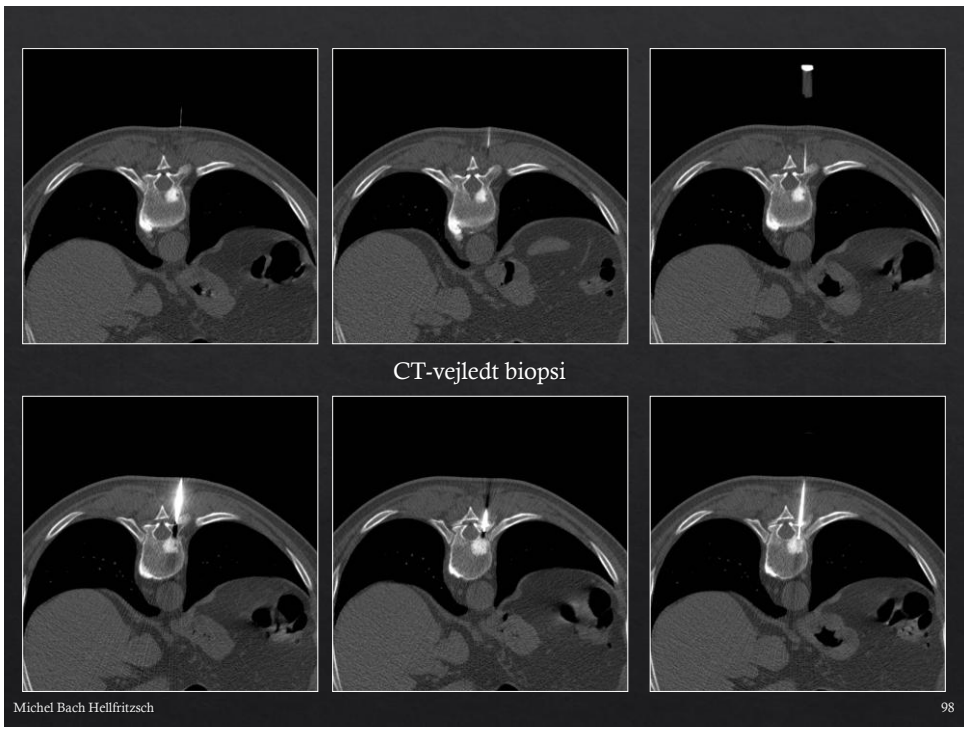
CT-vejledt biopsi
Michel Bach Hellfritzsch
98

98

Bløddelene

Medulla, cauda equina, discus intervertebralis, ligamenter

99

Discus intervertebralis

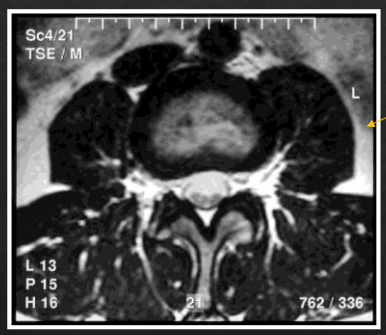

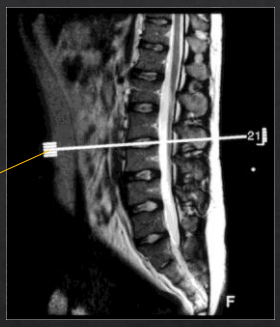



Snit lige gennem lumbal discus
(MR T2)

Bevægeapparatets anatomi

100

Medulla spinalis
Conus medullaris
Cauda equina
Liquor cerebrospinalis
Ligg. supraspinalia
Ligg. interspinalia
Ligg. flava
Lig. longitudinale ant.
Lig. longitudinale post.
Discus intervertebralis

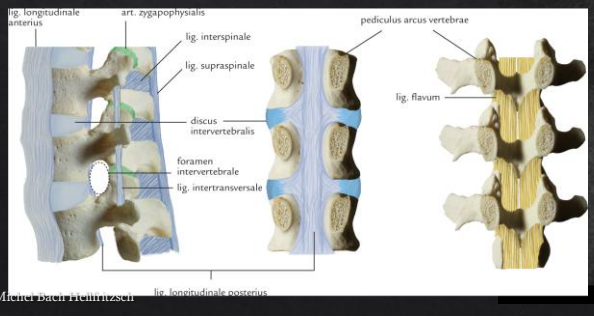

MR T2



Michel Bach Hellfritzsch

101

101

MR T2

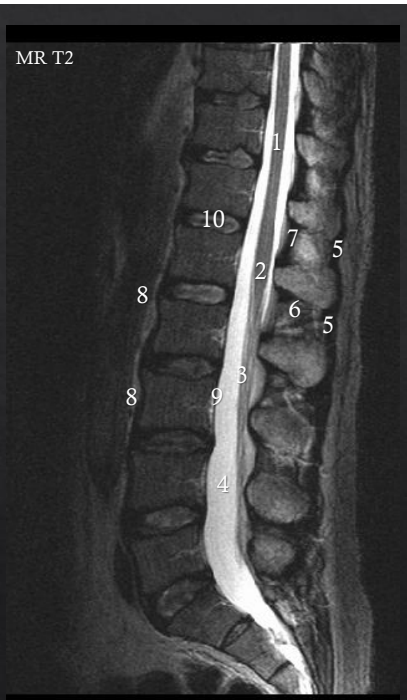

Michel Bach Hellfritzsch

102

102

1) Medulla spinalis
2) Conus medullaris
3) Cauda equina
4) Liquor cerebrospinalis
5) Ligg. supraspinalia
6) Ligg. interspinalia
7) Ligg. flava
8) Lig. longitudinale ant.
9) Lig. longitudinale post.
10) Discus intervertebralis



Michel Bach Hellfritzsch 103

103

Lumbalpunktur

Michel Bach Hellfritzsch 104

104

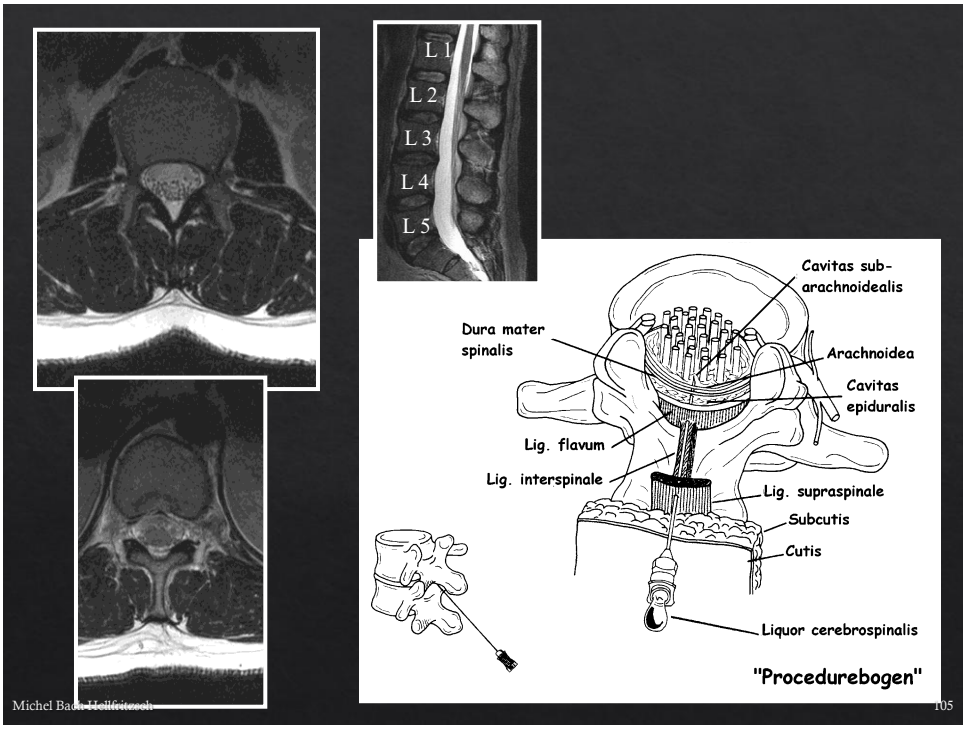
L 1
L 2
L 3
L 4
L 5
Cavitas sub-arachnoidealis
Dura mater spinalis
Arachnoidea
Cavitas epiduralis
Lig. flavum
Lig. interspinale
Lig. supraspinale
Subcutis
Cutis
Liquor cerebrospinalis
"Procedurebogen"
Michel Bach Hellfritzsch
105

105


SAG
Precision+
A Pure+
MI (1.0)
i24LX8
d19
34 fps
Qscan
G:88
DR:70
A:2
P:5
4mm
UL skanning af medulla spinalis og cauda equina hos nyfødt
Michel Bach Hellfritzsch
106

106

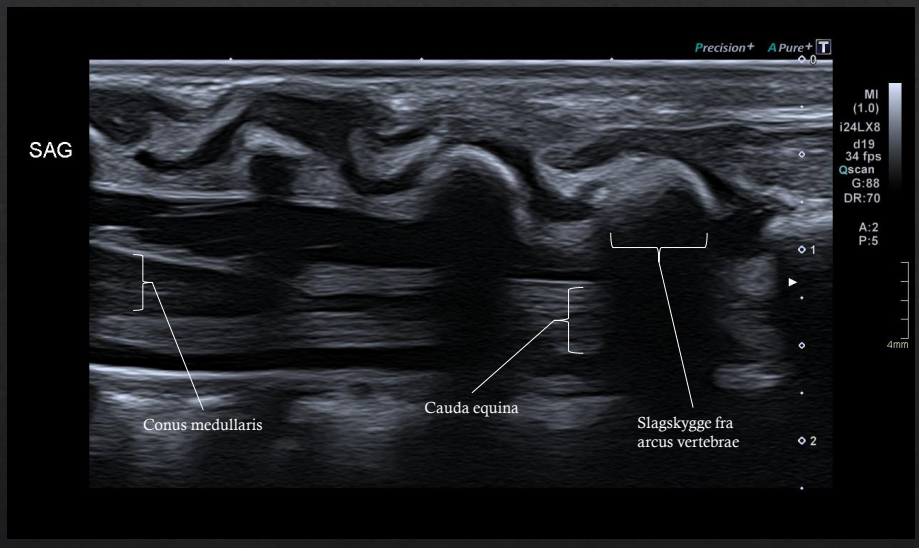

UL skanning af medulla spinalis og cauda equina hos nyfødt

107

Truncus

Del 3:

Bugvæggen og diafragma

Hernier

108

Bughulens afgrænsninger.

109

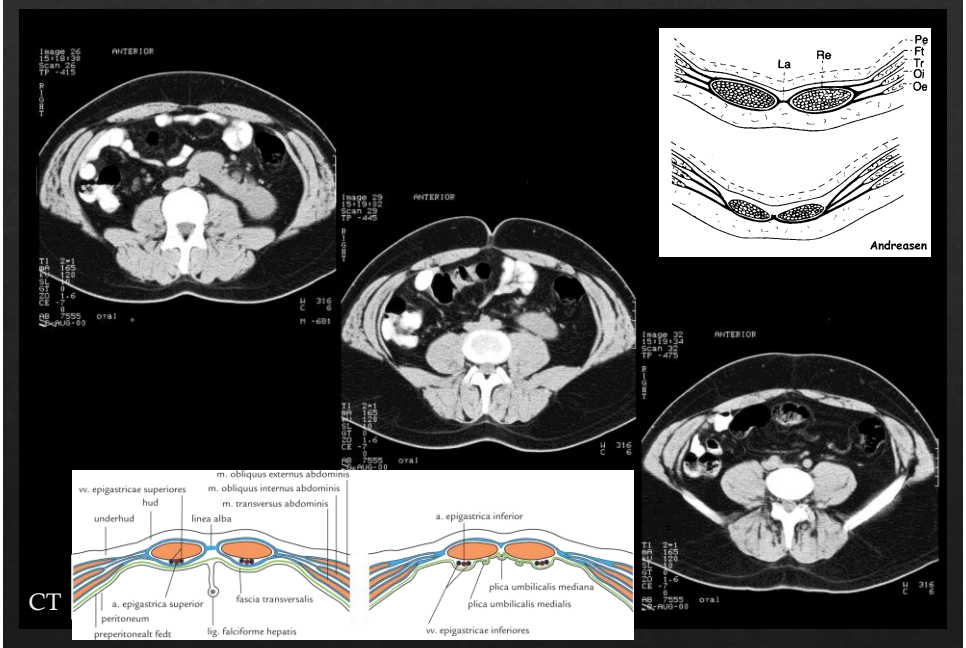

110

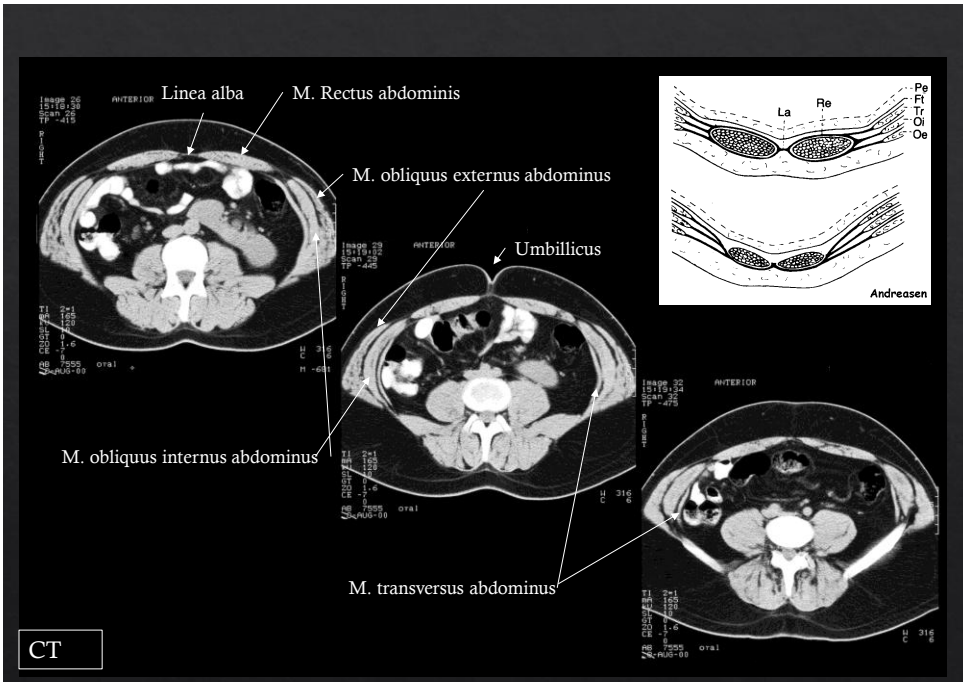

Michel Bach Hellfritzsch 111

111

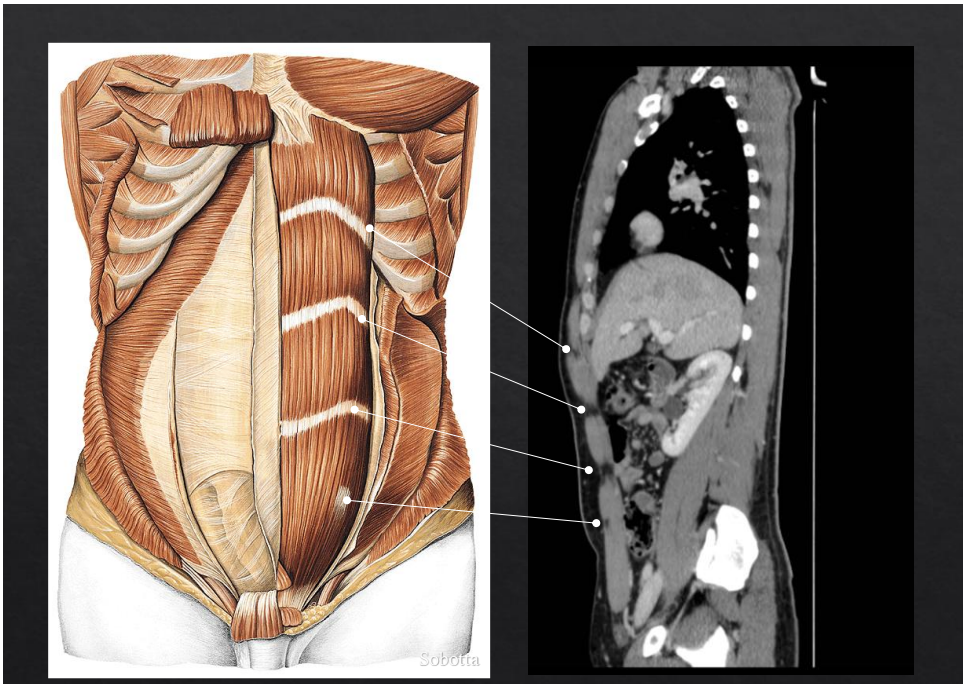

Michel Bach Hellfritzsch 112

112

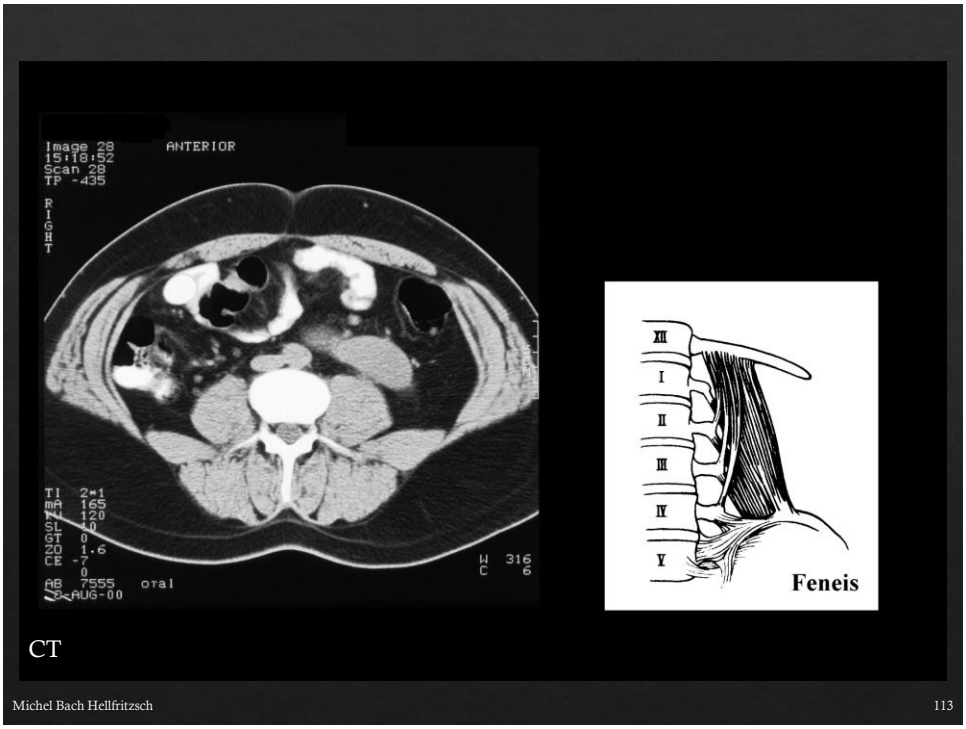
Image 28
15:18:52
Scan 28
TP -435
ANTERIOR
RIGHT
TI 2*1
mA 165
KV 120
SL 10
GT 0
ZO 1.6
CE -7
0
AB 7555 oral
AUG-00
W 316
C 6
XII
I
II
III
IV
V
Feneis
CT
Michel Bach Hellfritzsch
113

113

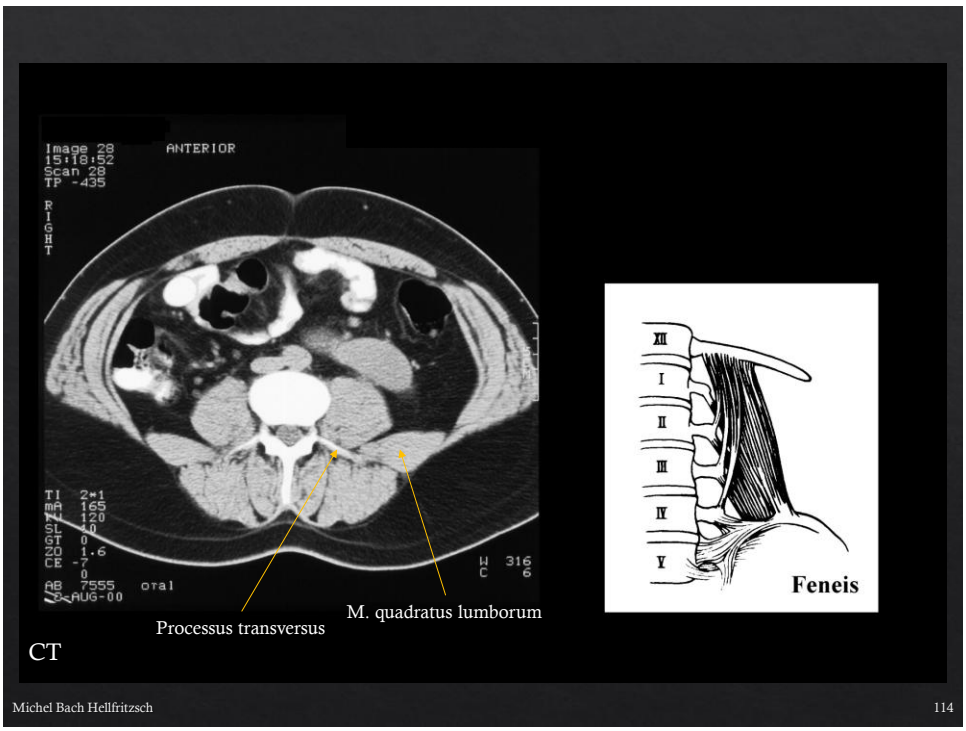
Image 28
15:18:52
Scan 28
TP -435
ANTERIOR
RIGHT
TI 2*1
mA 165
KV 120
SL 10
GT 0
ZO 1.6
CE -7
0
AB 7555 oral
AUG-00
W 316
C 6
Processus transversus
M. quadratus lumborum
XII
I
II
III
IV
V
Feneis
CT
Michel Bach Hellfritzsch
114

114

Diaphragma

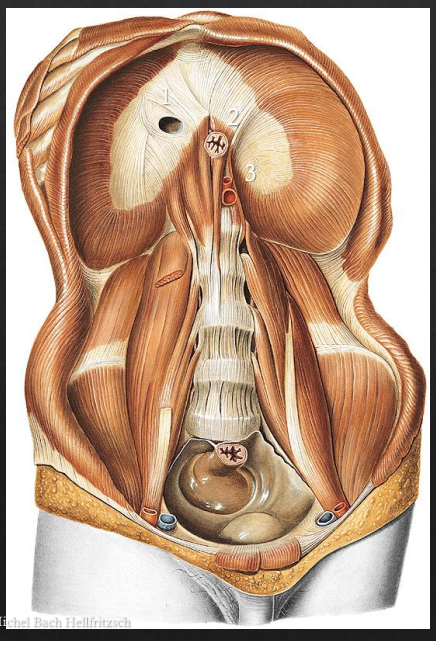

1) Foramen venae cavae
2) Hiatus esophageus
3) Hiatus aorticus

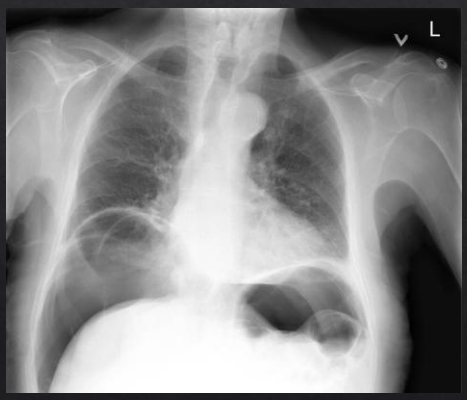

Pneumoperitoneum efter ERCP

115

Diaphragma

Under normale omstændigheder, ses ikke pneumoperitoneum. Der skal således altid være en god forklaring på fundet, eksempelvis de første dage efter en abdominal operation. Ellers må man mistænke perforation af et hulorgan, (ventrikel, tynd- eller tyktarm). Luften i sig selv vil blive resorberet igen, men der kan også lække tarmindhold med bakterier ud i peritoneum, således der opstår betændelse i bughulen, kaldet peritonit.
På den foreliggende stående røntgenoptagelse af thorax, ses diaphragma kuplerne tydeligt, pga. de luftholdige lunger kranielt og luften i peritoneum kaudalt herfor.

Pneumoperitoneum, luft i bughinden, opstået efter en kikkertundersøgelse af galdevejene og pancreas (Endoskopisk retrograd cholangio-pancreaticoskopi).

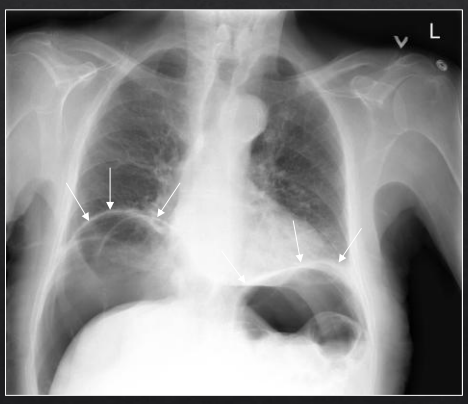

Pneumoperitoneum efter ERCP

116

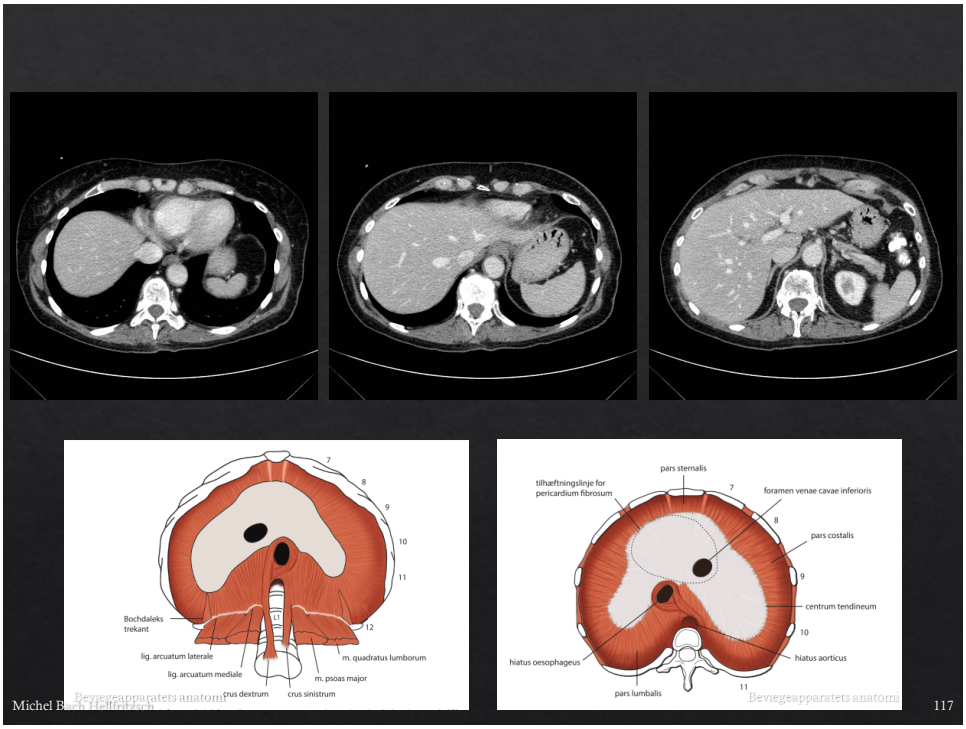
7
8
9
10
11
12
L1
Bochdaleks trekant
lig. arcuatum laterale
lig. arcuatum mediale
m. quadratus lumborum
m. psoas major
crus dextrum
crus sinistrum
pars sternalis
tilhæftningslinje for pericardium fibrosum
foramen venae cavae inferioris
pars costalis
centrum tendineum
hiatus oesophageus
hiatus aorticus
pars lumbalis
Bevægeapparatets anatomi
Michel Bach Hellfritzsch
117

117

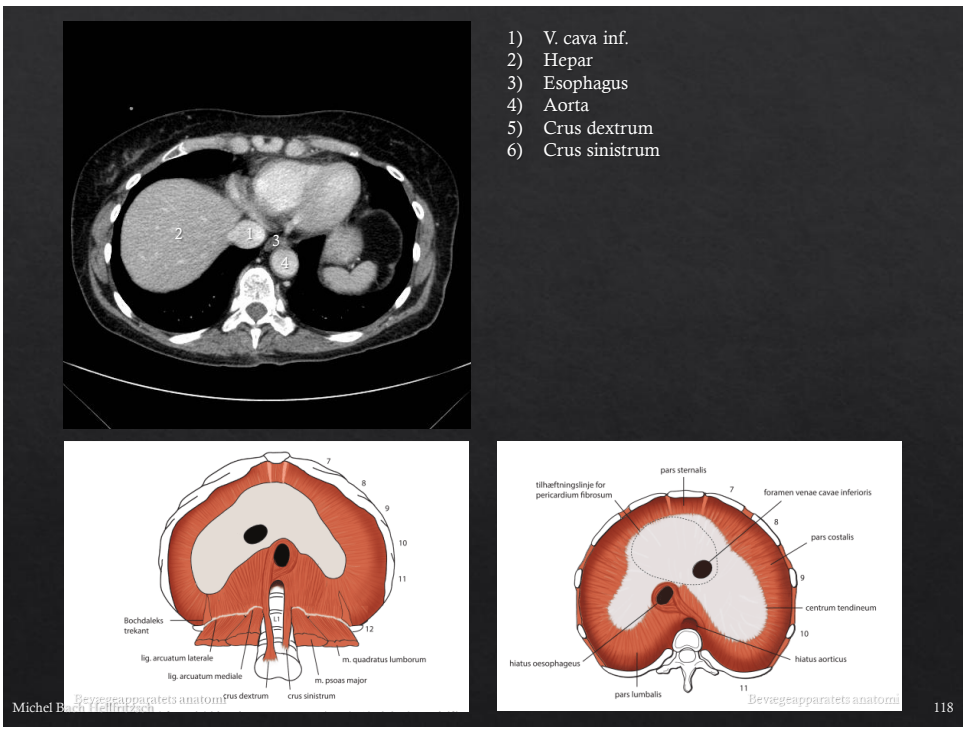
1) V. cava inf.
2) Hepar
3) Esophagus
4) Aorta
5) Crus dextrum
6) Crus sinistrum
2
1
3
4
7
8
9
10
11
12
L1
Bochdaleks trekant
lig. arcuatum laterale
lig. arcuatum mediale
m. quadratus lumborum
m. psoas major
crus dextrum
crus sinistrum
pars sternalis
tilhæftningslinje for pericardium fibrosum
foramen venae cavae inferioris
pars costalis
centrum tendineum
hiatus oesophageus
hiatus aorticus
pars lumbalis
Bevægeapparatets anatomi
Michel Bach Hellfritzsch
118

118



1) V. cava inf.
2) Hepar
3) Esophagus
4) Aorta
5) Crus dextrum
6) Crus sinistrum

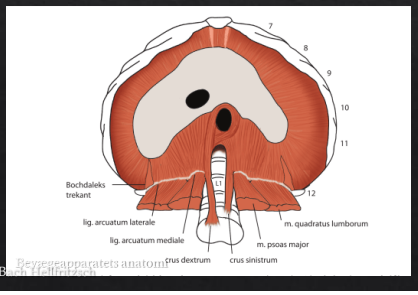

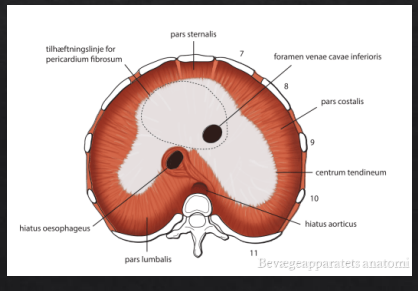

Bevægeapparatets anatomi

119



1) V. cava inf.
2) Hepar
3) Esophagus
4) Aorta
5) Crus dextrum
6) Crus sinistrum

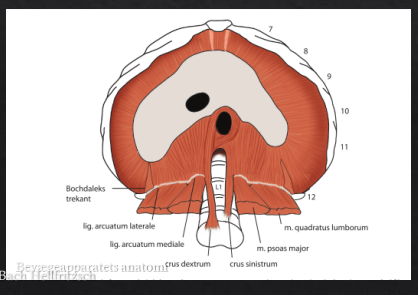

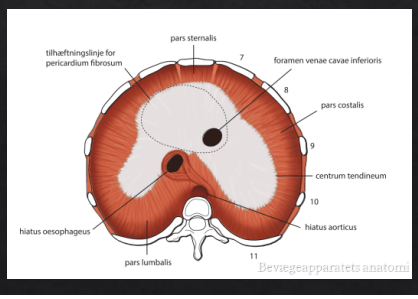

Bevægeapparatets anatomi

120

Hernie (Brok)

Abnorm fremtrængen af et organ (eller en del deraf) gennem væggen af en legemshule, almindeligvis peritonealhulen

121

Hernie (Brok)

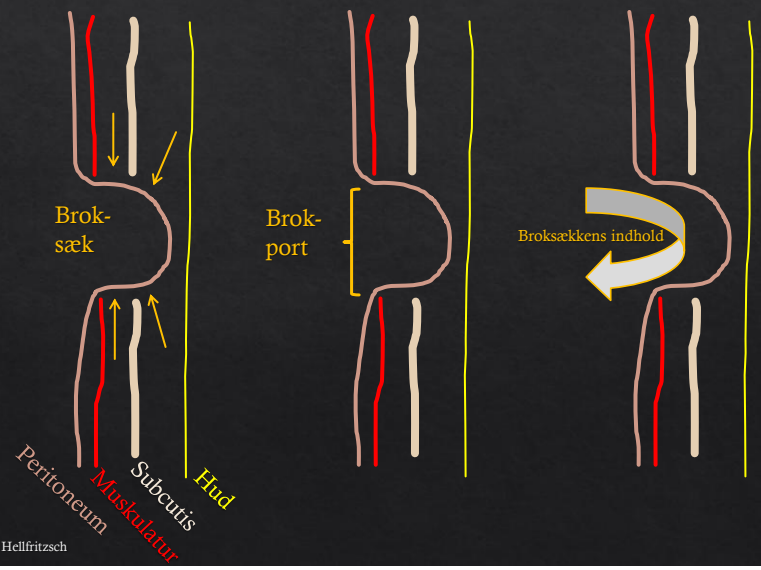

122

Umbilicalhernie

123



124

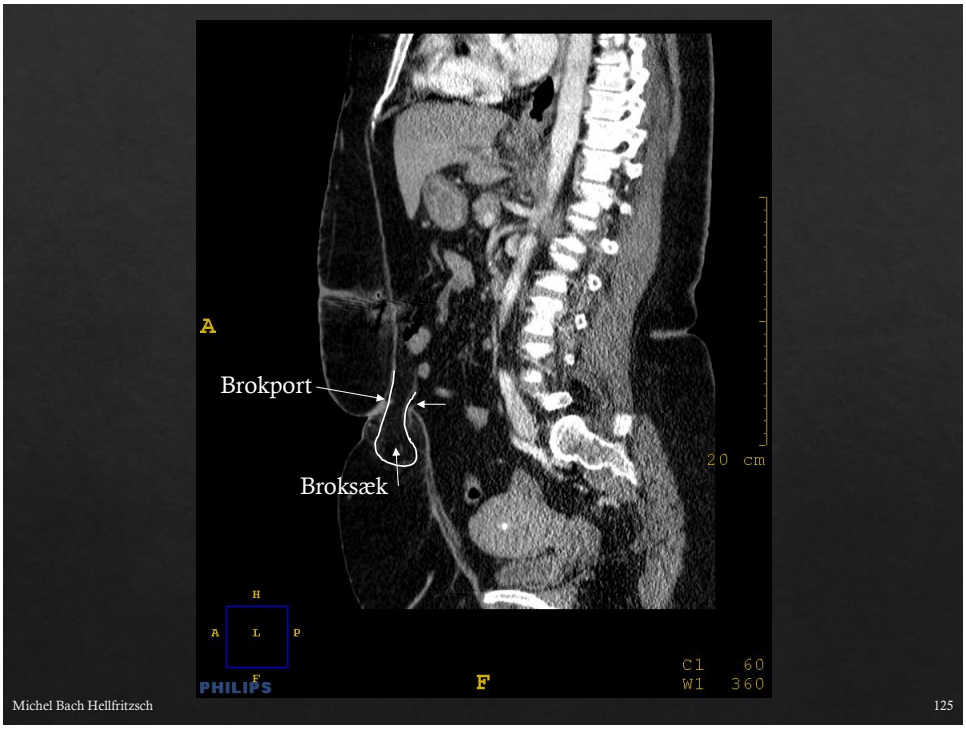
A
Brokport
Broksæk
20 cm
H
A
L
P
F
PHILIPS
F
C1 60
W1 360
Michel Bach Hellfritzsch
125

125


R
20 cm
A
R
F
L
P
PHILIPS
P
C1 60
W1 360
Michel Bach Hellfritzsch
126

126


R
20 cm
A
R F L
P
C1 60
W1 360
P
PHILIPS
Michel Bach Hellfritzsch
127

127


R
20 cm
A
R F L
P
C1 60
W1 360
P
PHILIPS
Michel Bach Hellfritzsch
128

128

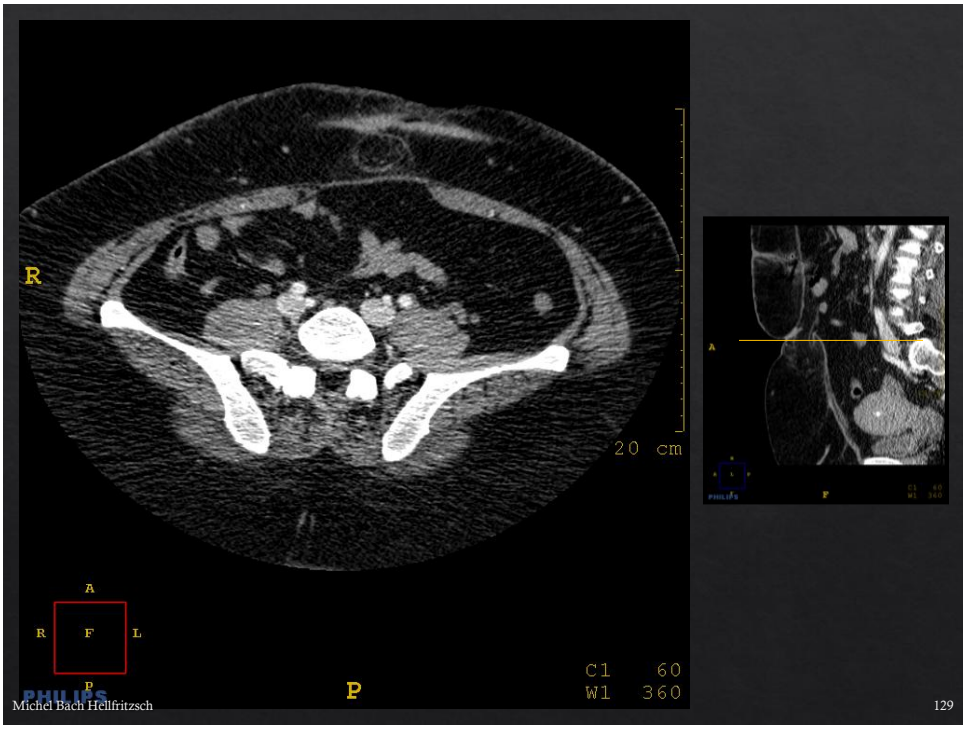
R
20 cm
A
R
F
L
P
PHILIPS
P
C1 60
W1 360
Michel Bach Hellfritzsch
129

129


Diaphragma hernie
Michel Bach Hellfritzsch
130

130

Diaphragma

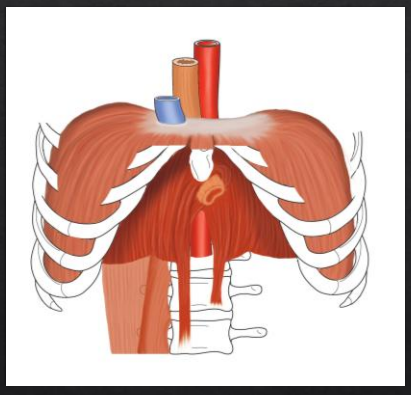

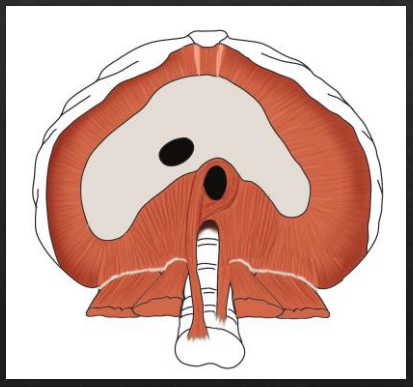

Michel Bach Hellfritzsch 131

131

Nyfødt med respiratoriske problemer.
Røntgen af thorax kort tid efter fødslen.

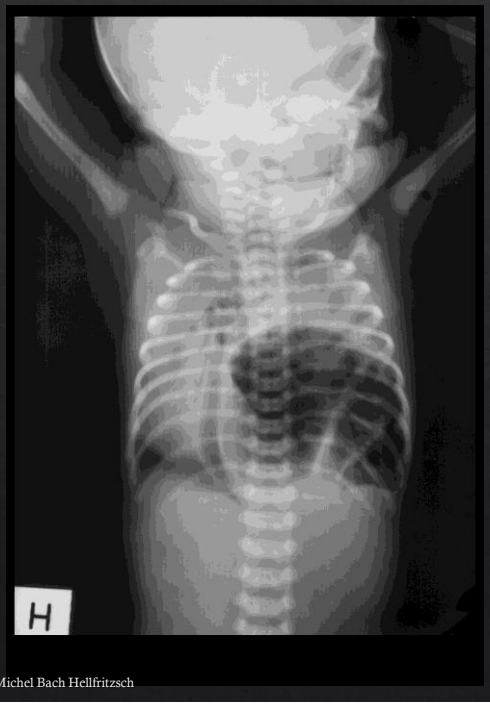

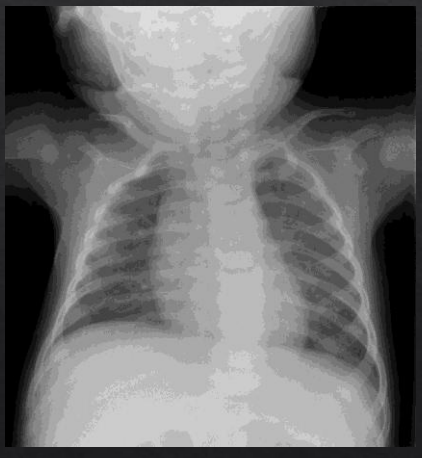

Til sammenligning: Normal undersøgelse, 5 månder gammel.

Michel Bach Hellfritzsch 132

132

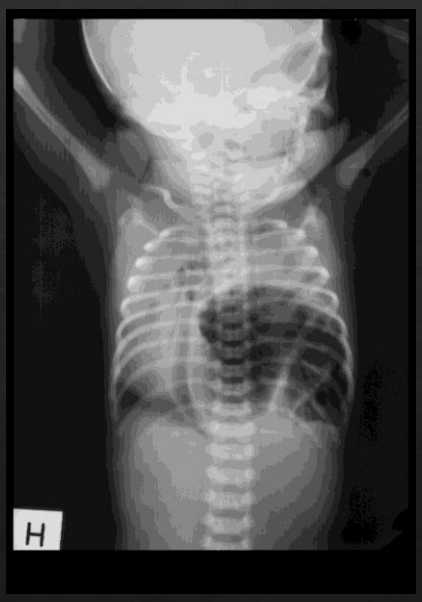

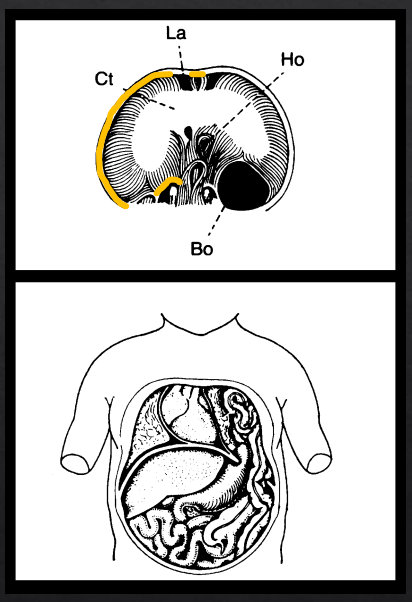

Kongenit diafragmahernie

Michel Bach Hellfritzsch 133

133

Inguinalhernie

Michel Bach Hellfritzsch 134

134

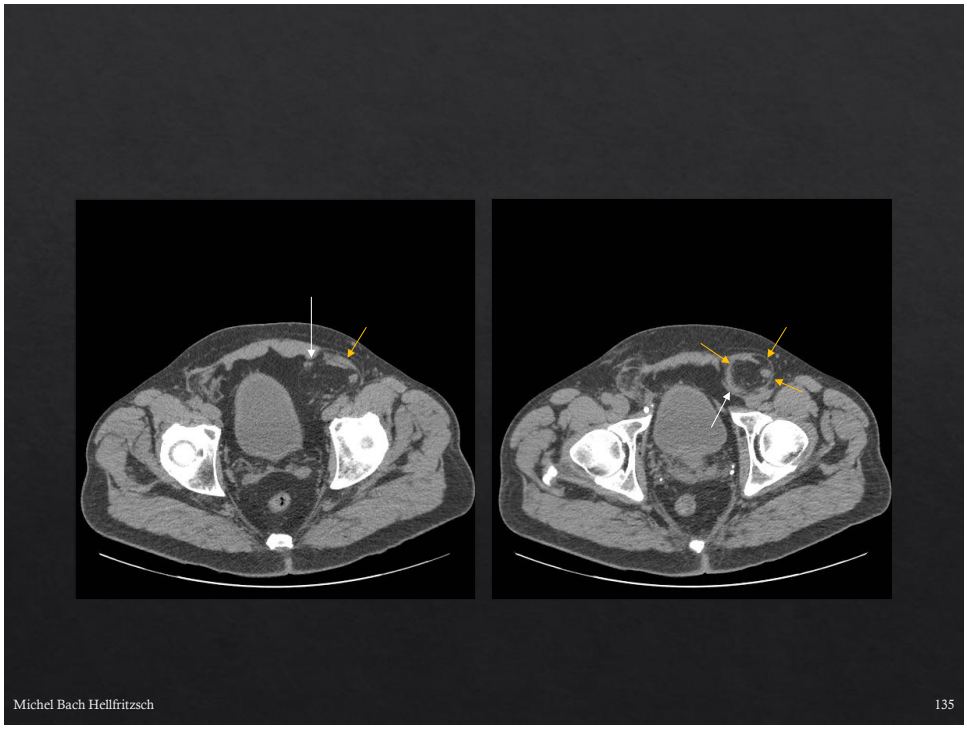

135

Intern hernie

136

Interne hernier:

Foramen epiploicum

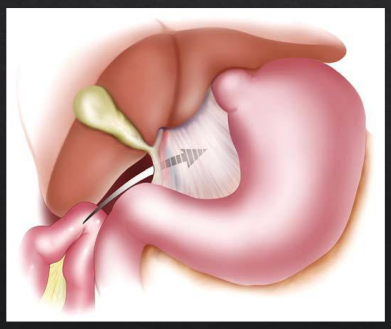

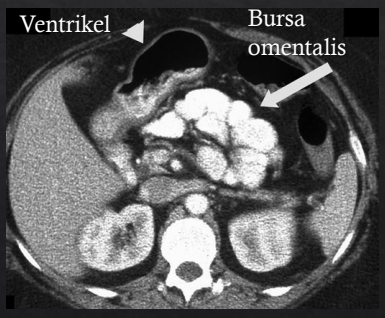

L. C. Martin et al. AJR:186, March 2006

Michel Bach Hellfritzsch

137

137