Non Accidental Injury (NIA)
Battered Child Syndrome
Børn udsat for fysisk overgreb

Michel Bach Hellfritzsch
Overlæge
Røntgen og Skanning
Aarhus Universitetshospital

1





https://pure.au.dk/ws/portalfiles/portal/452566386/Haandbog_Mistanke_om_overgreb_mod_boern.pdf

2

Indledning

3

Villadsen et al. 2014

Procentvis fordeling af lægernes svar med hensyn til, hvilke frakturer de fandt typiske for *battered child syndrome* hos børn under 18 måneder.

	Femurfraktur			Corner-fraktur			Collum costae-fraktur		
	ja	nej	ved ikke	ja	nej	ved ikke	ja	nej	ved ikke
Speciallæge (n = 11)	82	0	18	18	37	46	54,5	18	27,5
Reservelæge (n = 8)	50	37,5	12,5	37,5	25	37,5	75	25	0

Villadsen et al.: "Skadestuelægers kendskab til battered child syndrome er mangelfuldt", Ugeskr Læger 2014, 176: 749-751

4

Villadsen et al. 2014

- Vores undersøgelse viser, at to tredjedele af de deltagende læger angav at have tilstrækkelig faglig viden om BCS.
- To tredjedele af speciallægerne og halvdelen af reservelægerne ville underrette til sociale myndigheder eller en pædiatrisk afdeling alene på mistanken.
- På den baggrund kan manglende faglig viden om BCS kombineret med tilbageholdenhed, hvad angår underretning, være en mulig årsag til de få underretninger af BCS, som anført herover.

Villadsen et al.: "Skadestuelægers kendskab til battered child syndrome er mangelfuldt", Ugeskr Læger 2014, 176: 749-751

5

Villadsen et al. 2014

Det faglige vidensniveau hos behandlende læger uanset anciennitet på udvalgte skadestuer/akutmodtagelser er med denne undersøgelse fundet at være utilfredsstillende.

Villadsen et al.: "Skadestuelægers kendskab til battered child syndrome er mangelfuldt", Ugeskr Læger 2014, 176: 749-751

6

- Op til 55% af mishandlede børn med dødelig udgang har været i kontakt med sundhedsvæsenet inden for den seneste måned.
- Det præmobile barn er mindre udsat for hændelige uheld, og jo mindre det er, jo mere sandsynligt er det at frakturen er påført.
- Svære skader kan også omfatte thorax, abdomen og/eller hjernen (Non Accidental Head Injury - NAHI)
- Radiologen har ansvar for at tage øjeblikkelig kontakt til henvisende læge angående abnorme fund

7

Af barnets lov § 133 fremgår:

"*Personer, der udøver offentlig tjeneste eller offentlig hverv, skal underrette kommunalbestyrelsen, hvis de under udøvelsen af tjenesten eller hvervet får kendskab til eller grund til at antage, at:*

1. *et barn eller en ung under 18 år kan have behov for støtte efter denne lov,*
2. *et barn umiddelbart efter fødslen kan få behov for støtte efter denne lov på grund af de kommende forældres forhold,*
3. *et barn eller en ung under 18 år kan have behov for støtte efter denne lov på grund af barnets eller den unges ulovlige skolefravær eller undladelse af at opfylde undervisningspligten, eller*
4. *et barn eller en ung under 18 år har været udsat for overgreb.*"

Som læge, sygeplejerske, sundhedsplejerske, jordemoder, psykolog og autoriseret sundhedsperson i øvrigt gælder således en skærpet underretningspligt".

https://www.sundhed.dk/sundhedsfaglig/laegehaandbogen/socialmedicin/socialmedicinsk-arbejde-med-boern-og-unge/underretningspligten/

8

Radiologens rolle

1) Tilfældige fund

2) Udredning

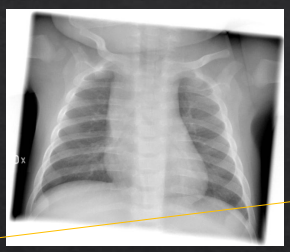

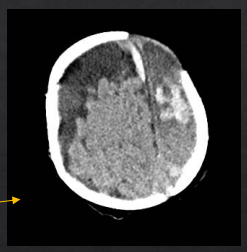



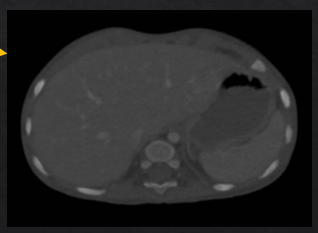

9

Udredning

10

Udredning

- Klinisk undersøgelse
- Rtg. af totalskelet
  - Henvisning fra specialæge i pædiatri
  - Første radiologiske undersøgelse - med mindre der klinisk er indikation for anden undersøgelse
- CT thorax og abdomen hvis klinisk indiceret
  - udføres på samme måde som ved hændeligt uheld.
- Neuroradiologi
  - Encephalopatiske tegn, fokale neurologiske udfald eller retinablødning
  - Børn under 1 år med tegn på fysisk vold
- CT cerebrum
- MR CNS

11

Udredning

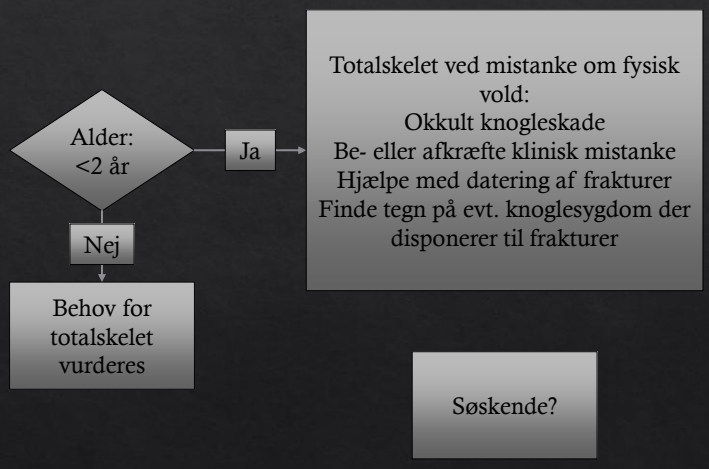

12

Rtg. af totalskelet

- Kranium
  - AP og lateral (Hvis der ikke udføres CT skanning)
- Thorax
  - AP inkl. klavikler
  - Skråoptagelser af thorax (costae)
- Abdomen/bækken
  - AP
- Columna
  - Lateral
  - AP på thorax og bækken
- Ekstremiteter
  - AP af begge humeri
  - AP af begge anbrachii
  - PA af begge hænder
  - AP af begge femora
  - AP af begge crurae
  - DP af begge fødder
  - Evt. suppl. sideoptagelser af albue, håndled, knæ og ankel

13

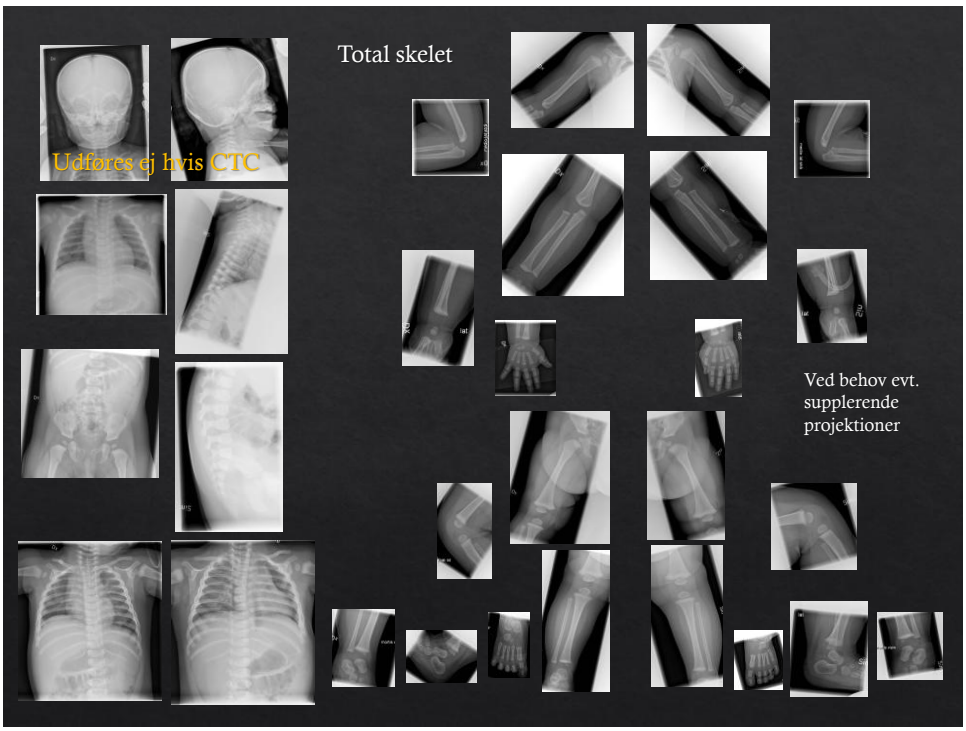

14



Oestreich and Caré

Subperiostal knoglenydannelse og callus ses på konventionel røntgen først efter 9-10 dage.

15



Primær undersøgelse



14-dages kontrol

Klassisk metafysær læsion (CLM) ved primær undersøgelse og ved 14-dages kontrol

16

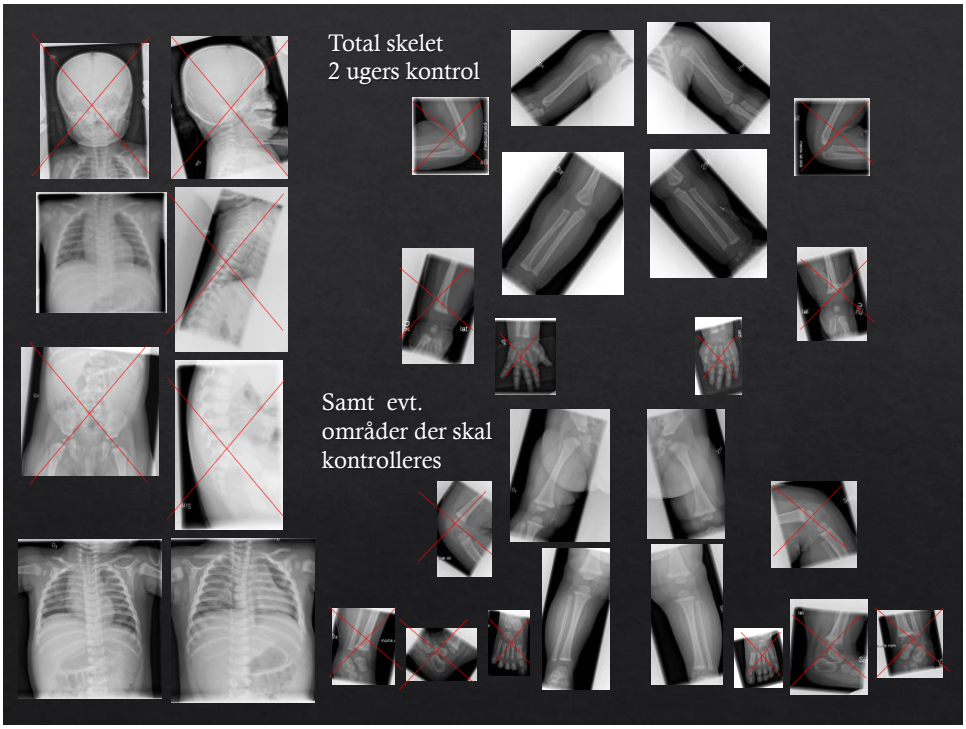

17

Andre modaliteter: CT

18

1 år gammel barn senere undersøgt med CT (obs. abdominal læsion)

19

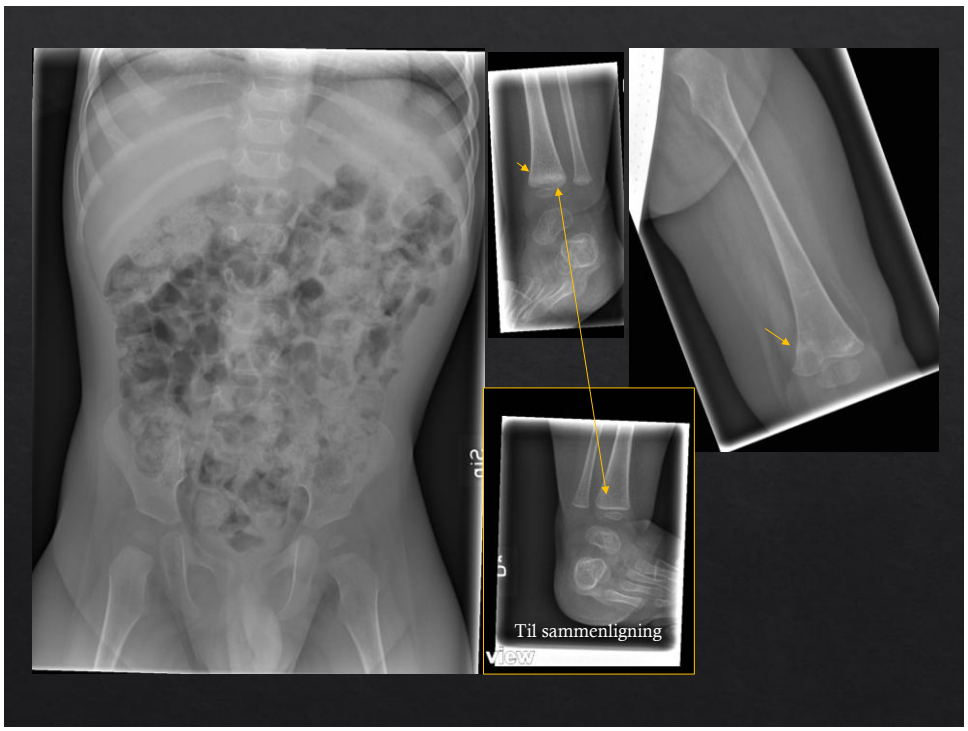

20

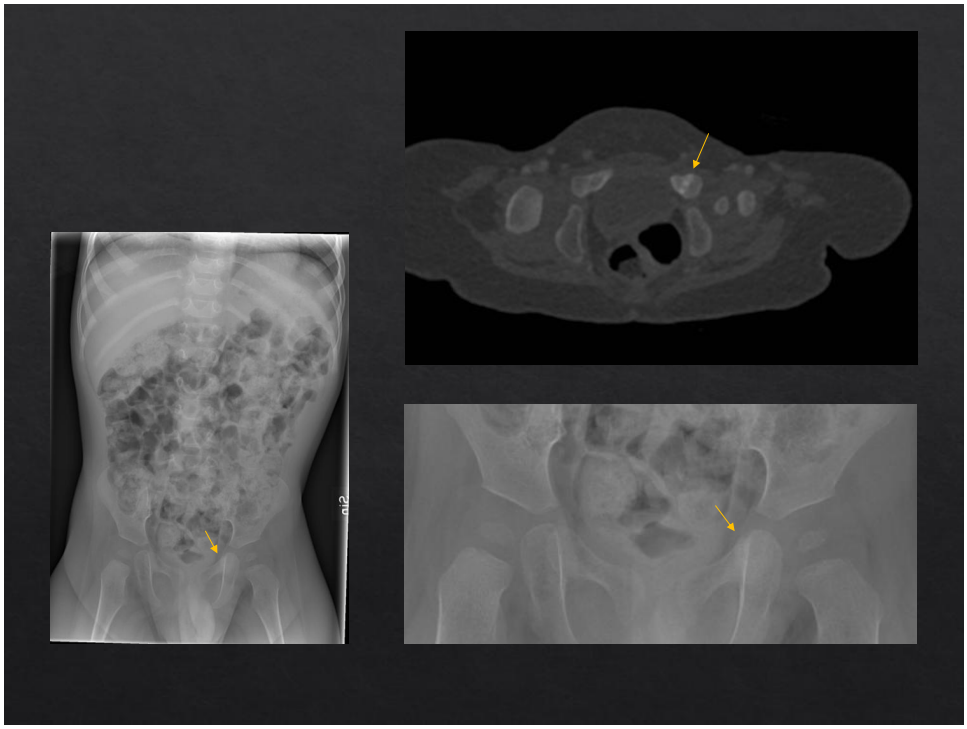

21

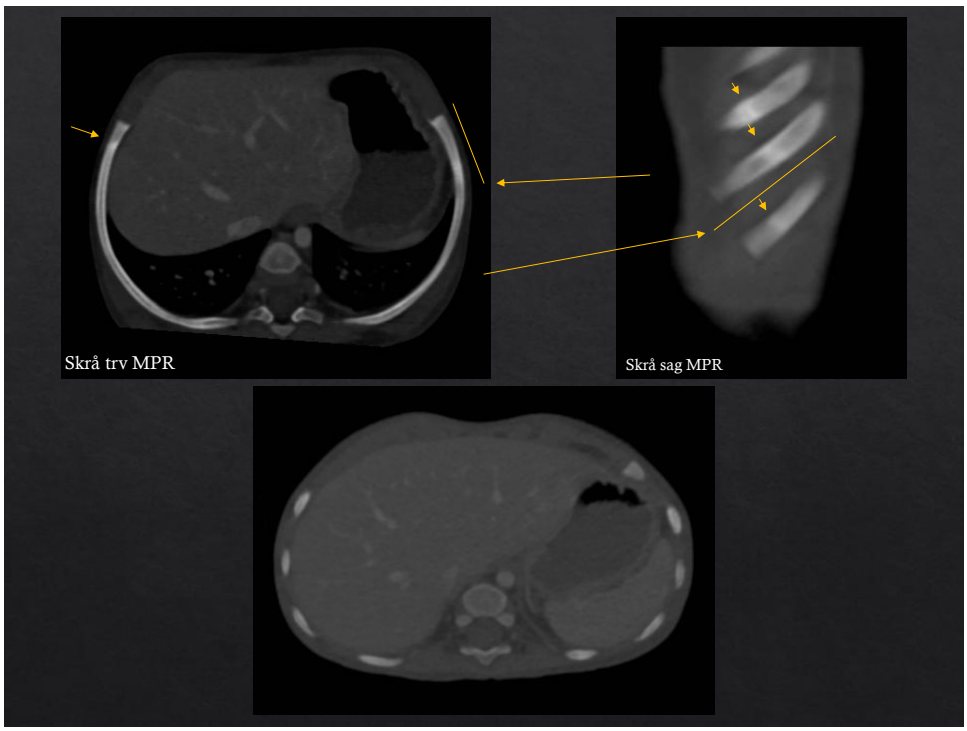

22

Andre modaliteter: UL

23

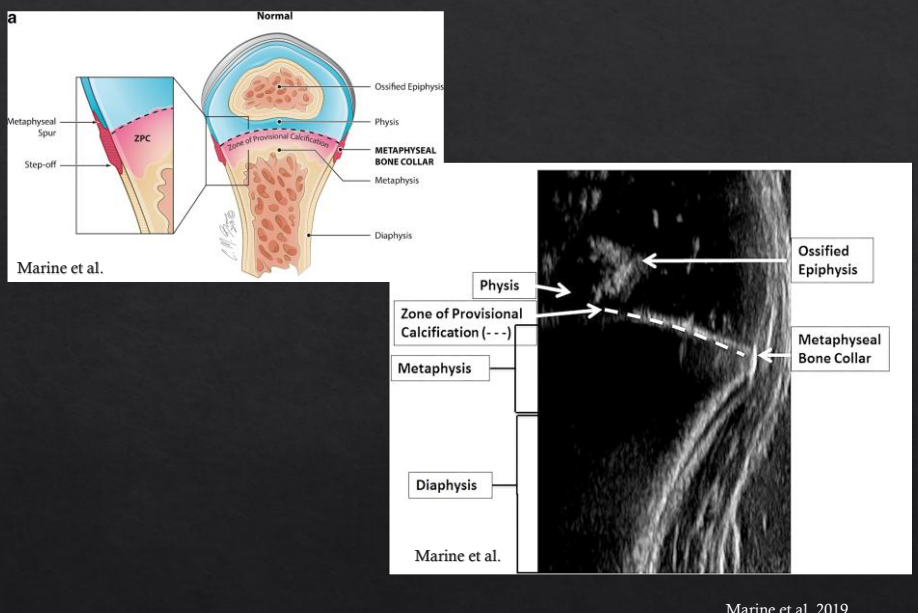

Marine et al. 2019

24

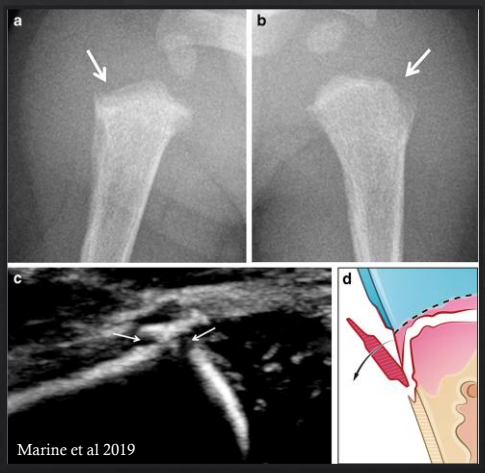

25

Fraktur oversigt

26

Specificity of injuries for child abuse

- **High specificity (highest specificity in infants)**
  - Classic metaphyseal lesions (CML)
  - Rib fractures especially posteromedial
  - Scapular fractures
  - Sternal fractures
  - Spinous process fractures
- **Moderate specificity**
  - Multiple fractures, especially bilateral
  - Fractures of different ages
  - Epiphyseal separations
  - Vertebral body fractures and subluxations
  - Digital fractures
  - Complex skull fractures
  - Pelvic fractures
- **Common but low specificity**
  - Subperiosteal new bone formation
  - Clavicular fractures
  - Long-bone shaft fractures
  - Linear skull fractures

Kleinman 2015

27

Frakturtyper: Alm. frakturer

28

Dreng knap 3 mdr.





29

”Toddlers fracture”









30

”Toddlers fracture” – knap 3 år





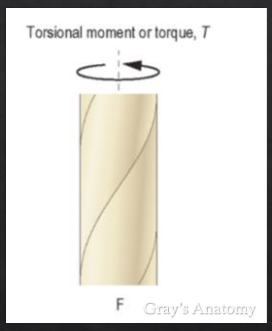

NB! ”Toddlers fracture” når barnet går selvstændigt.

31

Frakturtyper: CML

32

CML: "Classic metaphyseal lesion"

- Specifik fraktur
- Hyppigste lokalisation: Distale femur -> Proximale tibia -> Proximale humerus
- Næsten udelukkende hos børn <2 år.
- Generelt ingen fraktur følger

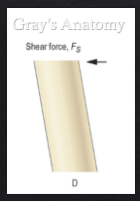



Lonergan 2003

33

CML

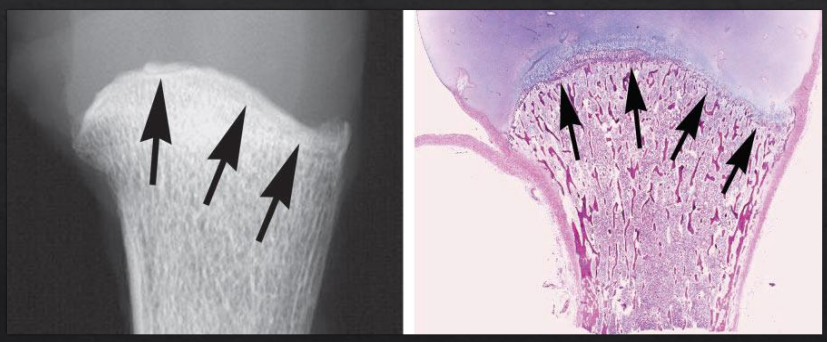

Lonergan et al., RadioGraphics 2003; 23:811–845 (fra Paul Kleinman, MD, The Children's Hospital, Boston, Mass.).

34

CML: Classic metaphyseal lesion

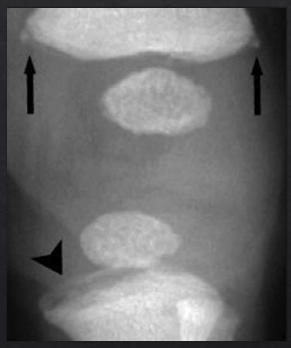

- Corner lesion
- Bucket handle lesion

Stephen Chapman "Non-accidental Injury" in Imaging in pediatric skeletal trauma, Springer

35

CML: Corner lesion vs. Bucket handle lesion



Tsai et al. 2014

36

CML: Classic metaphyseal lesion

- Hyppigste lokalisation: Distale femur -> Proximale tibia -> Distale tibia -> Proximale humerus

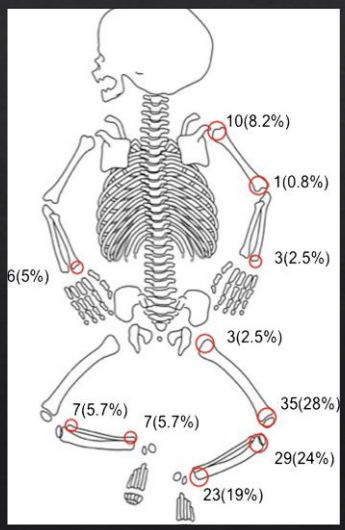

Barber et al 2015

37

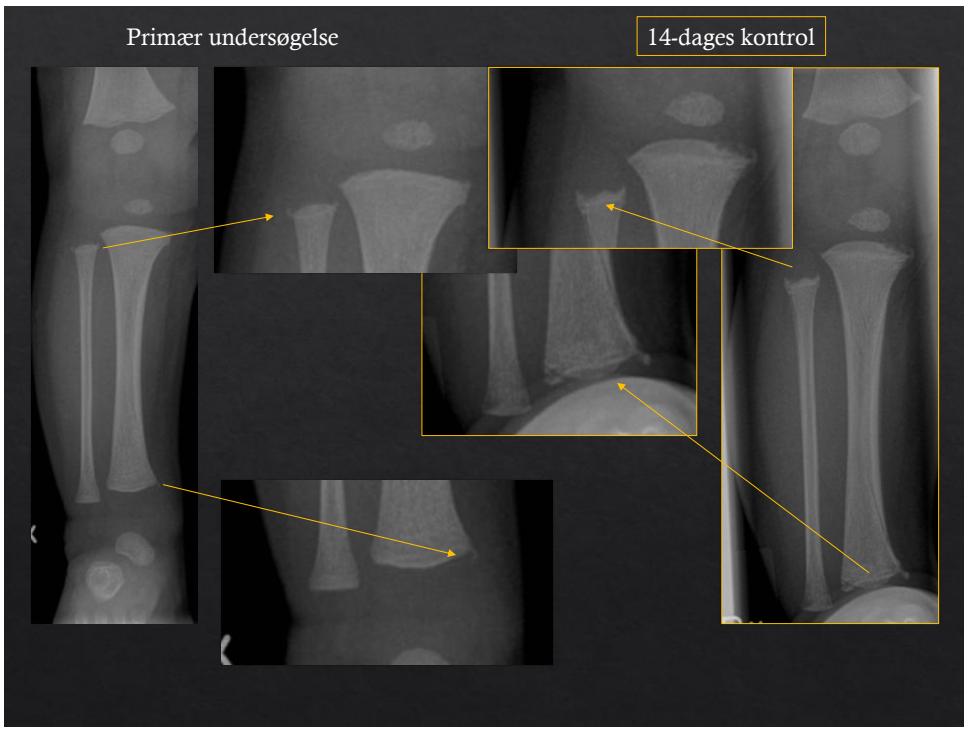

38

Frakturtyper: Costa frakturer

39

Costa fraktur

- Specifik fraktur –især hvis posterior
- Scintigrafi eller CT bedre til at detektere disse frakturer.
- Sjælden ved fødslen
- Sjælden ved Hjerte-Lunge-Redning (HLR). Der er her tale om anteriore frakturer.

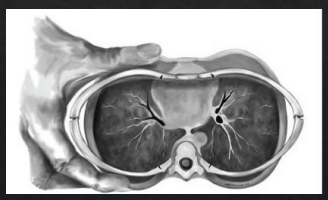

Lonergan et al., RadioGraphics 2003; 23:811–845

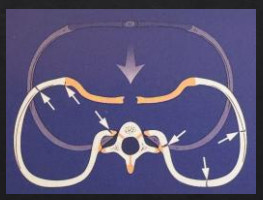

Kleinman: "Diagnostic imaging of child abuse"

40

Fraktur i brusken

41

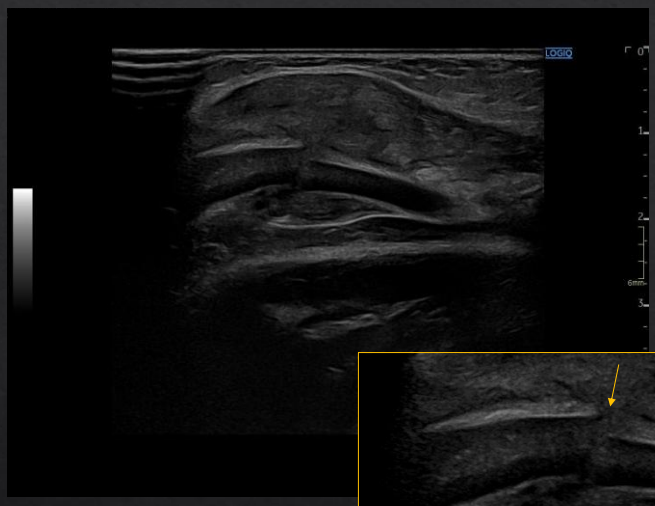

12 måneder gammel barn med brud i den bruskede del af ribbenet

42

Anterior fraktur

43

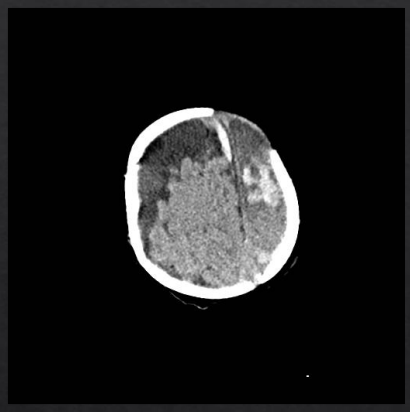



Barn 5 mdr. med hygromer

44

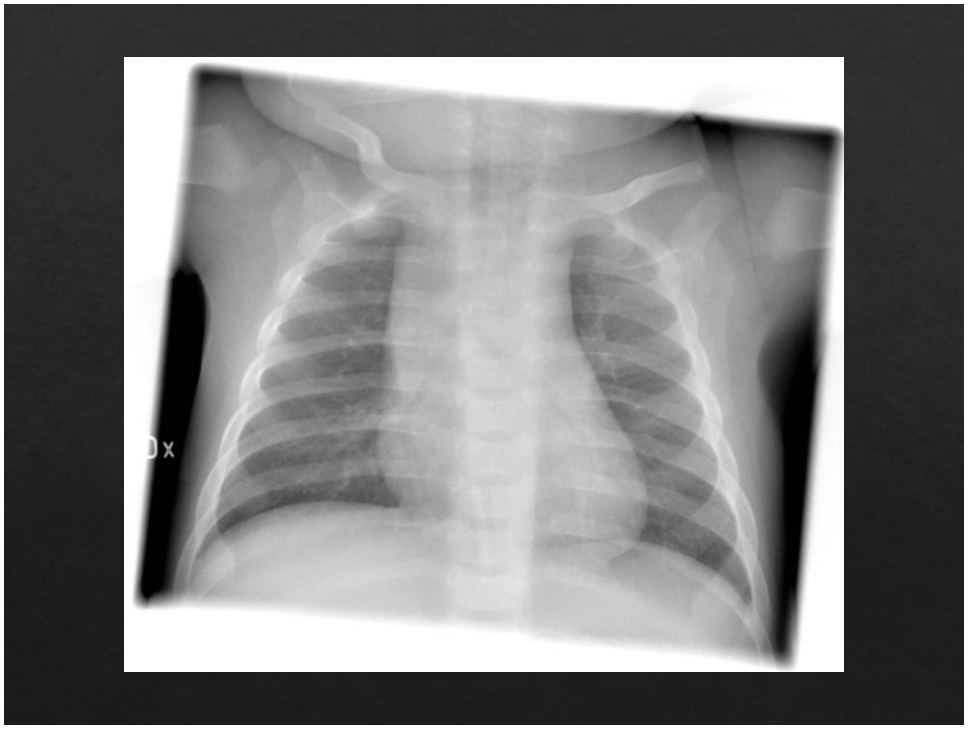

45

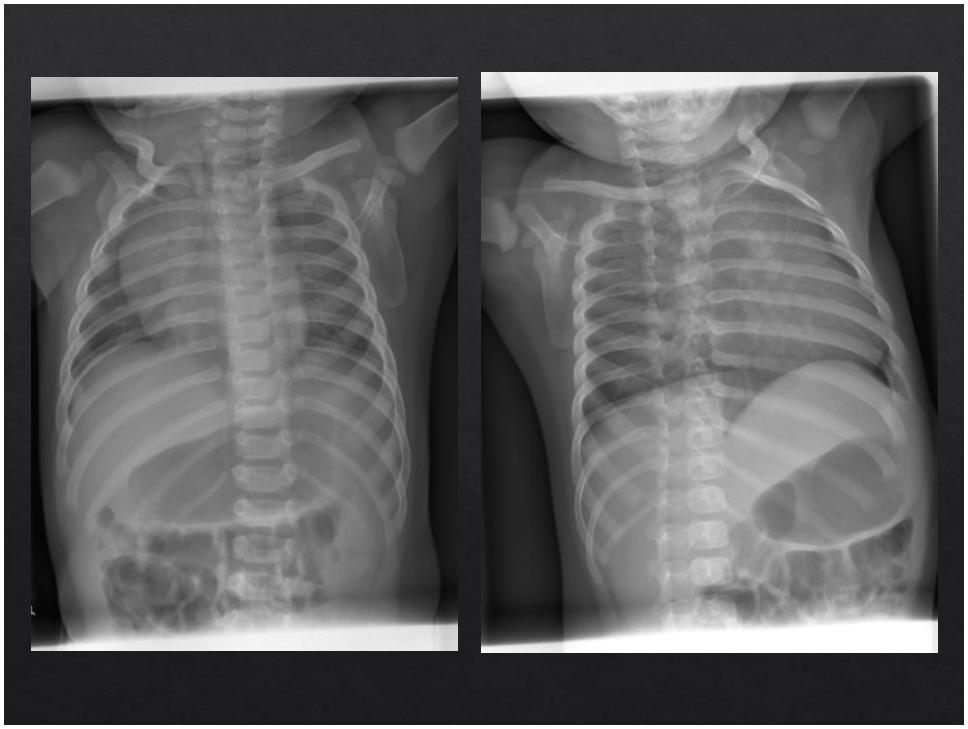

46

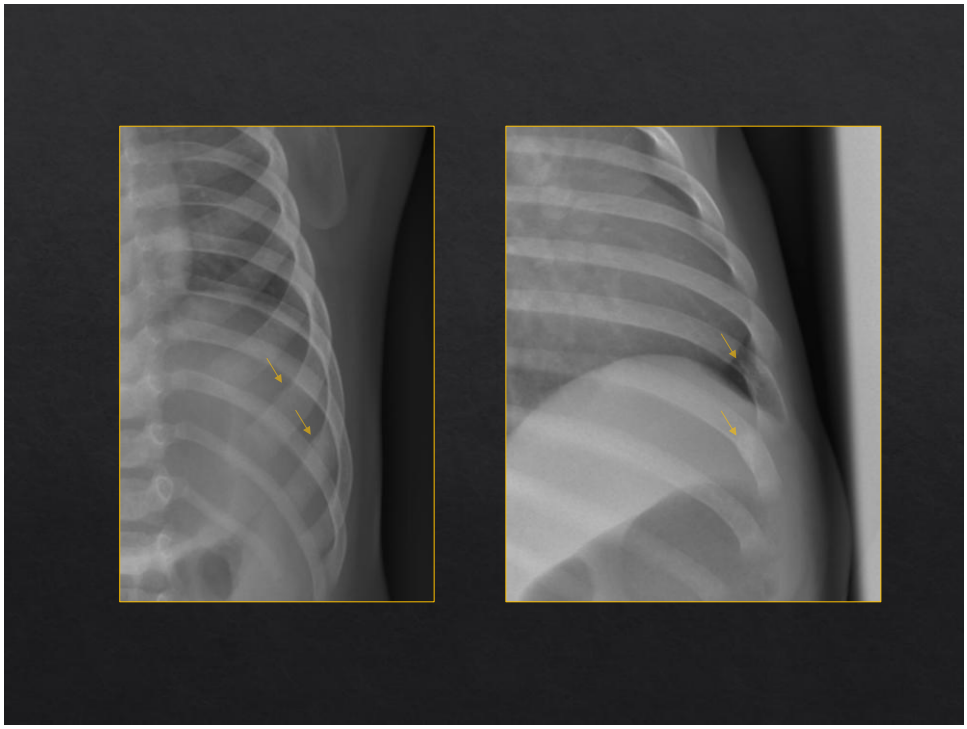

47

Anteriolateral fraktur

48

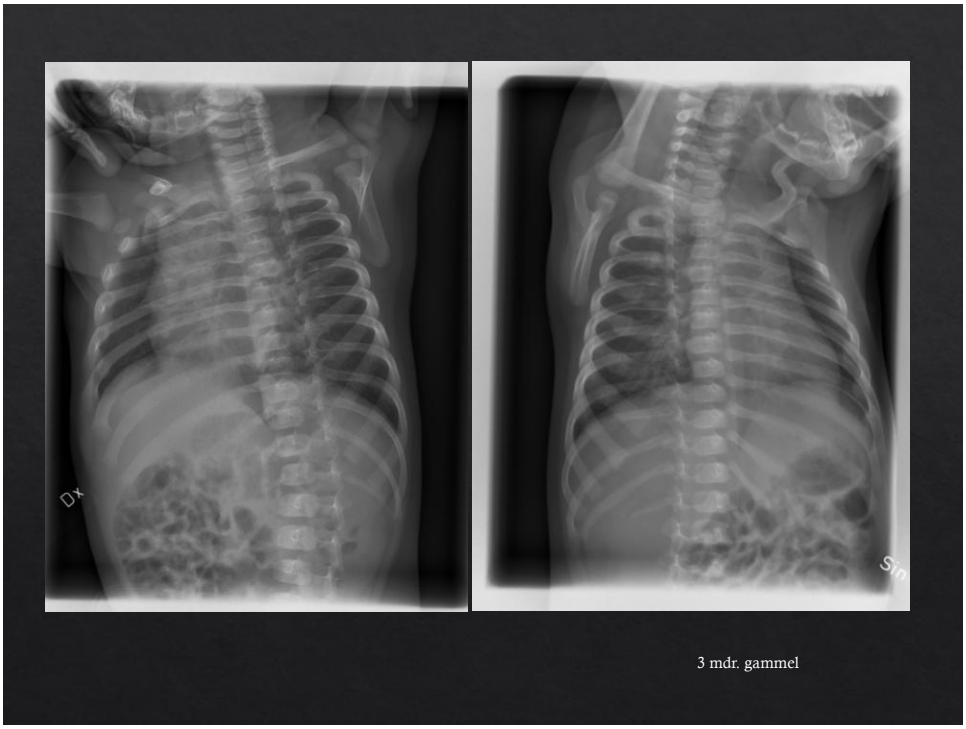

49

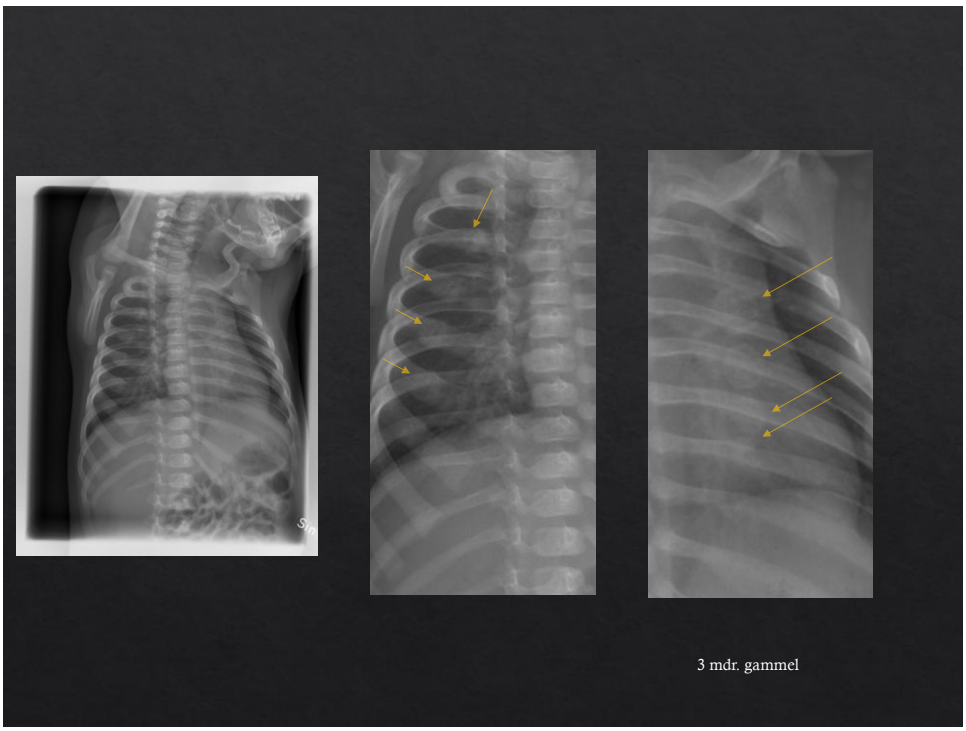

50

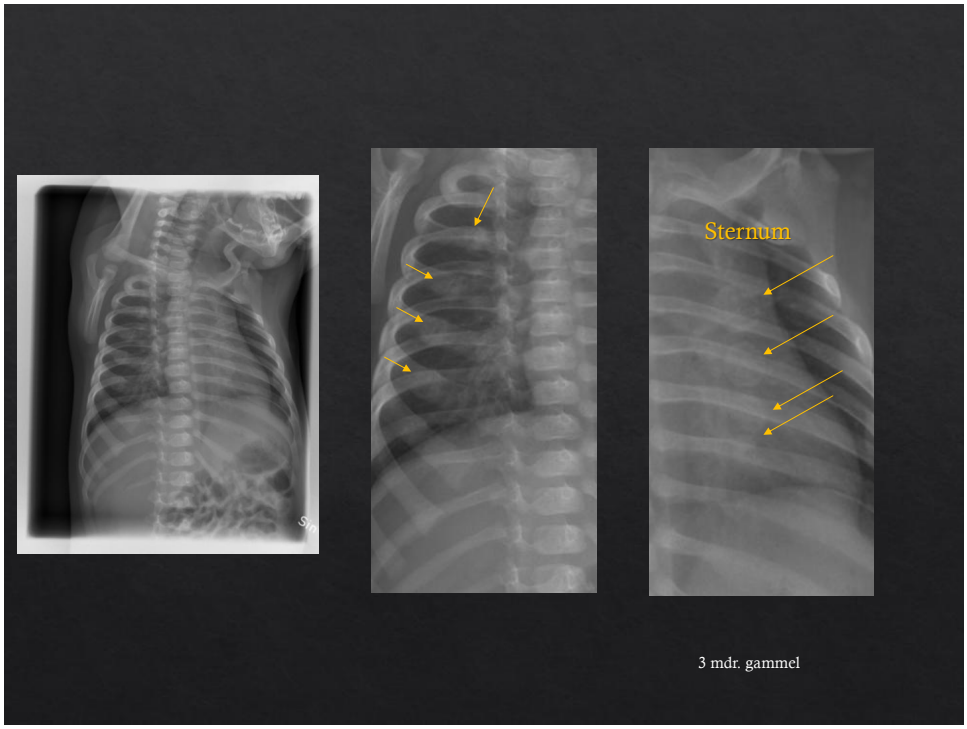

51

Posteriolateral fraktur med 14 dages kontrol

52

Knap 4 mdr. gammel, faldet fra puslebord – obs. klavikel fraktur.



53

Knap 4 mdr. gammel, faldet fra puslebord.

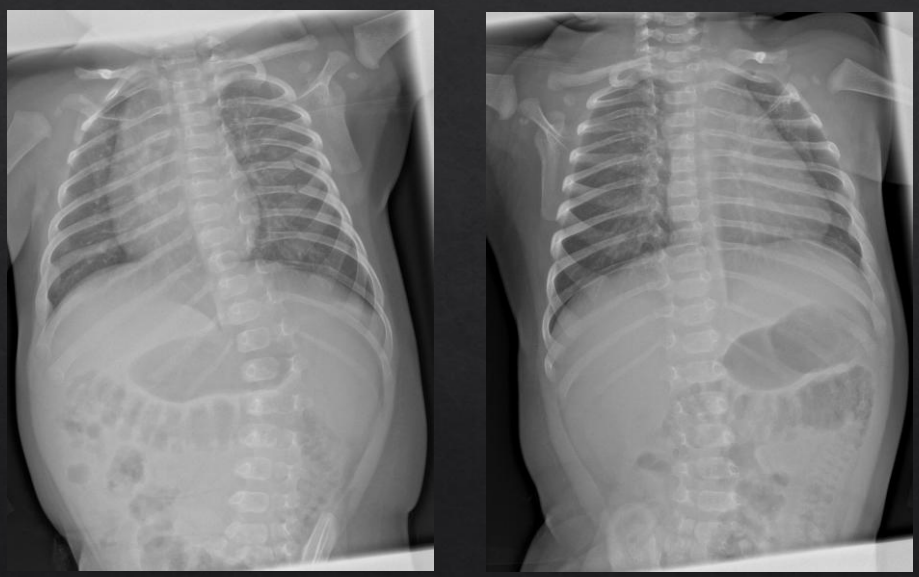

54

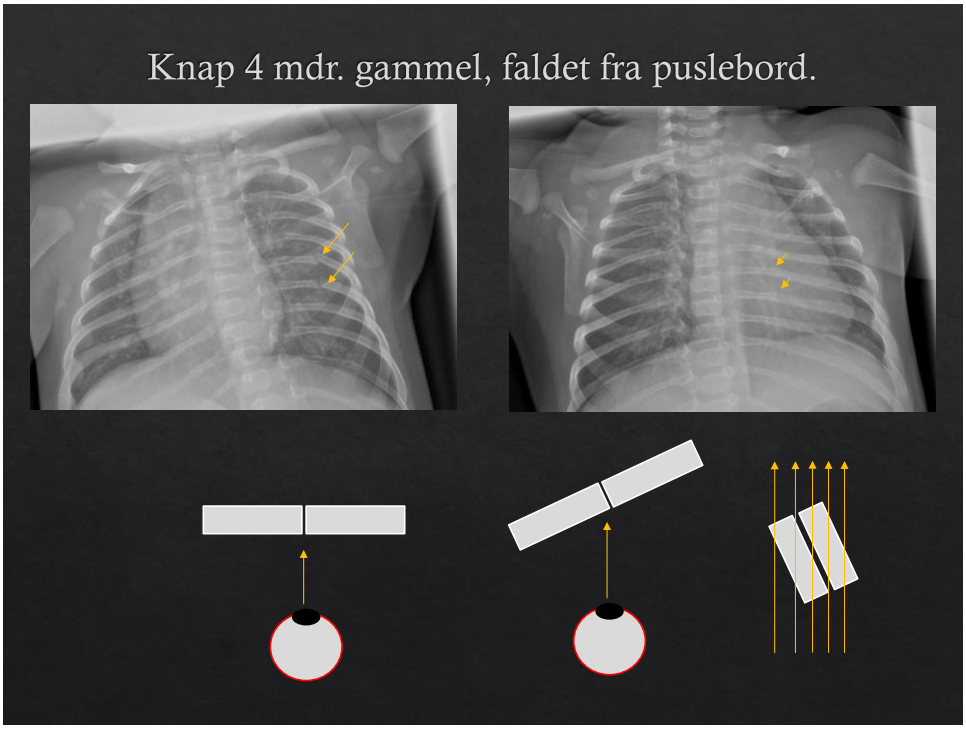
Knap 4 mdr. gammel, faldet fra puslebord.

55

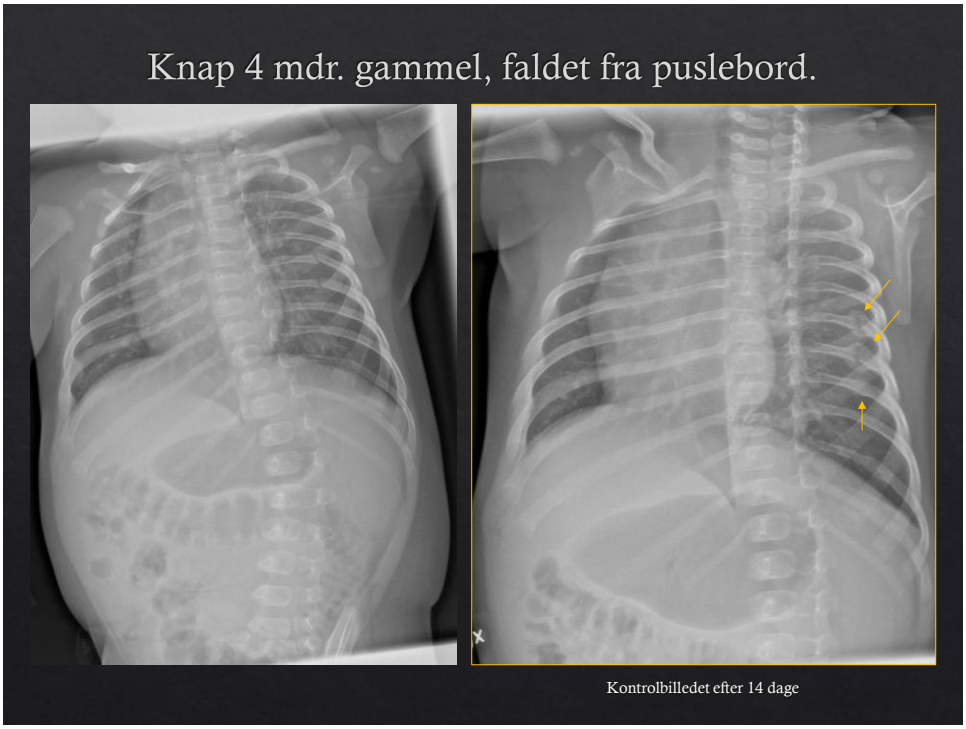
Knap 4 mdr. gammel, faldet fra puslebord.
Kontrolbilledet efter 14 dage

56



Oestreich and Caré

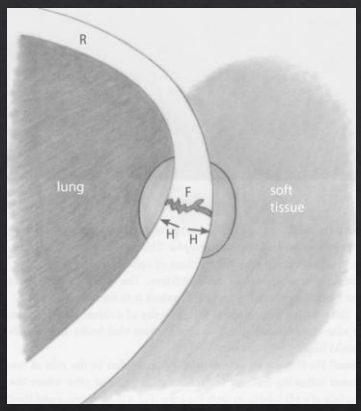

Oestreich and Caré

Callus væv ses på konventionel røntgen først efter 9-10 dage. På medialsiden af costae, ses hæmatomet dog, idet det afgrænses af luftholdig lungevæv.

57

Frakturtyper: Kranie frakturer

58

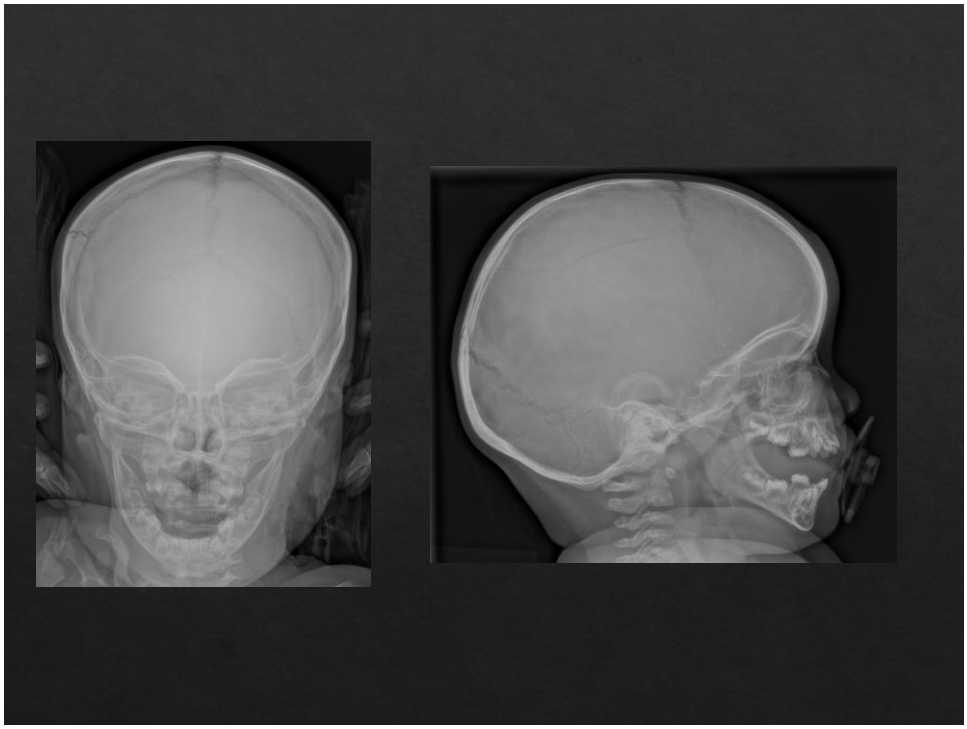

59

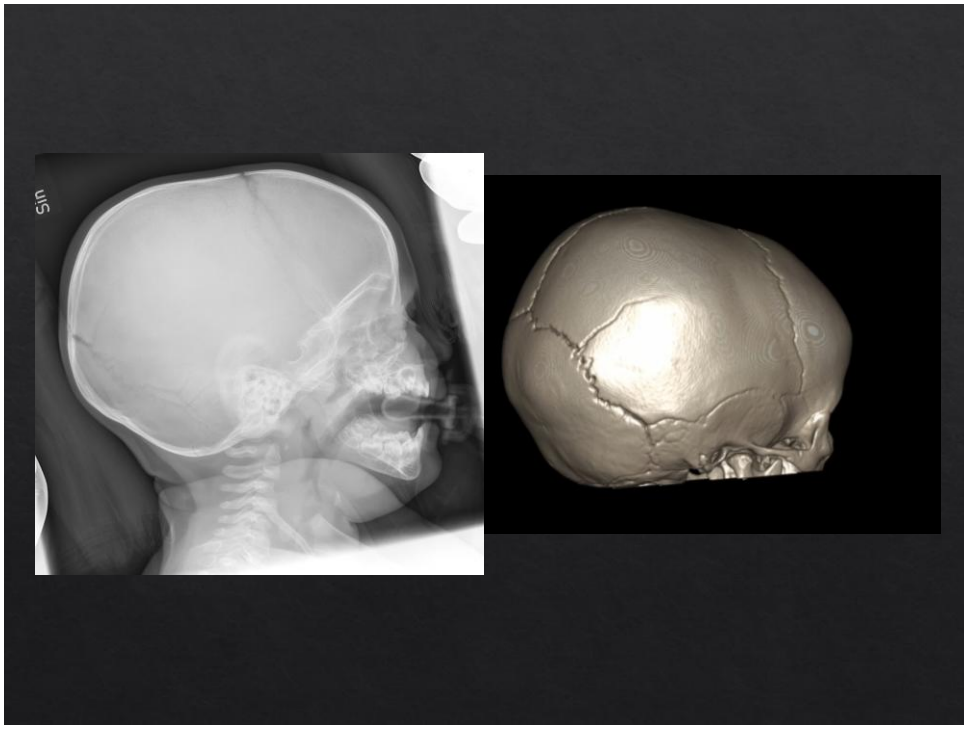

60

Frakturtyper: Columna frakturer

61

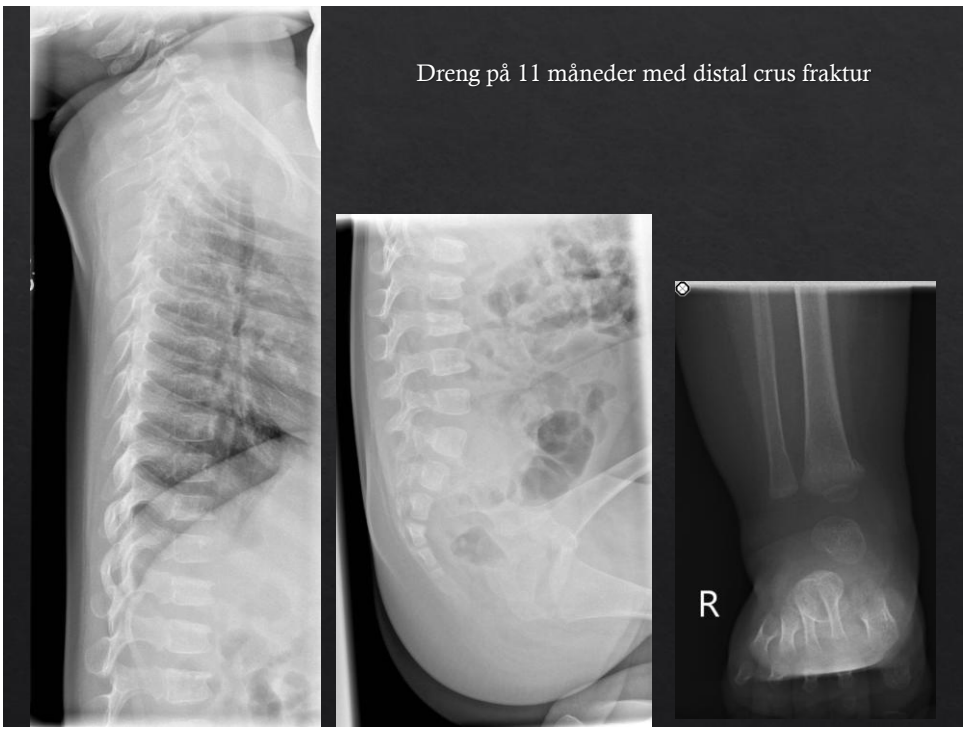

62


Dreng på 11 måneder med distal crus fraktur og multiple hvirvelfrakturer
Pige 8 måneder
til sammenligning
Dreng 13 måneder
til sammenligning

63


Fraktur alder

64

Faser

- Fraktur
- Subperiotal knoglenydannelse (SPNBF)
- Callus
- Remodelering

65

Helings tegn

- Periosteal reaction:
  - Linear and thin (not rounded) elevation and calcification of the periosteum, which is parallel to the shaft of bone, located around or adjacent to the fracture site
- Callus formation:
  - Evidence of healing as new bone is laid down which gradually calcifies and ossifies. It envelops the fracture site. This initially has a 'fluffy' edge followed by a more well demarcated dense edge which is nearly as dense as cortex
- Bridging callus:
  - Fracture line has been completely crossed by intact callus, though the fracture line may or may not remain visible
- Remodelling:
  - Loss of fracture line definition with complete bridging of the fracture gap with continuity of cortical bone

Fra Prosser et al (2012).

66

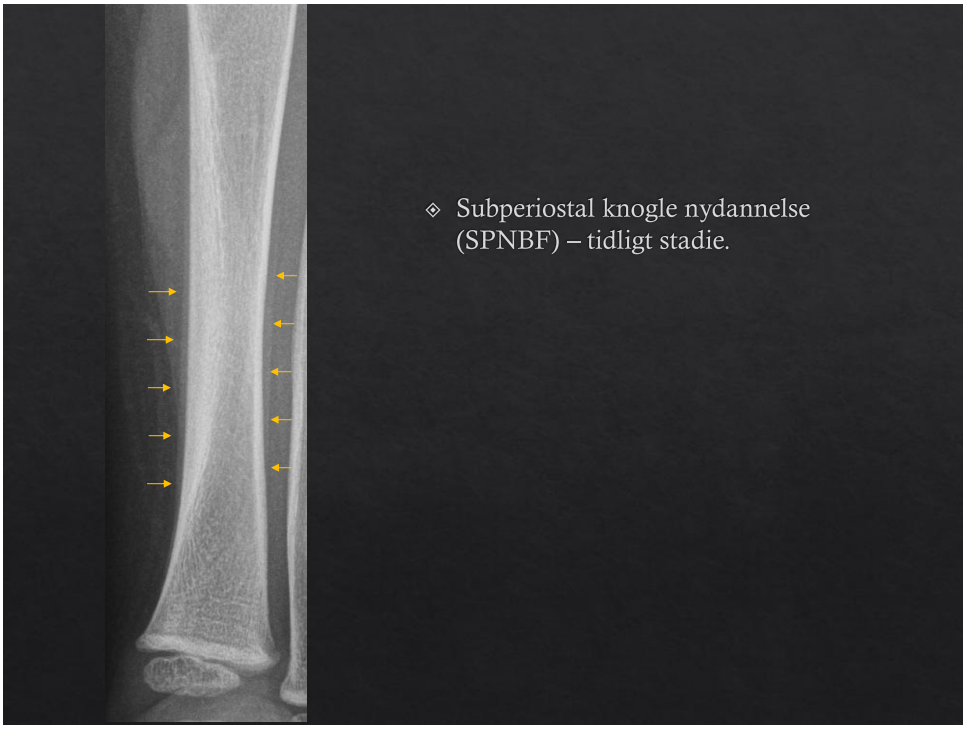
Subperiostal knogle nydannelse (SPNBF) – tidligt stadie.

67

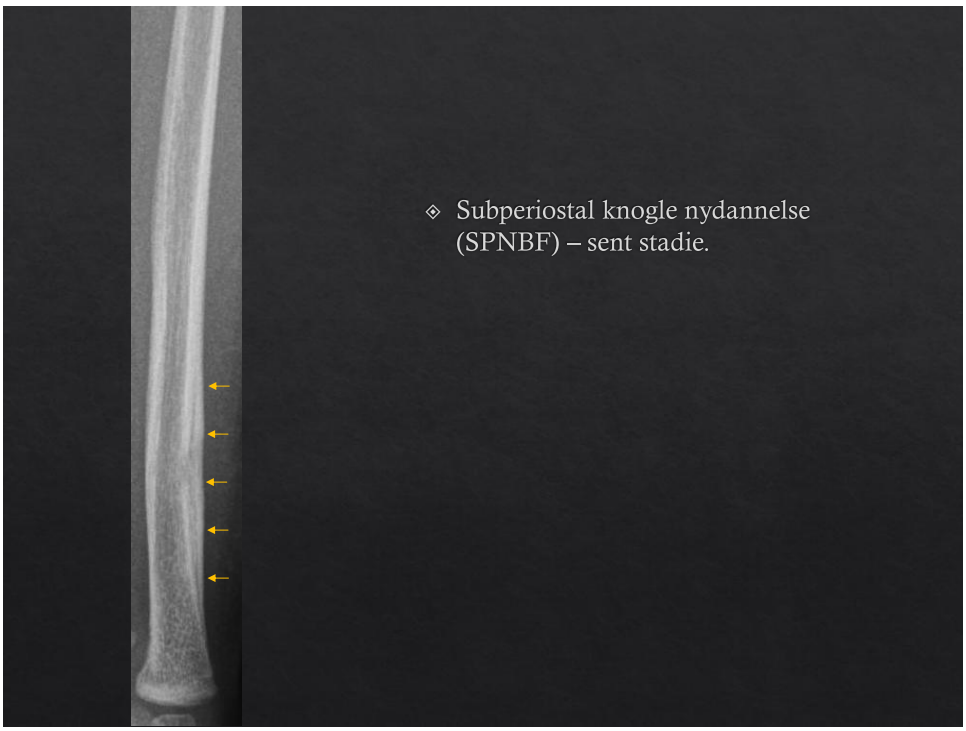
Subperiostal knogle nydannelse (SPNBF) – sent stadie.

68

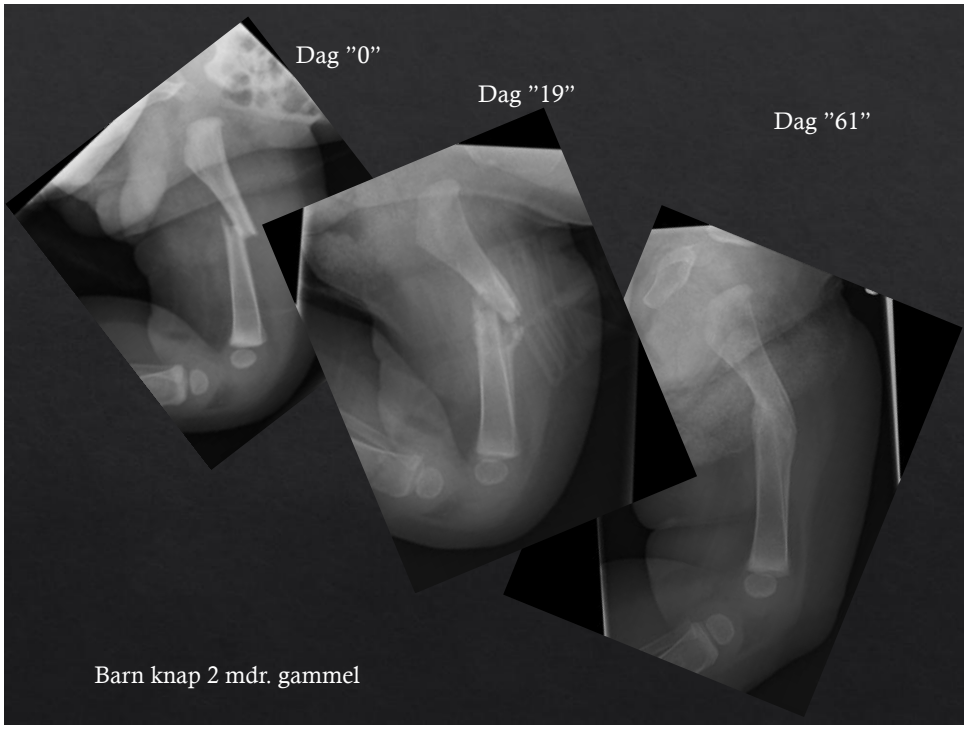

69

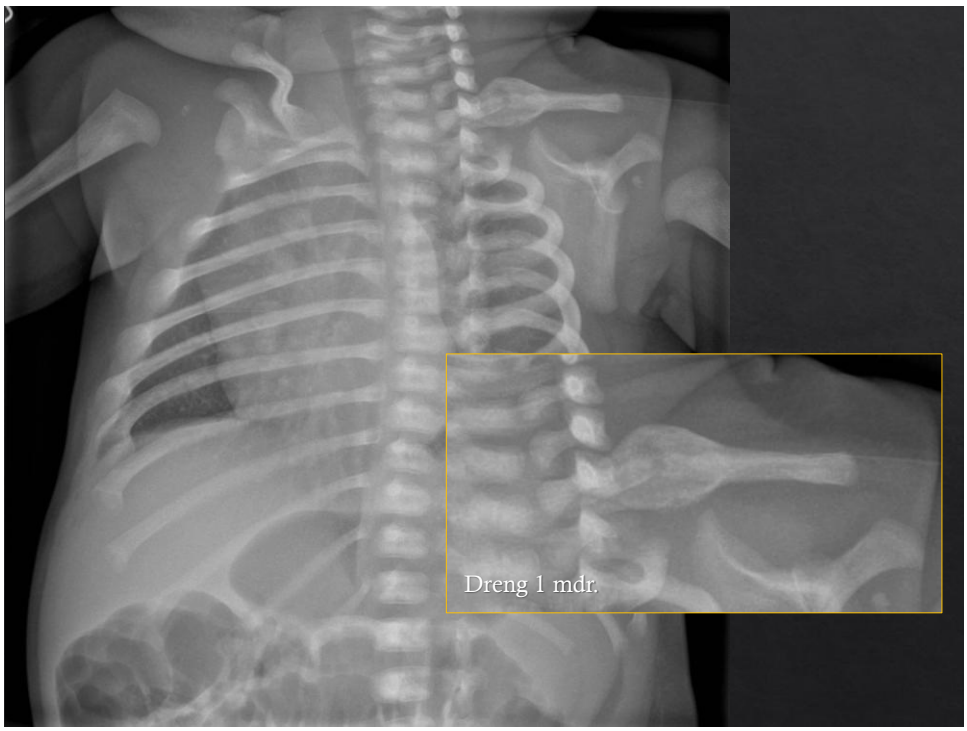

70

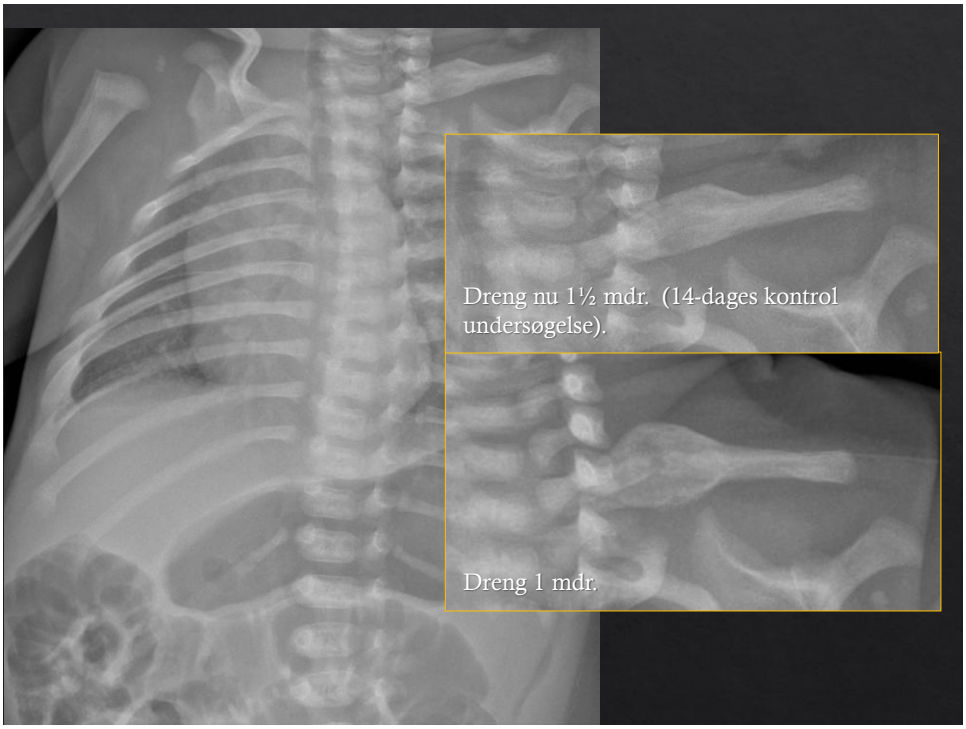

71

A Timetable for the Radiologic Features of Fracture Healing in Young Children

TABLE 3: Day That Each Feature of Fracture Healing Was First Seen, Peaked, and Was Last Seen on Digital Radiography

Feature of Fracture Healing	No. of Days Since Injury		
	First Seen[a]	Peak Period[b]	Last Seen[c]
Soft-tissue swelling	1	1–2	31
Periosteal reaction	5	15–35	96
Soft callus	12	22–35	66
Hard callus	19	≥22	96
Bridging	19	≥36	300
Remodeling	45	≥36	421

[a]The first day that reviewers agreed a feature was present.
[b]Time bands when agreed presence rose to its greatest level, exceeding 40%, before starting to decline again.
[c]Last day reviewers agreed that feature was present.

Prosser: AJR 2012; 198:1014–1020

72

A Timetable for the Radiologic Features of Fracture Healing in Young Children

- 228 billeder
- 82 frakturer
- 63 børn yngre end 5 år – gennemsnitsalder 4,8 år.

Prosser: AJR 2012; 198:1014–1020

73

"A study of radiological features of healing in long bone fractures among infants less than a year"

Table 3 Radiological features consistent with healing phases over time (days)

		Periosteal reaction	Callus	Bridging	Remodeling
Total	Range	7–130	9–130	15–130	51–247
	Peak[1]	9–49	9–26	15–67	51–247
Complete	Range	9–130	9–130	15–130	51–247
	Peak	9–49	9–36	15–67	51–247
Incomplete	Range	7–52	*	*	*
	Peak	7–28			

[1] Peak defined as present in >40% of images

*Lack of agreement in the majority of cases

Table 4 Proposed timetable for dating complete fractures based on presence of radiographic features

Proposed time table for fracture dating based on radiographic features

No healing	Periosteal reaction	Callus	Bridging	Remodeling	Fracture age
+					<9 days old
	+	+	–	–	≥9–14 days old
	±	+	+	–	≥15–51 days old
	±	±	±	+	≥51 days old

*Proposed timetable is for complete fractures, and caution should be taken using the timetable for incomplete fractures

Warner et al.: Skeletal Radiol (2017) 46:333–341, DOI 10.1007/s00256-016-2563-8

74

"A study of radiological features of healing in long bone fractures among infants less than a year"

- 59 billedserier
- 40 børn < 1 år gamle.
- Tre radiologer: Periostal reaktion, callus, brodannelse, remodellering (til stede, ikke til stede, uklart)
- "Peaked": Til stede på mere end 40% af billederne.

Warner et al.: Skeletal Radiol (2017) 46:333–341, DOI 10.1007/s00256-016-2563-8

75

Fraktur datering

"It is important to understand that radiological dating is an inexact science".

Chapman "Non-accidental Injury" in Imaging in pediatric skeletal trauma, Springer, 2008

76

Frakturer af forskellig alder

77

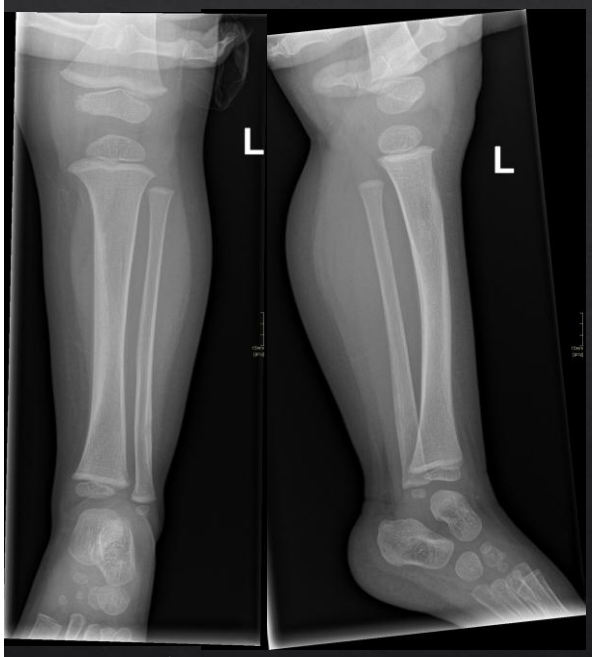

Dreng 9 mdr.

Oplyst at traumet er er sket for 11 dage siden.



78

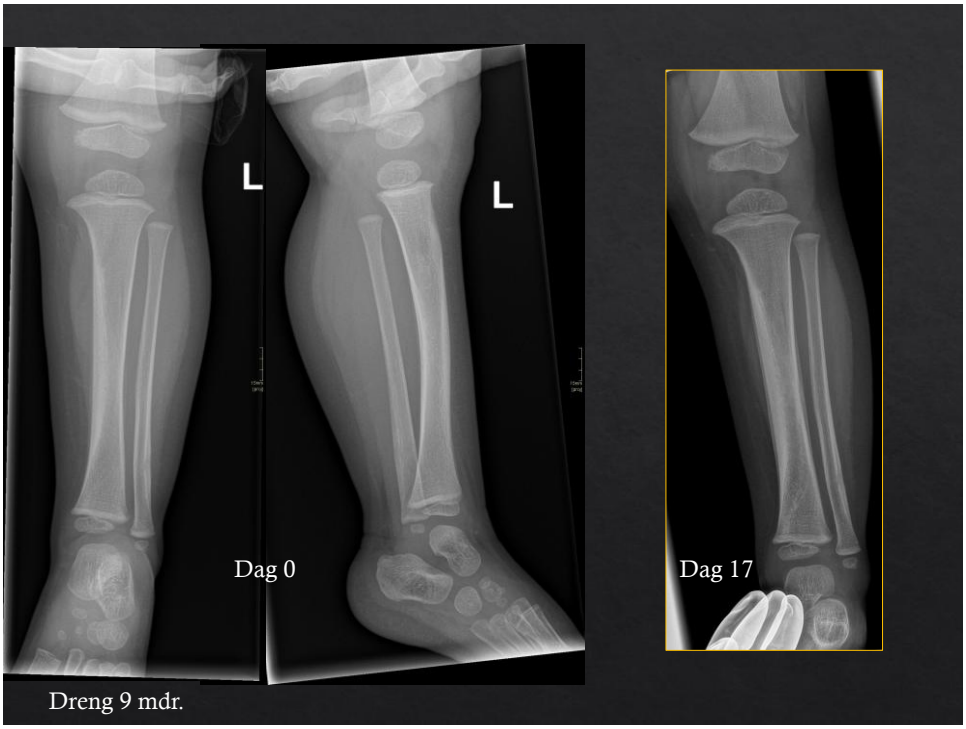

79

Differantial diagnoser

- Hændeligt uheld
- Anatomiske normal varianter
- Obstetrisk traume
- Skeletal dysplasi og syndromer
- Osteogenesis imperfectal

80

Anatomiske normal varianter

81

Højresidig tibia fraktur



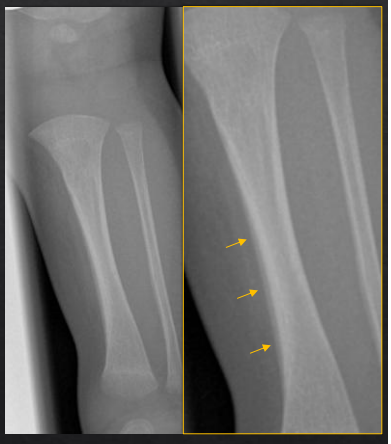

82

Fysiologisk periostitis

Fysiologisk periostitis
- Alder: 1-4 mdr. (ind imellem 6 mdr.)
- Bilateralt hos 40-70 %
- Hyppigst: Tibia > femur > humerus > ulna > radius
- < 2 mm tyk
- Diafysært

Normal fænomen ved hurtig knoglenydannelse med intramembranøs ossifikation langs periost i de lange rørknoglers diafyse.

"Pediaric Ortopedic Imaging"



Dreng to mdr. med højresidig tibiafraktur

83

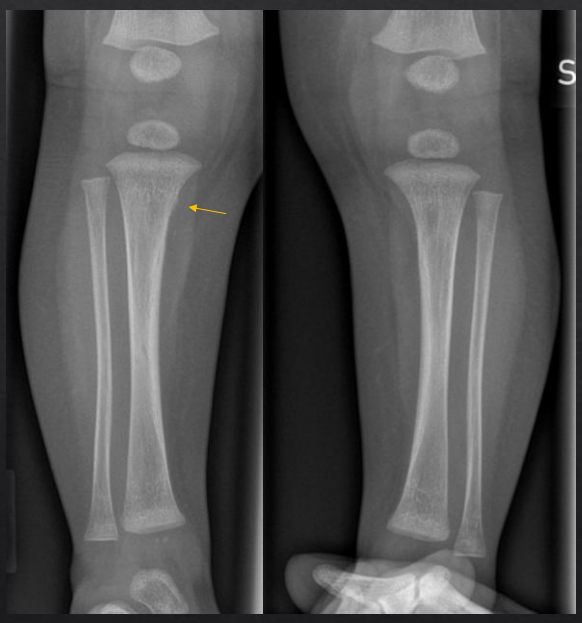



Kontrolundersøgelse efter 14 dage

Pige på 3 mdr.

84

20 dage gammel barn



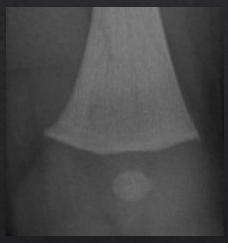

85

Sporedannelse: Normal anatomi



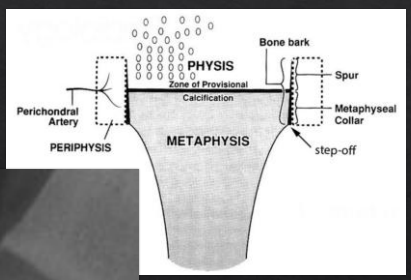



Oestreich and Caré

86

Sporedannelse: Normal anatomi



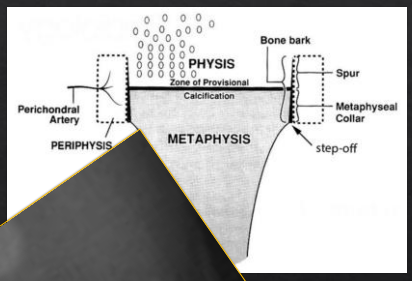



Oestreich and Caré

87

Metafysært "næb"





88

Metafysært "næb"





Kleinman et al. 1991

89



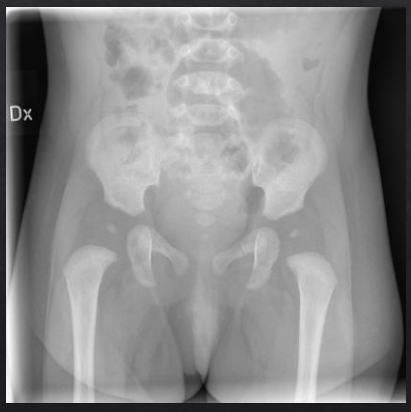

2 mdr. gammel

90

Accessorisk synchondrose i ramus superior ossis pubis





Kontrol 14 dage senere

91

Obstetriske frakturer

92

Nyfødt der ”ikke bruger armen så meget”



93

Dreng 16 dage gammel

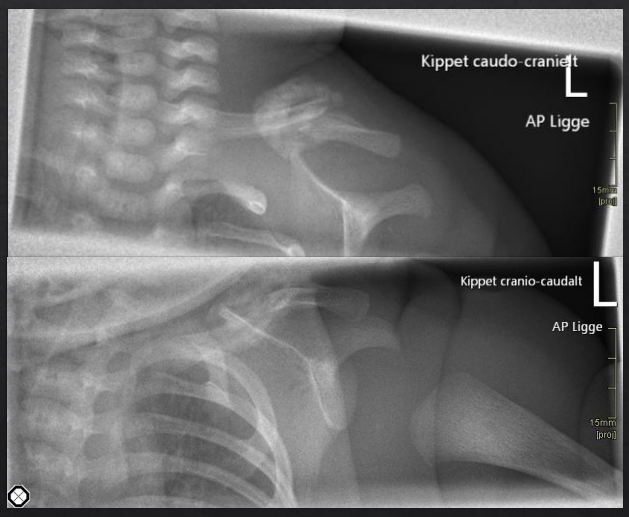

94

Dreng nu 54 dage gammel



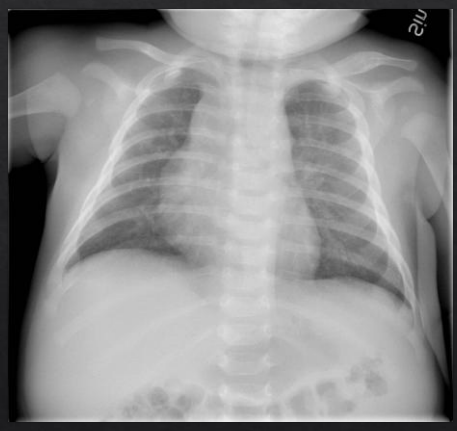

95

Dreng 54 dage gammel+14 dage



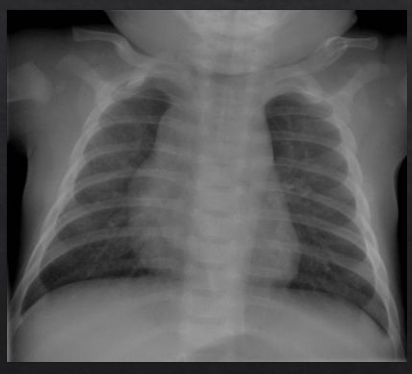

96

CML?



Currarino et al. 2000

97

CML?



Barn 5½ år



Andet barn 6 år 9 mdr.

Currarino et al. 2000

98

Skeletal dysplasi og syndromer

99

Developmental coxa vara associated with spondylometaphyseal dysplasia (DCV/SMD): "SMD-Corner Fracture Type" (DCV/SMD-CF) (Sutcliffe type)





Currarino et al. 2000

184255

100

Menkes Syndrome/Kinky Hair Disease

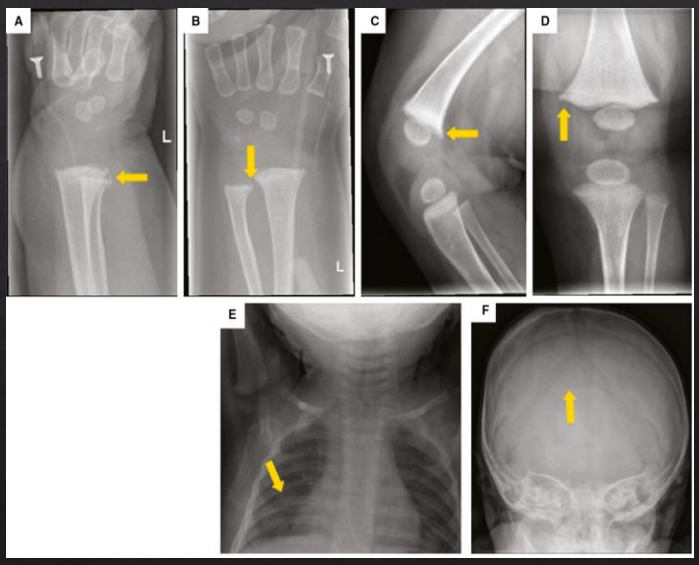

309400

Droms et al: Menkes disease mimiking child abuse. Pediatric Dermatology Vol. 34 e1132-134, 2017.

101

Litteratur

102

Litteratur

- Barber et al.:"The yield of high-detail radiographic skeletal surveys in suspected infant abuse", Pediatr Radiol (2015) 45:69–80
- Currarino et al.: "Developmental coxa vara associated with spondylometaphyseal dysplasia (DCV/SMD): "SMD-Corner Fracture Type" (DCV/SMD-CF) demonstrated in most reported cases" Pediatr Radiol (2000) 30: 14-24
- Ignasi et al.:"The yield of high-detail radiographic skeletal surveys in suspected infant abuse", Pediatr Radiol (2015) 45:69–80
- Kleinman et al.: " Normal metaphyseal radiologic variants not to be confused with findings of infant abuse", AJR (1991) 156:781-783
- Kleinman ed.: "Diagnostic Imaging of Child Abuse", 2015 Cambrigde University Press.

103

Litteratur

- Kwon et al: "Physiologic Subperiosteal New Bone Formation: Prevalence, Distribution, and Thickness in Neonates and Infants", AJR 2002;179:985–988
- Lonergan et al.:"Child abuse: Radiologic-Pathologic correlations",RadioGraphics (2003) 23:811-845
- Marine et al.: "Ultrasound findings in classic metaphyseal lesions: emphasis on the metaphyseal bone collar and zone of provisional calcification", Pediatric Radiology https://doi.org/10.1007/s00247-019-04373-w
- Oestreich et al.: "Recognizing Child Abuse in Radiology", Springer 2017
- Prosser et al."A timetable for the radiologic features of fracture healing in young children", AJR (2012); 198: 1014-1020.

104

Litteratur

- "The radiological investigation of suspected physical abuse in children" 2018 The Royal College of Radiologists
- Stein-Wexler et al.: "Pediatric Orthopedic Imaging", Springer
- Tsai et al.: "High-resolution CT with histopathological correlates of the classic metaphyseal lesion of infant abuse", Pediatr. Radiol. (2014) 44: 124-140.
- Warner et al.:" A study of radiological features of healing in long bone fractures among infants less than a year". Skeletal Radiol (2017) 46:333-341

105