PÆDIATRISK RADIOLOGI: BEVÆGEAPPARATET

Michel Bach Hellfritzsch
Overlæge
Røntgen og skanning
Aarhus Universitetshospital

1



WWW.RADIOLOGY.DK

2


Pediatric Orthopedic Imaging
Rebecca Stein-Wexler
Sandra L. Wootton-Gorges
M.B. Ozonoff
Editors
Springer
Radiographic Atlas of Skeletal Maturation
S. Lowell Kahn
Cree M. Gaskin
Victoria L. Sharp
Theodore E. Keats
Thieme
Skeletal Injury in the Child
Third Edition
John A. Ogden
Pediatric and Adolescent Musculoskeletal MRI
A Case-Based Approach
Springer
Alan E. Oestreich
Growth of the Pediatric Skeleton
A Primer for Radiologists
Springer
Theodore E. Keats
Mark W. Anderson
Atlas of NORMAL ROENTGEN VARIANTS THAT MAY SIMULATE DISEASE
Ninth Edition
BONE DYSPLASIAS
Michel Bach Hellfritzsch
3

3


AP Liggende L
H
HØ
AP STA
V
VE
GENNEMGÅ PRINCIPPER FOR DIAGNOSTIK I PÆDIATRISK MUSKULOSKELETAL RADIOLOGI
Michel Bach Hellfritzsch
4

4

EMNER

- Knoglebiologi og knoglealder
- Frakturer
- Tumorer – Normal anatomiske varianter (ellers A-kursus Ortoradiologi)
- (Infektioner A-kursus Ortoradiologi)
- (Osteochondroser A-kursus Ortoradiologi)
- (Artrit A-kursus Ortoradiologi)
- Hoftedysplasi og hofteforandringer ved cerebral parese
- Skeletal dysplasi
- Tema: Det haltende barn
- Cases undervejs – og evt. til slut
- Litteraturforslag (Bøger, artikler, Links)

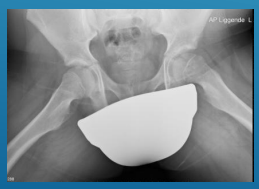



5

KNOGLEBIOLOGI

6



14.4 mm langt embryo

- S: Scapula
- H: Humerus
- R: Radius
- m: Metacarpus (tidligt chondrofications stadie)
- N: N. radialis



7

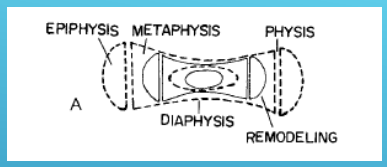

A: Dannelse af cortical knogle
B: Dannelse af trabekulær enostal knogle
C: Dannelse af marvhulen
D: Perifer metafysær cortex og remodelering
E: Dannelse af trabeculær enostal knogle

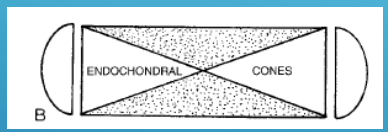

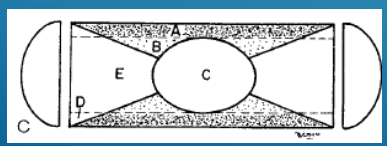



8

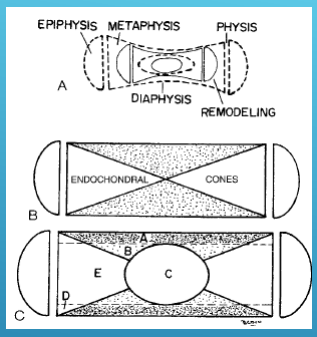

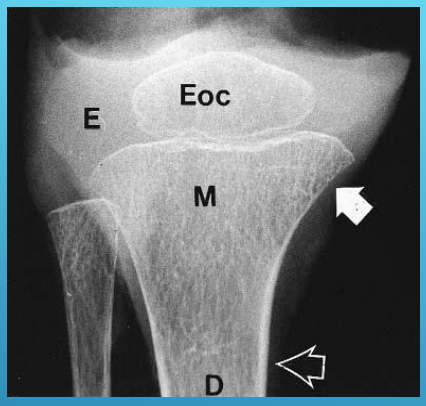



Michel Bach Hellfritzsch

9

9

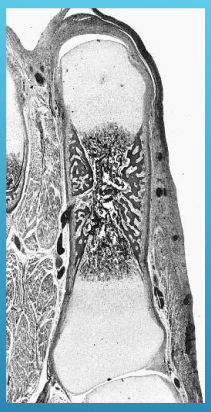



7. gestationsmåned:
Metacarpale knogler

ENCHONDRAL OG INTRAMEMBRANØS OSSIFIKATION



Michel Bach Hellfritzsch

10

10





5 DAGE GAMMEL DRENG

11

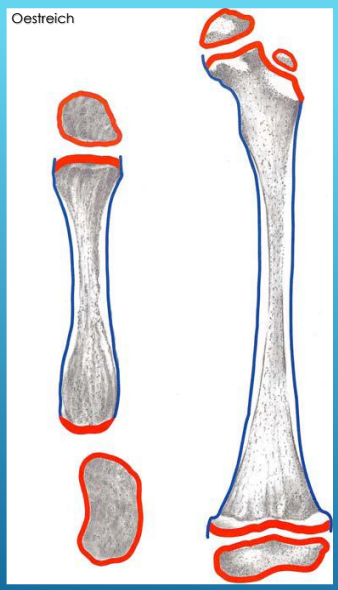

KNOGLEVÆKST

Enchondral ossifikation

Intramembranøs ossifikation



12

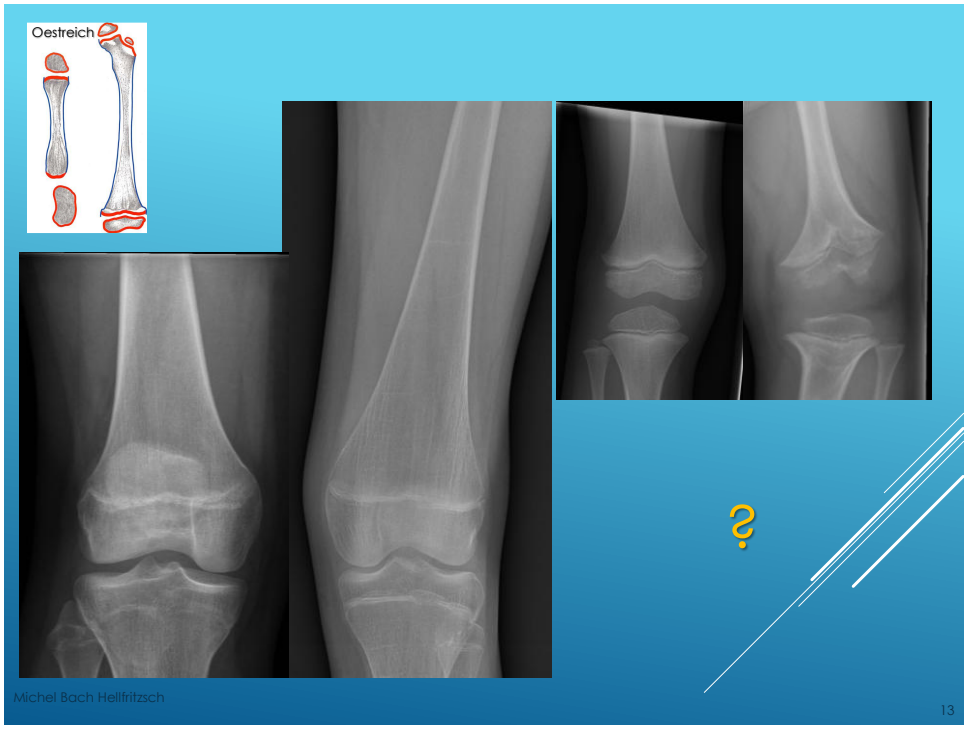
Oestreich
?
Michel Bach Hellfritzsch
13

13

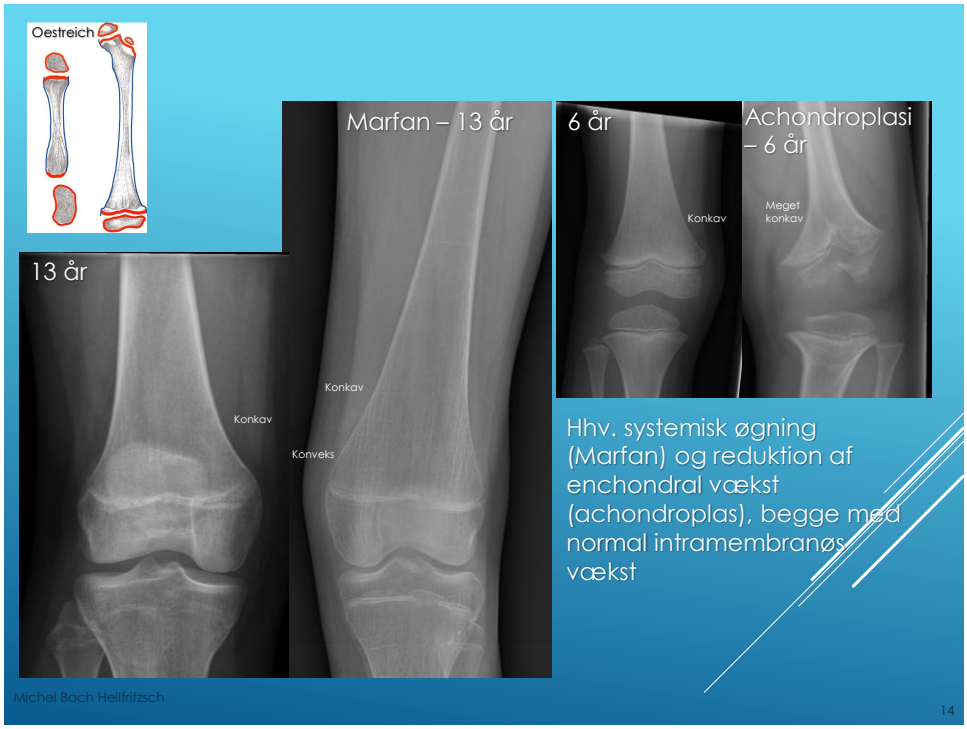
Oestreich
Marfan – 13 år
13 år
Konkav
Konkav
Konveks
6 år
Achondroplasi – 6 år
Konkav
Meget konkav
Hhv. systemisk øgning (Marfan) og reduktion af enchondral vækst (achondroplas), begge med normal intramembranøs vækst
Michel Bach Hellfritzsch
14

14





?

Michel Bach Hellfritzsch

15

15





OSTEOGENESIS IMPERFECTA
BEHANDLET MED ZOLEDRONSYRE

Michel Bach Hellfritzsch

16

16

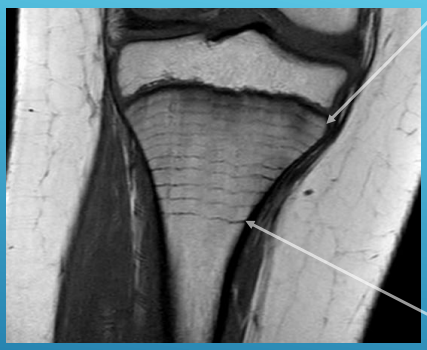

- 0 mdr. (1 mdr. før MR ses ej)
- -7 mdr.
- -14 mdr.
- -20 mdr.
- -26 mdr.
- -31 mdr.
- -38 mdr.
- -43 mdr.
- -50 mdr.
- -55 mdr.
- -62 mdr.

OSTEOGENESIS IMPERFECTA BEHANDLET MED ZOLEDRONSYRE

Michel Bach Hellfritzsch

17

17

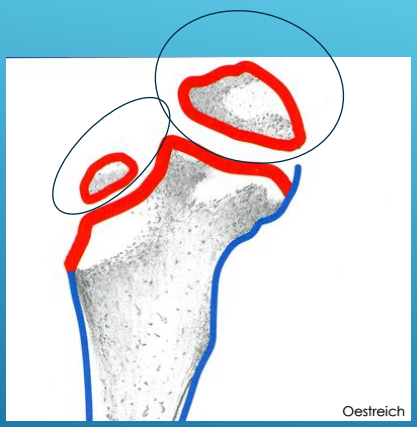

PROXIMALE FEMUR

Diafyse

Metafyse

Epifyse/Apofyse

Fyse (epifyselinien (radiologi) eller vækstskiven (anatomi))



Michel Bach Hellfritzsch

18

18



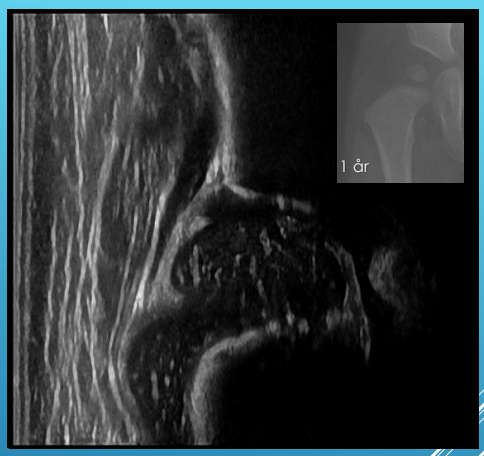

NEONATAL: UL SKANNING AF HØJRE HOFTE

Michel Bach Hellfritzsch

19

19

1. Caput femoris
2. Trochanter major
3. Metafyse (femur)
4. Diafyse (femur)
5. Acetabular loft
6. Bruskede del af acetabulum
7. Labrum
8. Os pubis (ossificeret del)

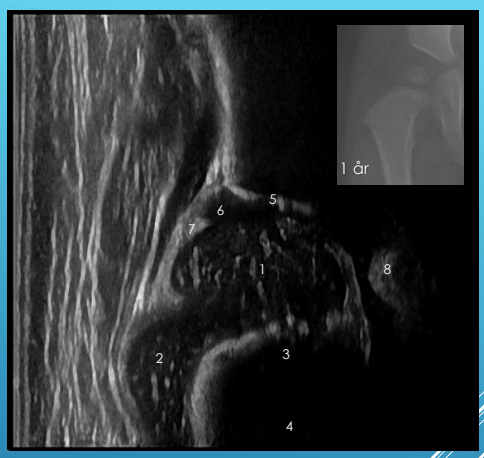

NEONATAL: UL SKANNING AF HØJRE HOFTE

Michel Bach Hellfritzsch

20

20

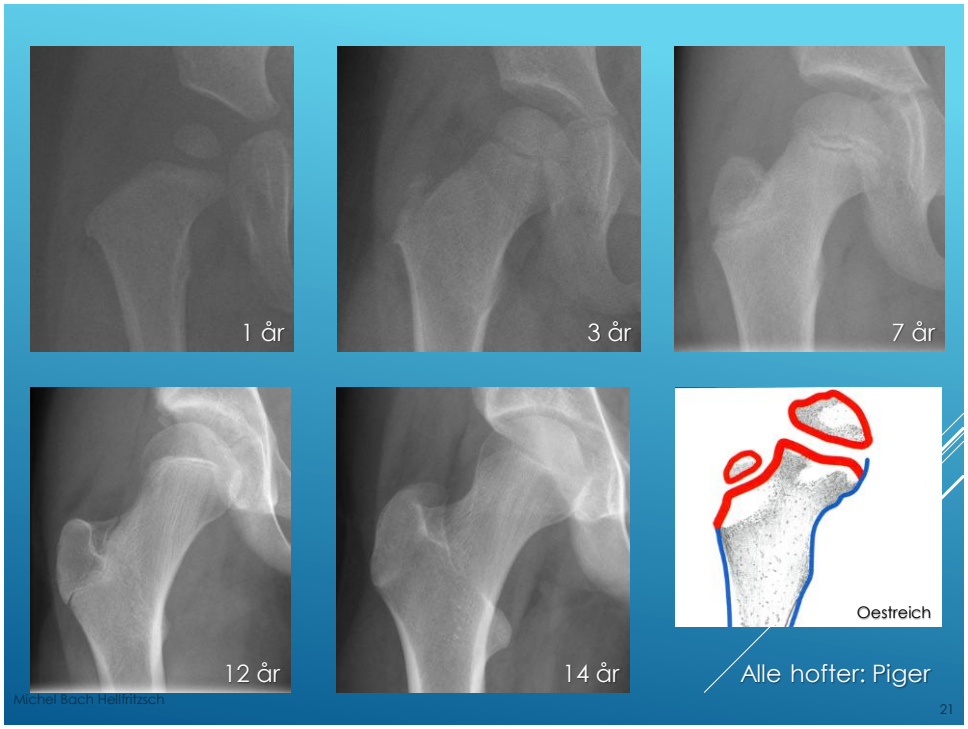
1 år
3 år
7 år
12 år
14 år
Oestreich
Alle hofter: Piger
Michel Bach Hellfritzsch
21

21


Ogden
Dreng 9 år
A
Pige 8 år
Ogden
B
FYSENS FACON I PROXIMALE FEMUR
MAKROSKOPISK OG HISTOLOGISK.
Skeletal Injury in the Child
Third Edition
John A. Ogden
Michel Bach Hellfritzsch
22

22



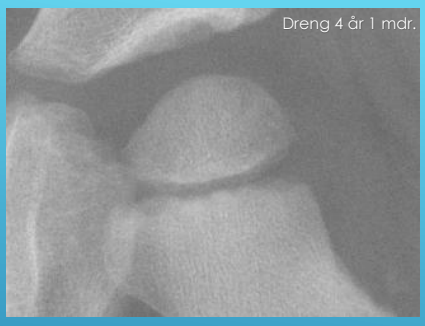



Epifyselinien og epifysekernen

Michel Bach Hellfritzsch

23

23

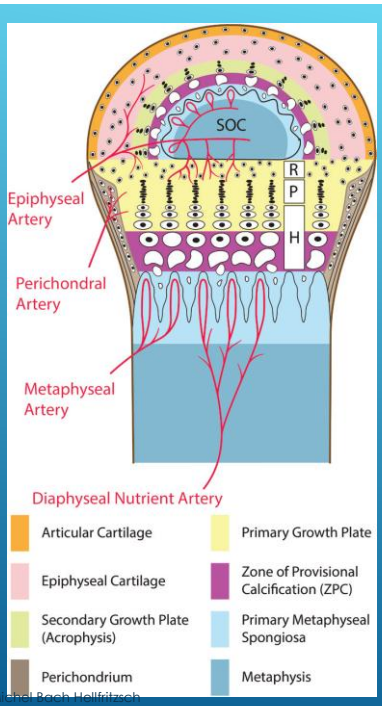

Drawing illustrates the anatomy at the end of a long bone (not drawn to scale).

NGUYEN ET AL: "IMAGING OF PEDIATRIC GROWTH PLATE DISTURBANCES", RADIOGRAPHICS 2017; 37:1791–1812

R: Reserve cells

P: Proliferative cells

H: Hypertrophic cells (undergo apoptosis near the ZPC.

Michel Bach Hellfritzsch

24

24

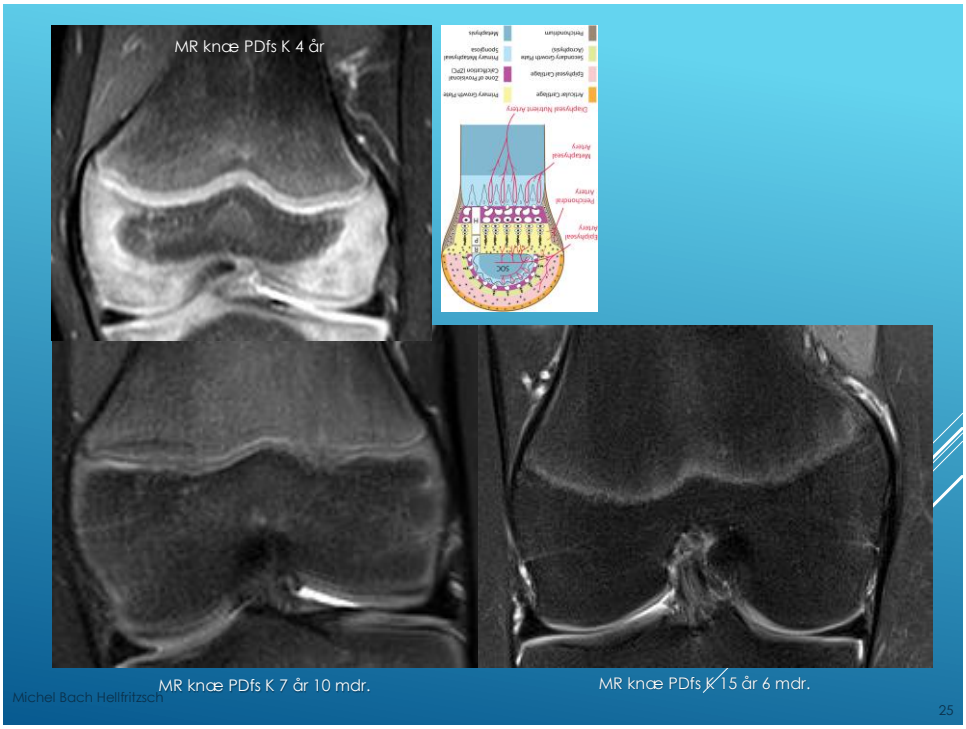
MR knæ PDfs K 4 år
MR knæ PDfs K 7 år 10 mdr.
MR knæ PDfs K 15 år 6 mdr.
Michel Bach Hellfritzsch
25

25

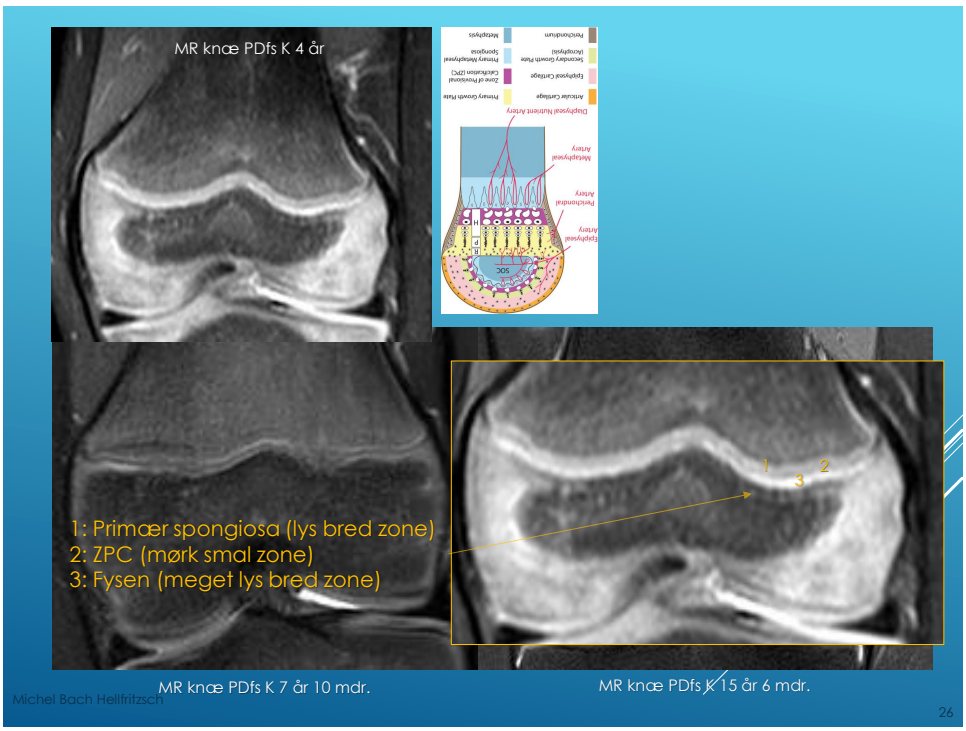
MR knæ PDfs K 4 år
1: Primær spongiosa (lys bred zone)
2: ZPC (mørk smal zone)
3: Fysen (meget lys bred zone)
1
3
2
MR knæ PDfs K 7 år 10 mdr.
MR knæ PDfs K 15 år 6 mdr.
Michel Bach Hellfritzsch
26

26

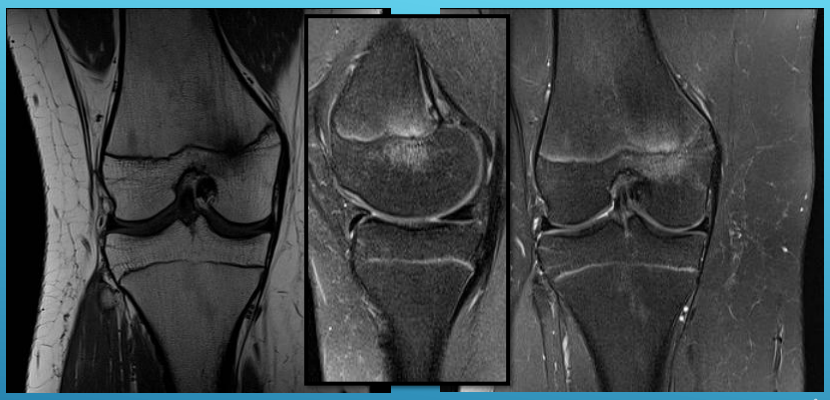

Pige godt 15 år

FOPE
(FOCAL PERIPHYSEAL EDEMA)

Michel Bach Hellfritzsch

27

27

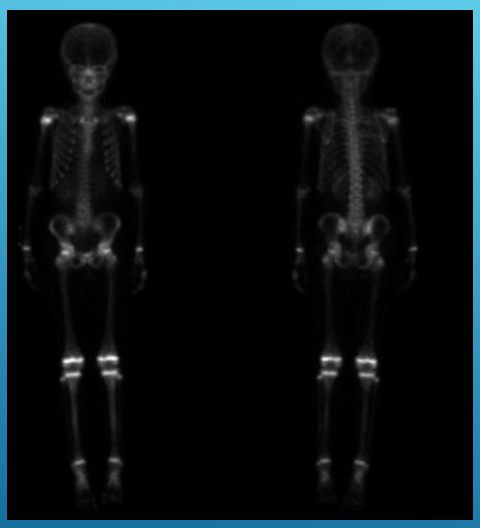

9-ÅRIG BARN: TECHNETIUM SCINTIGRAFI, NORMAL UNDERSØGELSE

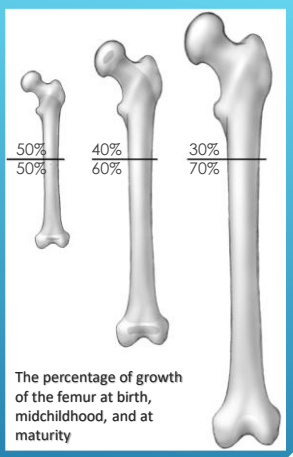

The percentage of growth of the femur at birth, midchildhood, and at maturity

Peterson 2007

Michel Bach Hellfritzsch

28

28

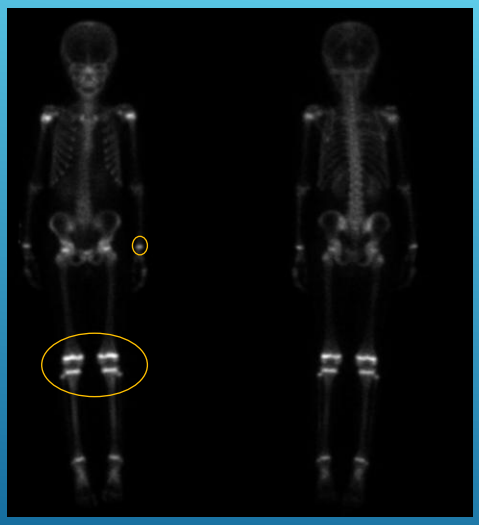



Hypofofatæmisk rakit

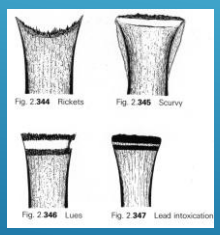

Köhler Zimmer

9-ÅRIG BARN: TECHNETIUM SCINTIGRAFI, NORMAL UNDERSØGELSE

Michel Bach Hellfritzsch

29

29

Periost

Michel Bach Hellfritzsch

30

30

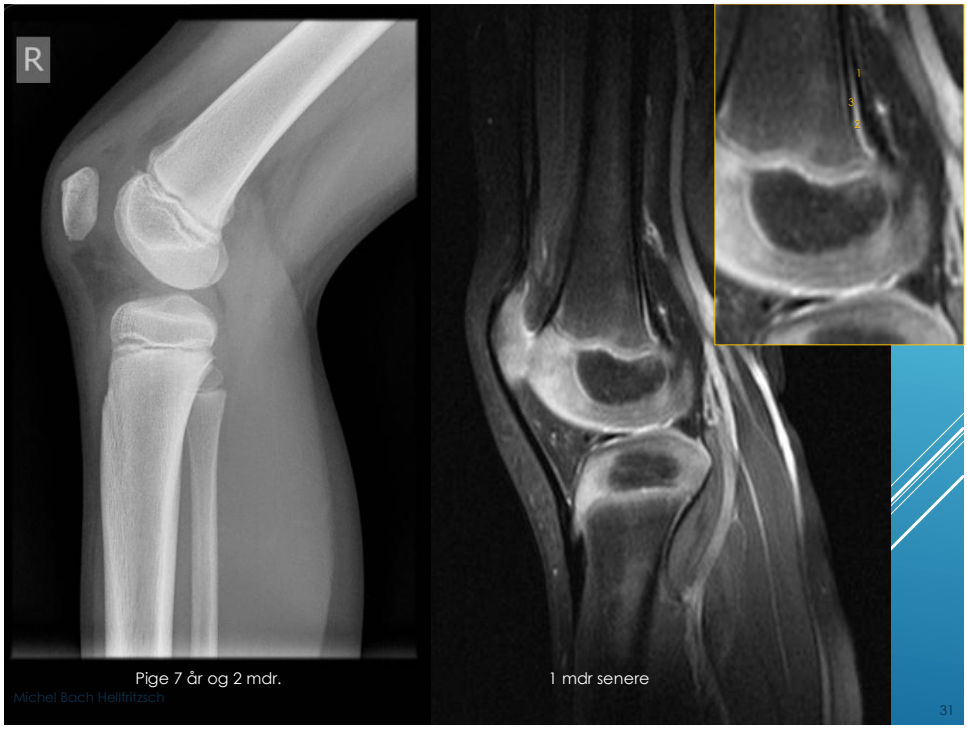
R
1
3
2
Pige 7 år og 2 mdr.
1 mdr senere
Michel Bach Hellfritzsch
31

31

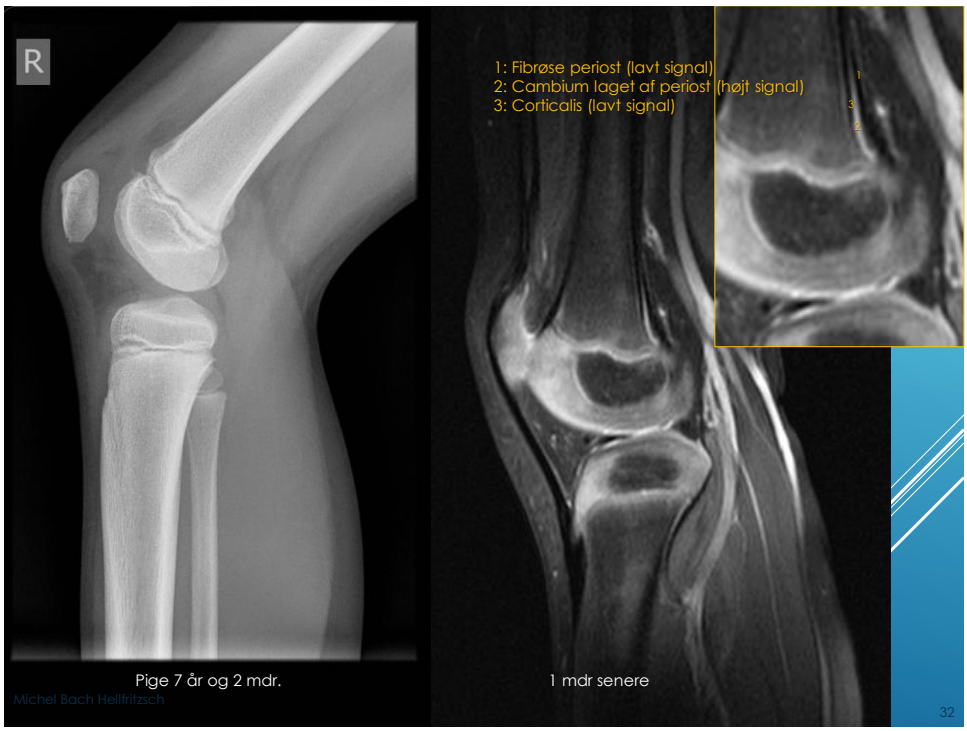
R
1: Fibrøse periost (lavt signal)
2: Cambium laget af periost (højt signal)
3: Corticalis (lavt signal)
1
3
2
Pige 7 år og 2 mdr.
1 mdr senere
Michel Bach Hellfritzsch
32

32

Knoglemarv

33



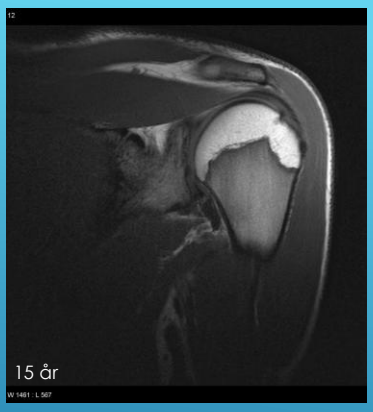

RTG. OG MR AF PROXIMALE HUMERUS.

34

Gul knoglemarv



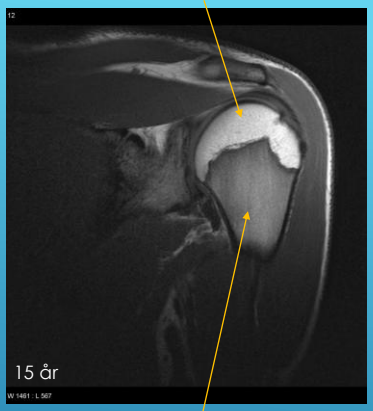

Rød knoglemarv

BEMÆRK:
DEN MEGET UREGELMÆSSIGE EPIFYSELINIE.
DET FORSKELLIGE SIGNAL FRA APIFYSEKERNEN OG METAFYSE/DIAFYSE REGIONEN

Michel Bach Hellfritzsch

35

35

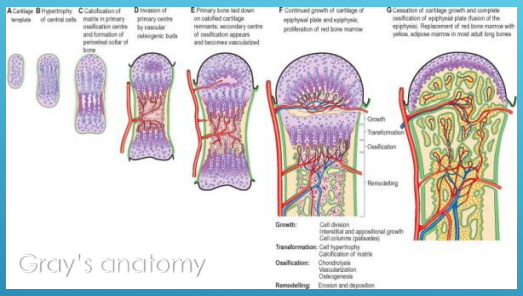

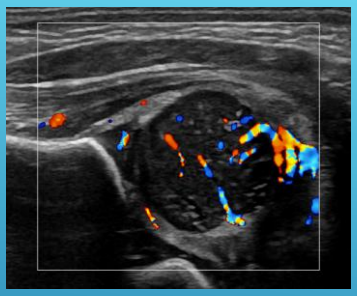

Husk: Der er kar i epifyser og apofyser, i modsætning til ledbrusk, og dette før ossifikationen starter!

KNOGLERS BLODFORSYNING

(OMTALT PÅ A-KURSUS I MSK RADIOLOGI

Michel Bach Hellfritzsch

36

36

Knoglestruktur

37

Forandringer?



2 år og 2 mdr.

38

Forandringer?



2 år og 2 mdr. | 1 år og 8 mdr. | 3 år 11 mdr.

39

Knoglestruktur



265800 | OMIM

Pyknodysostose | Osteogenesis imperfecta

40

KNOGLEALDER

41

Indikation:

- Pubertas precox (Endokrin sygdom mistænkt)
- Forudsige sluthøjde
- Bestemmelse af tidspunkt for kirurgi:
  - Skoliosekirurgi
  - Kirurgi ved anisomeli (LLD)
  - Valgus/varus korrektion i underekstremiteter
- M. fl.

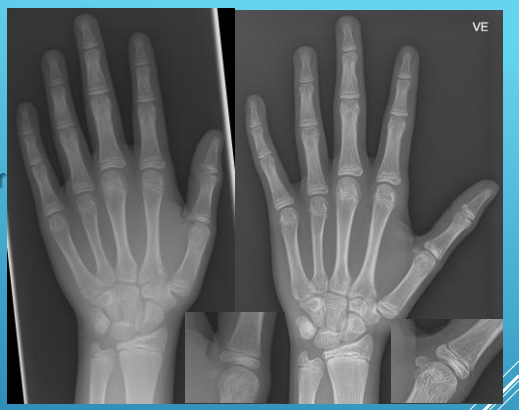

Samme barn hhv. 12 år 4 mdr. og 15 år 1 mdr.

KNOGLEALDERBESTEMMELSE

42

KNOGLEALDERBESTEMMELSE

- Forskellige metoder
- Hånden:
  - Tanner-Whitehouse 3
  - Greulich-Pyle
  - BoneXpert (automatisk metode)
- Risser (Crista apofysen)
- Sauvegrain (Albuen)
- M. fl.

- Udover selve aldersbestemmelsen, bør de enkelte knogler også vurderes

43



Knoglealderbestemmelse med software programmet BoneXpert

44



- Case

4-ÅRIG PIGE, HØJRE HÅND

45





VENSTRE HÅND TIL SAMMENLIGNING

46


Dx
Sin
ACCELERERET KNOGLEALDER
MODER DEBUTEREDE MED JUVENIL IDIOPATISK ARTRIT I SAMME ALDER. PÅ UL SYNOVIT I HØJRE HÅND.
Michel Bach Hellfritzsch
47

47

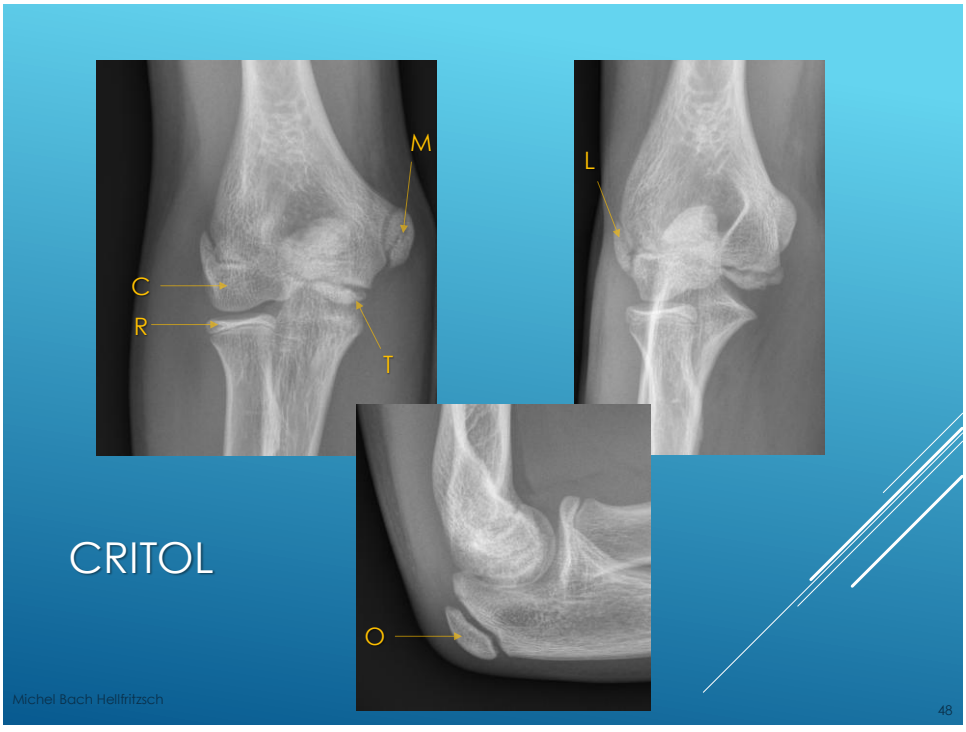
M
C
R
T
L
O
CRITOL
Michel Bach Hellfritzsch
48

48







CRITOL
C: Capitulum humeri
R: Radial head
I: Internal epicondyle
T: Trochlea humeri
O: Olecarnon
L: Lateral epicondyle





Drenge i forskellig alder

ANLÆGGELSE AF EPI- OG APOFYSER I ALBUEN HOS BØRN.

Michel Bach Hellfritzsch

49

49

	Piger		Drenge	
	Ossifikation	Fusion	Ossifikation	Fusion
Capitulum humeri	0.33–1	9.4–15	0.08–1	12.4–17.5
Caput radii	1.6–6.8	10.2–15	2.9–8.5	12.4–17.1
Mediale epicondyl	1.3–7.1	11.5–15.3	3.5–9.7	13–16.8
Trochlea humeri	5.7–11.1	9.2–13	7–12.5	11.6–15.2
Olecranon	6–11	10.8–14.8	7.6–12.2	12.4–16.5
Laterale epicondyl	7.3–11.6	9.5–13.3	8–14.4	12.1–15.9

PEDIATRIC ORTHOPEDIC IMAGING SPRINGER 2015

Michel Bach Hellfritzsch

50

50

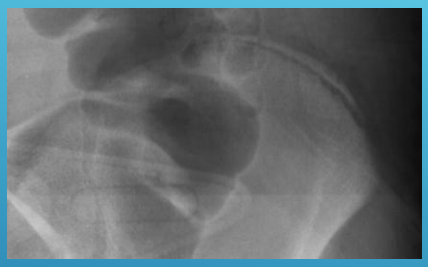

- Ringapofyserne på vertebra lukker på (cirka) samme tid som crista apofysen
- Stadium 5:
  - Kvinder 18,1 år
  - Mænd 18,6 år

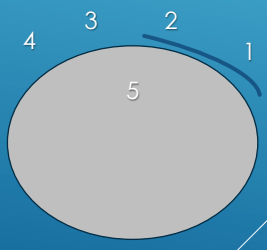

RISSER STADIER 0-5

Apofysen ossificerer lateralt fra og fusionerer medialt fra.

Michel Bach Hellfritzsch

51

51

- Radiographic Atlas of Skeletal Maturation – Kahn et al., Thieme 2012
- https://www.orthorad.de/index.php/orthorad/pedbone
- App Pedbone
- BoneXpert software

LITTERATUR OG LINKS

Michel Bach Hellfritzsch

52

52

FRAKTURER

Michel Bach Hellfritzsch

53

53

- Henvisning:
  - Anamnese
  - Objektive fund
  - Klinisk diagnose
- Beskrivelse:
  - Er undersøgelse teknisk OK
  - Selve beskrivelsen

- Frakturtyper
- Frakturheling
- Specifikke pædiatriske frakturer
- Frakturfølger og komplikationer

FRAKTURER

Michel Bach Hellfritzsch

54

54


?
2½-ÅRIG DRENG, VIL IKKE STØTTE PÅ HØJRE FOD, KLINISK MISTANKE OM METATARS FRAKTUR
Michel Bach Hellfritzsch
55

55

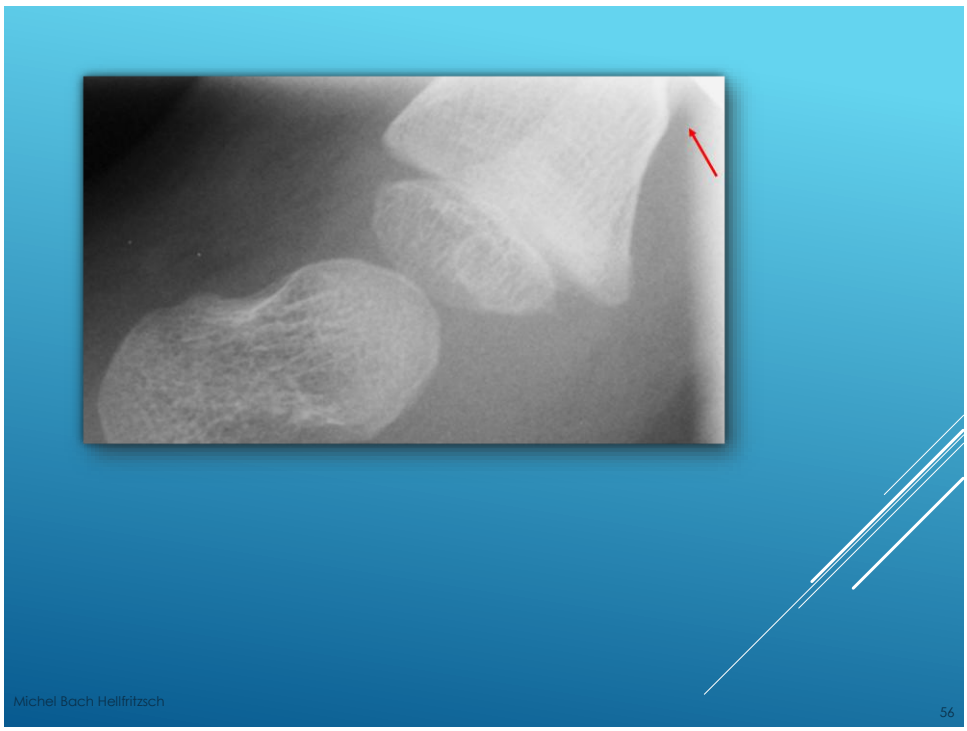
Michel Bach Hellfritzsch
56

56





ANAMNESE OG KLINISKE OPLYSNINGER ER VIGTIGE - MEN "KLINIK" KAN VÆRE SVÆRT HOS BØRN

Michel Bach Hellfritzsch

57

57



?



PIGE 1 ÅR 11 MDR, OBS. ANTEBRACHIUM FRAKTUR

Michel Bach Hellfritzsch

58

58



Albuen kun undesøgt i et plan: Insufficient undersøgelse.



PIGE 1 ÅR 11 MDR, OBS. ANTEBRACHIUM FRAKTUR

Michel Bach Hellfritzsch

59

59

Infraktioner

Michel Bach Hellfritzsch

60

60



4-ÅRIG PIGE

61

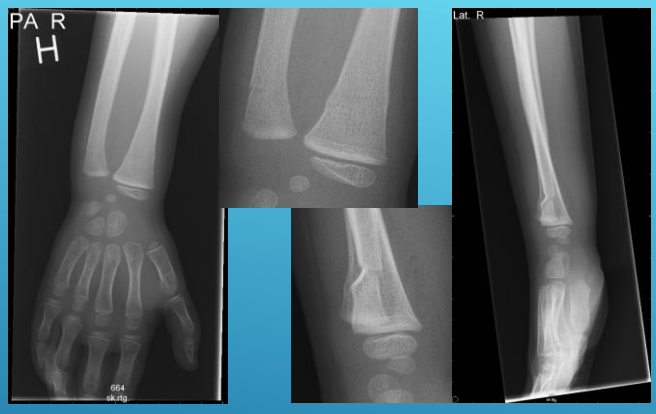

4-ÅRIG PIGE:
TORUS (BUCKLE) FRAKTUR



62

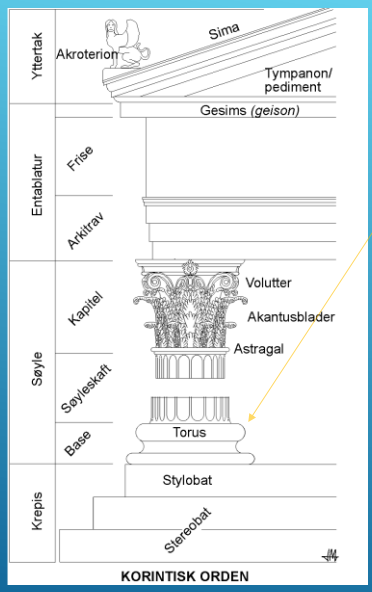

TORUS

https://upload.wikimedia.org/wikipedia/commons/0/0c/Soyleorden_korintisk.png

63







4-ÅRIG DRENG: "GREENSTICK FRAKTUR"



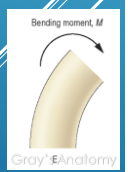

64

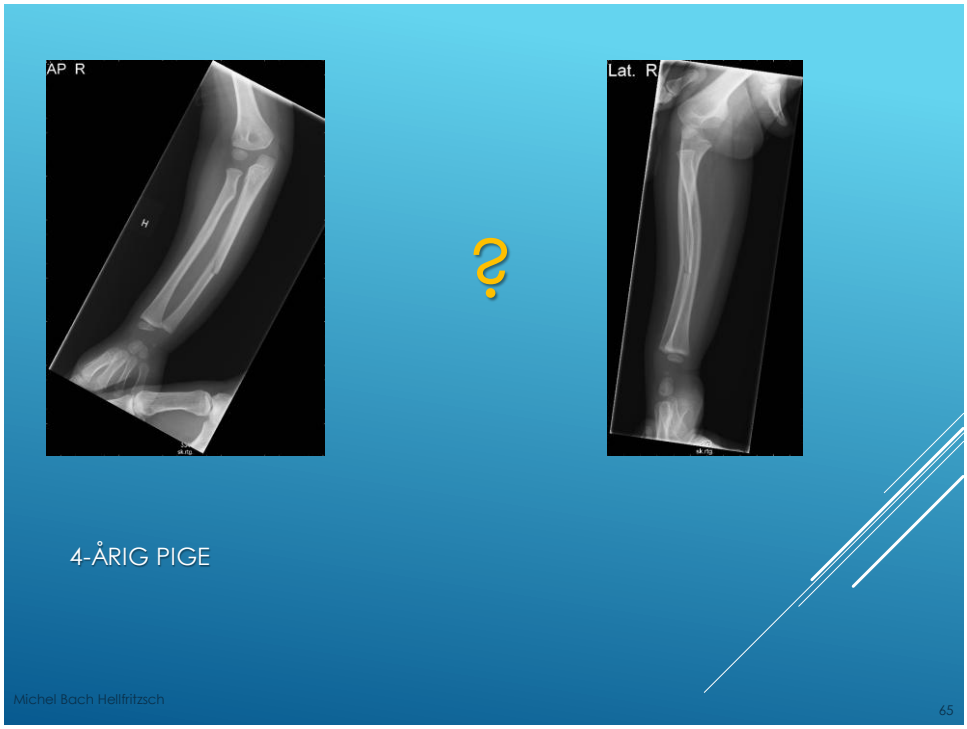
AP R
Lat. R
?
4-ÅRIG PIGE
Michel Bach Hellfritzsch
65

65

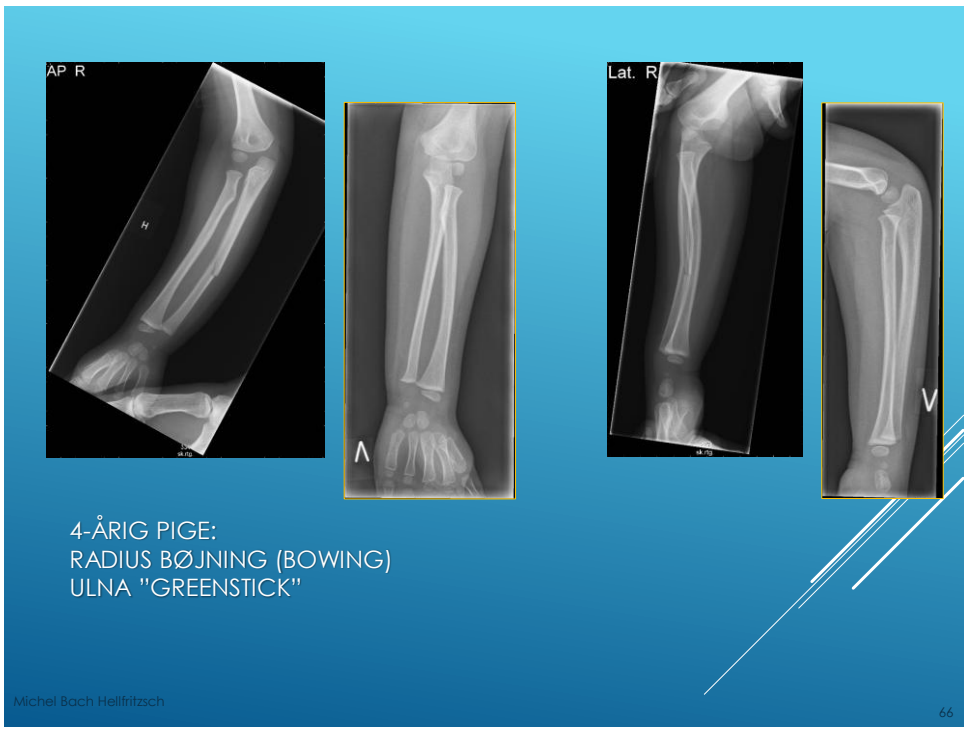
AP R
Lat. R
4-ÅRIG PIGE:
RADIUS BØJNING (BOWING)
ULNA "GREENSTICK"
Michel Bach Hellfritzsch
66

66

Salter-Harris

67

- Diafyse
- Metafyse
- Fyse (Vækstskive)
- Epifyse
- (Apofyser)

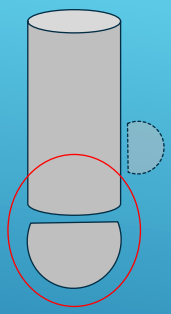

FYSÆRE FRAKTURER (VÆKSTSKIVE LÆSIONER)

68

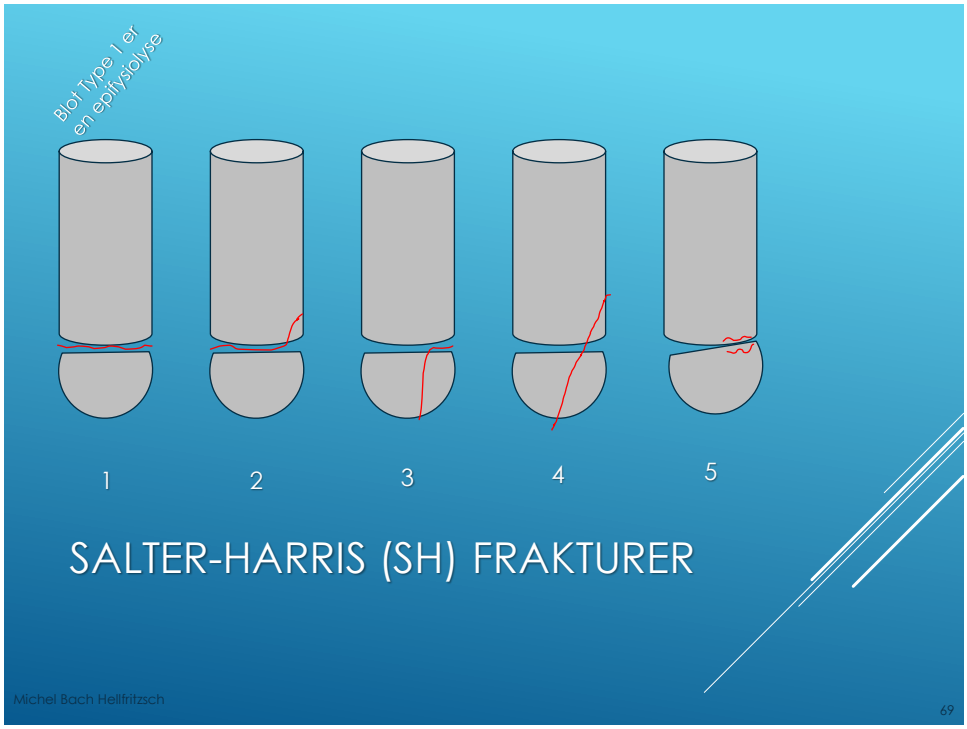
Blot Type 1 er
en epifysiolyse
1
2
3
4
5
SALTER-HARRIS (SH) FRAKTURER
Michel Bach Hellfritzsch
69

69

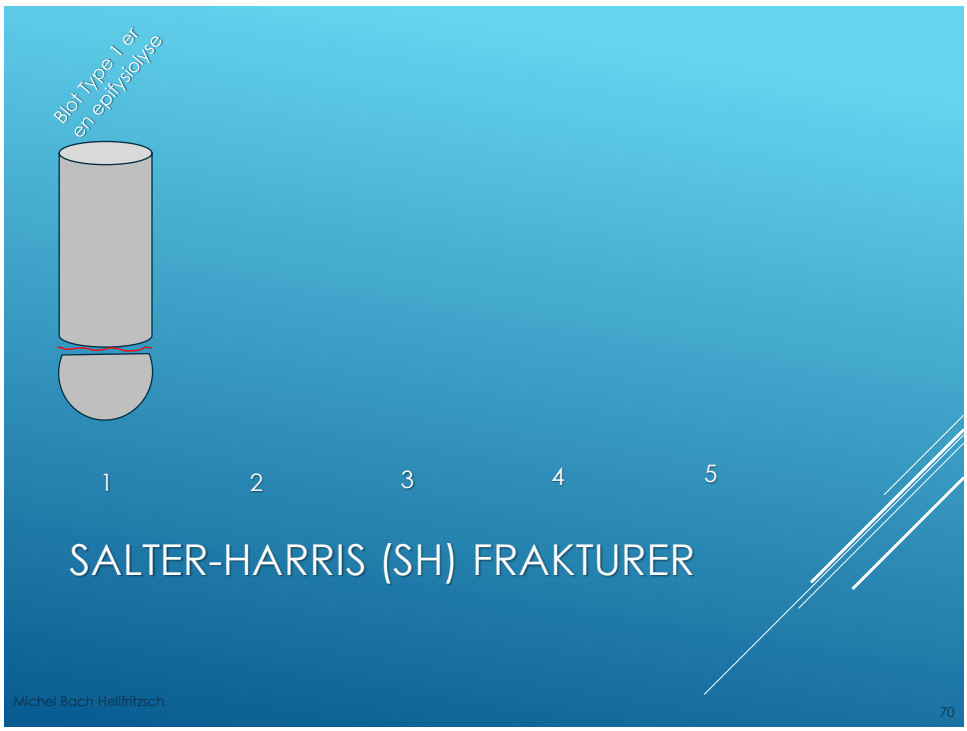
Blot Type 1 er
en epifysiolyse
1
2
3
4
5
SALTER-HARRIS (SH) FRAKTURER
Michel Bach Hellfritzsch
70

70

NYFØDT DER IKKE VIL BRUGE ARMEN



?

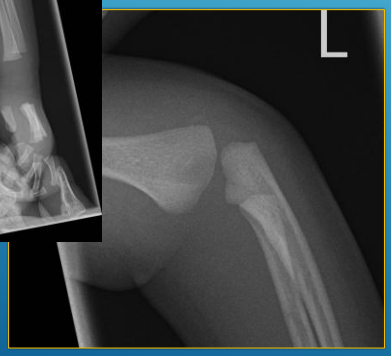

Dag 5

Michel Bach Hellfritzsch

71

71

OBSTETRISK FRAKTUR: DISTALE HUMERUS



SH-1 fraktur (her med et lille metafysært fragment)

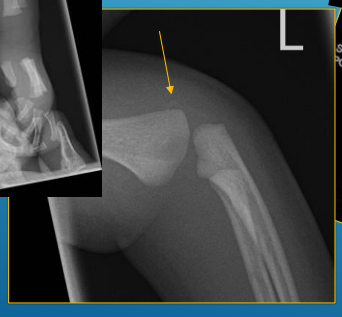

Dag 5

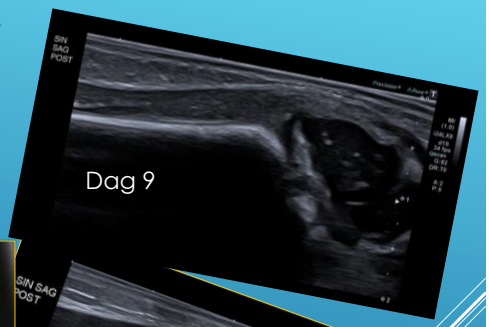

Dag 9



Andet barn
Dag 21

Michel Bach Hellfritzsch

72

72

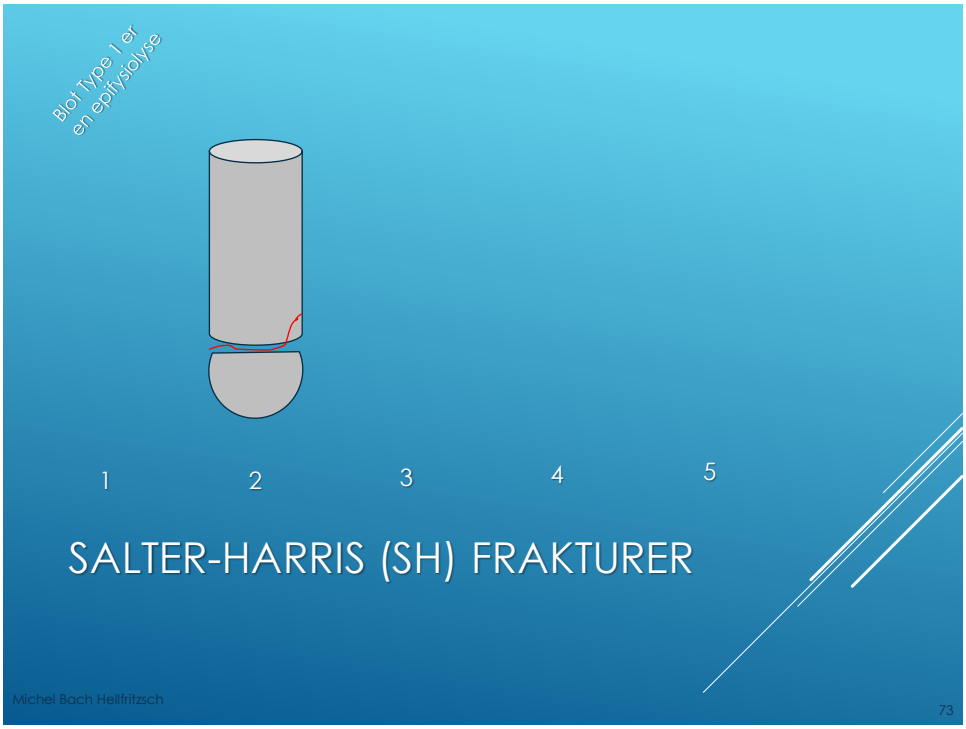
Blot Type 1 er en epifysiolyse
1
2
3
4
5
SALTER-HARRIS (SH) FRAKTURER
Michel Bach Hellfritzsch
73

73

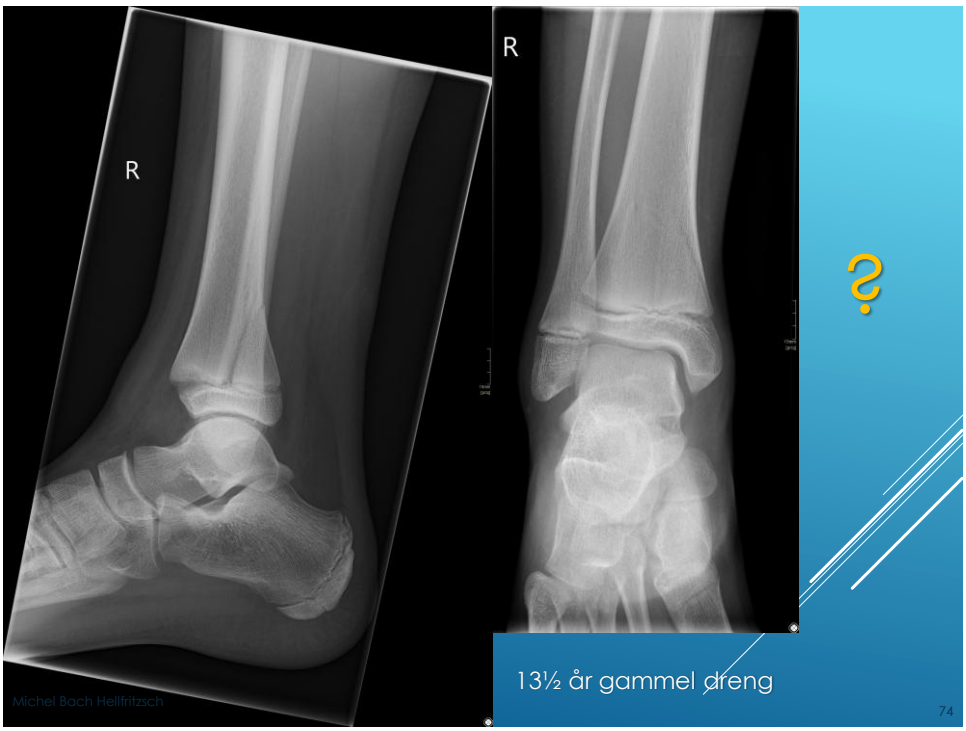
R
R
?
13½ år gammel dreng
Michel Bach Hellfritzsch
74

74

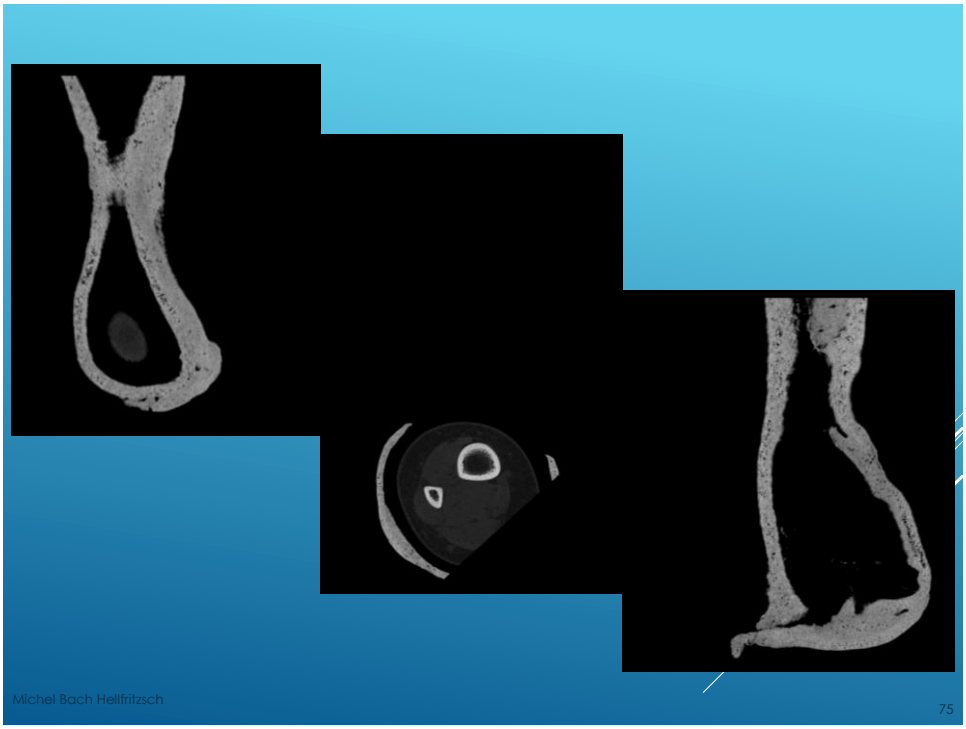
Michel Bach Hellfritzsch
75

75

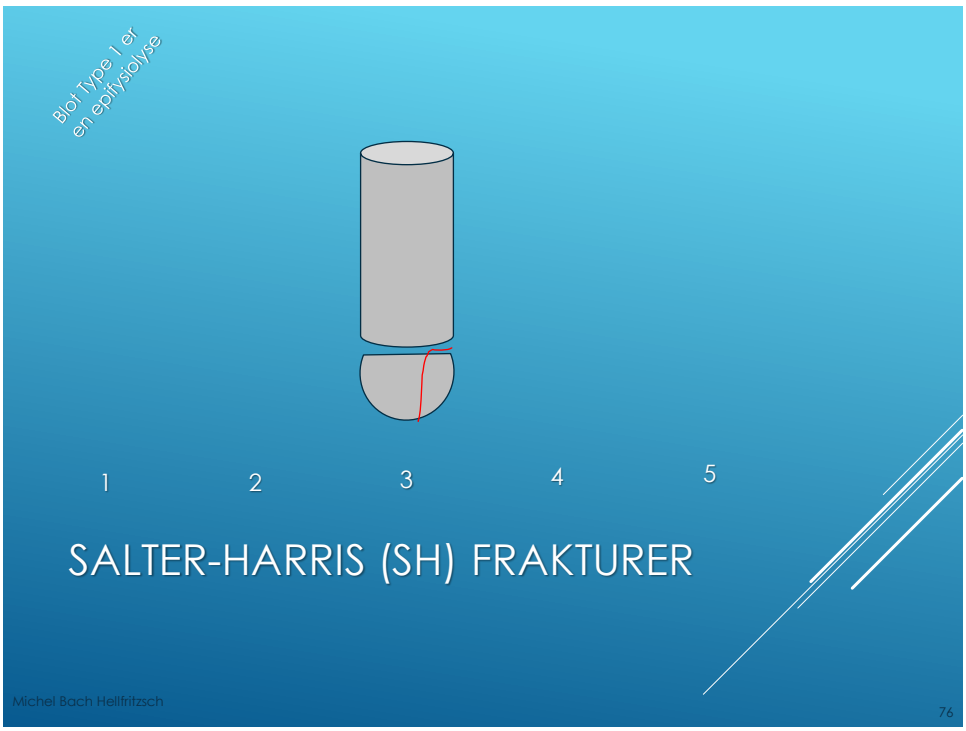
Blot Type 1 er
en epifysiolyse
1
2
3
4
5
SALTER-HARRIS (SH) FRAKTURER
Michel Bach Hellfritzsch
76

76

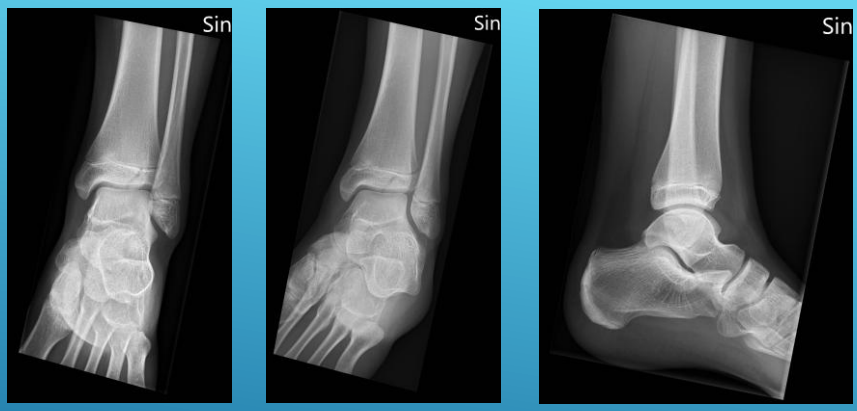

S-H TYPE 3 (TILLAUX FRAKTUR)
13-ÅRIG PIGE

Michel Bach Hellfritzsch

77

77

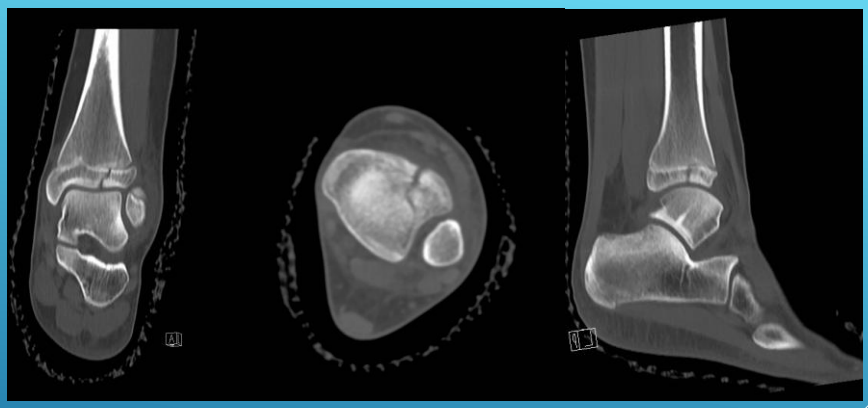

TILLAUX FRAKTUR (S-H TYPE 3)
(13-ÅRIG PIGE)

Michel Bach Hellfritzsch

78

78

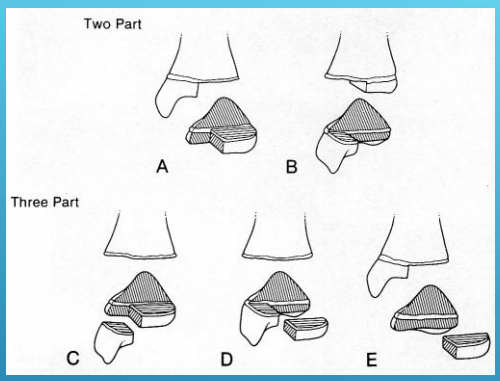

Lee F. Roger

TRIPLANE FRACTURES (KOMPLEKS SKADE)

Michel Bach Hellfritzsch

79

79

Biol Type 1 er en epifysiolyse

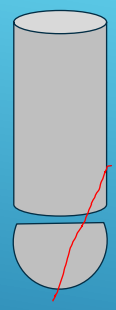

1 2 3 4 5

SALTER-HARRIS (SH) FRAKTURER

Michel Bach Hellfritzsch

80

80

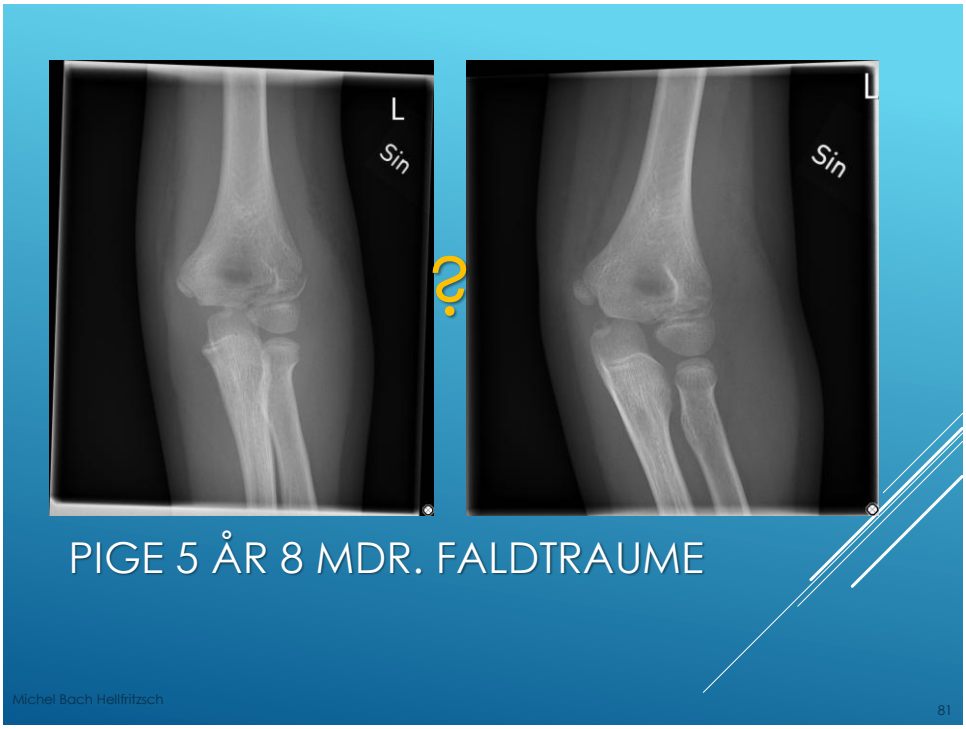
L
Sin
?
L
Sin
PIGE 5 ÅR 8 MDR. FALDTRAUME
Michel Bach Hellfritzsch
81

81

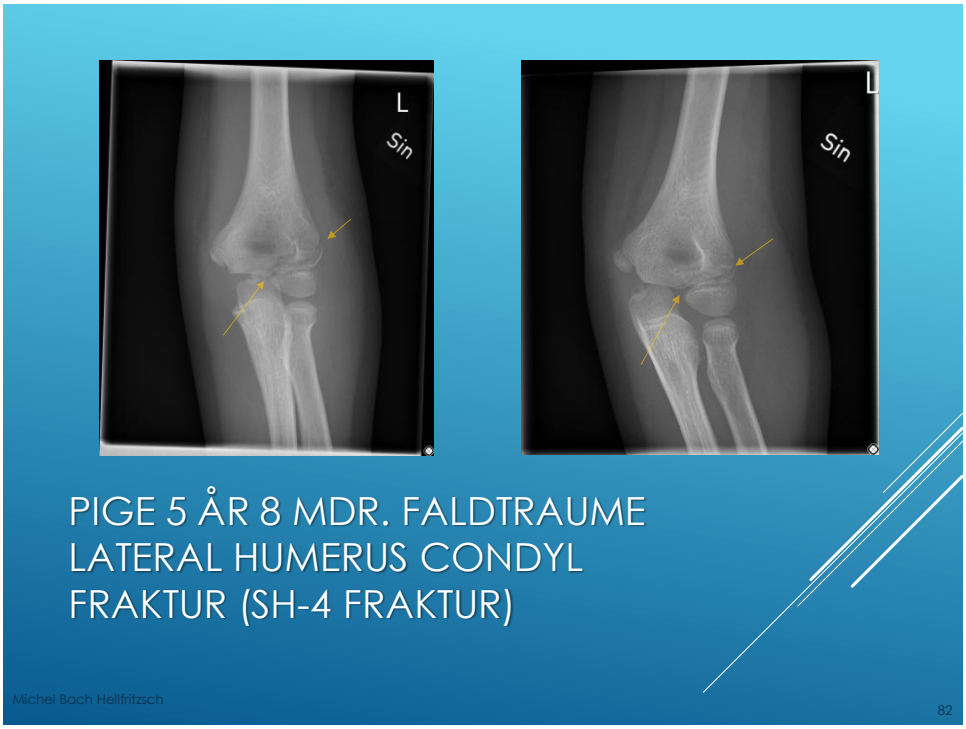
L
Sin
L
Sin
PIGE 5 ÅR 8 MDR. FALDTRAUME
LATERAL HUMERUS CONDYL
FRAKTUR (SH-4 FRAKTUR)
Michel Bach Hellfritzsch
82

82

Blot Type 1 er en epifysiolyse



1 2 3 4 5

SALTER-HARRIS (SH) FRAKTURER

Michel Bach Hellfritzsch

83

83

Patologisk fraktur

Michel Bach Hellfritzsch

84

84





PATOLOGISK FRAKTUR

85





PATOLOGISK FRAKTUR: POST-OP OPTRANSPLANTATION

86

Fraktur efter lokalisation eller alder

87





15 MDR GAMMELT BARN: VIL PLUDSELIG IKKE STØTTE

88



- 1-3 års alderen
- Falder på fikseret ben, hvilket giver rotation i tibia, således der kommer en spiral fraktur
- Kan hvis udisloceret være vanskelig at se på primære undersøgelse
- Ved vedvarende symptomer nyt røntgen efter 10-14 dage.

15 MDR GAMMELT BARN: "TODDLERS FRACTURE"



Michel Bach Hellfritzsch

89

89





PIGE KNAP 5 ÅR. FALDTRAUME

Michel Bach Hellfritzsch

90

90

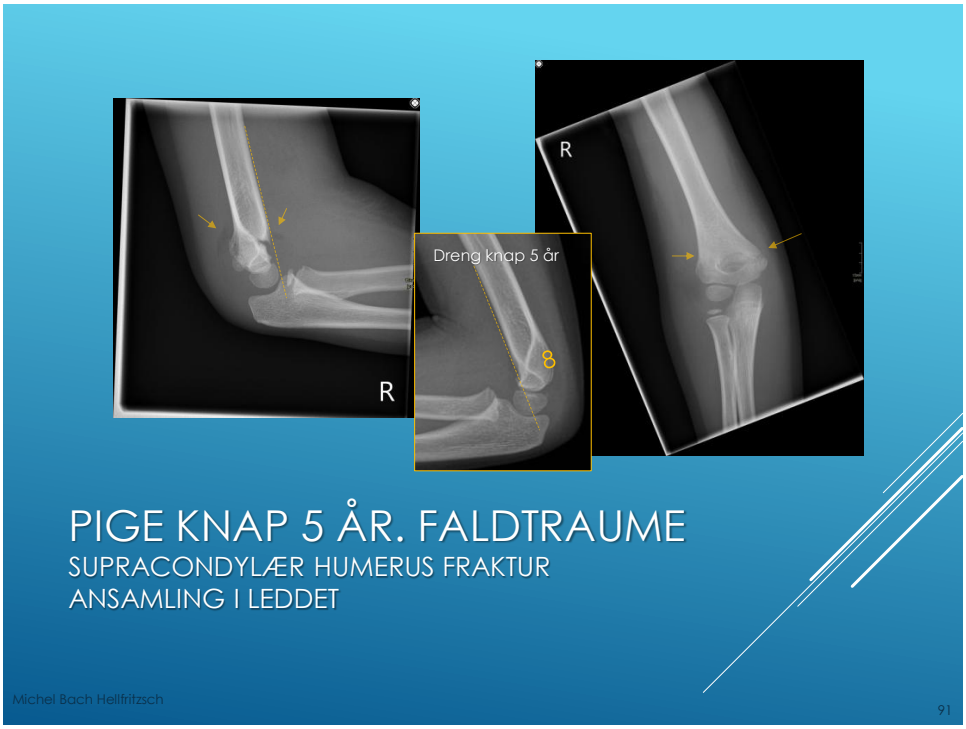
R
Dreng knap 5 år
R
PIGE KNAP 5 ÅR. FALDTRAUME
SUPRACONDYLÆR HUMERUS FRAKTUR
ANSAMLING I LEDDET
Michel Bach Hellfritzsch
91

91

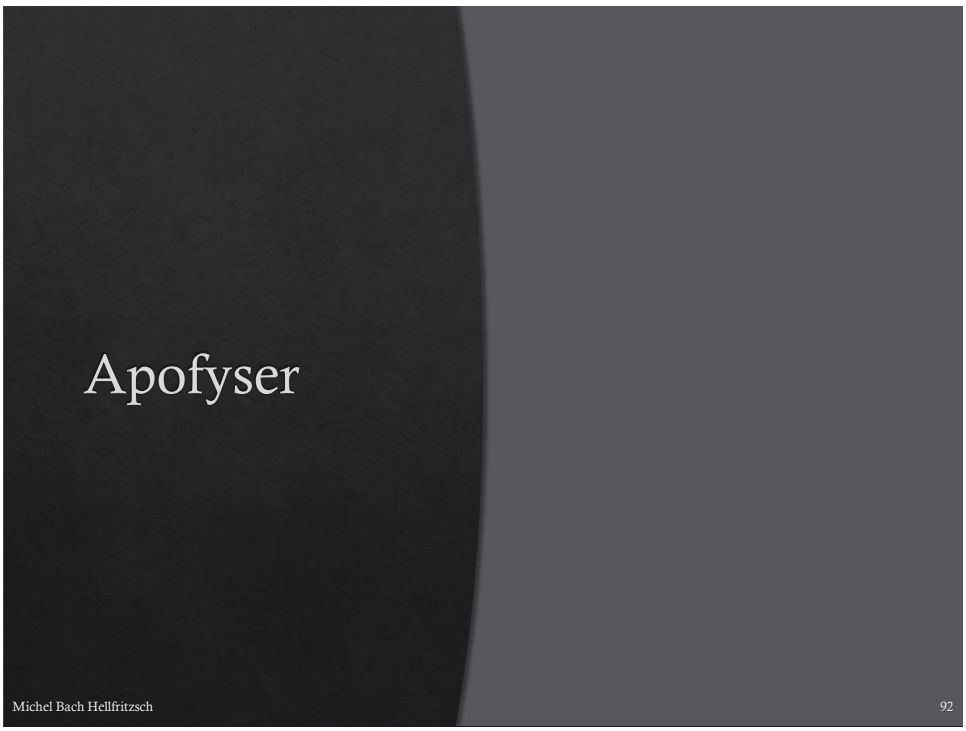
Apofyser
Michel Bach Hellfritzsch
92

92

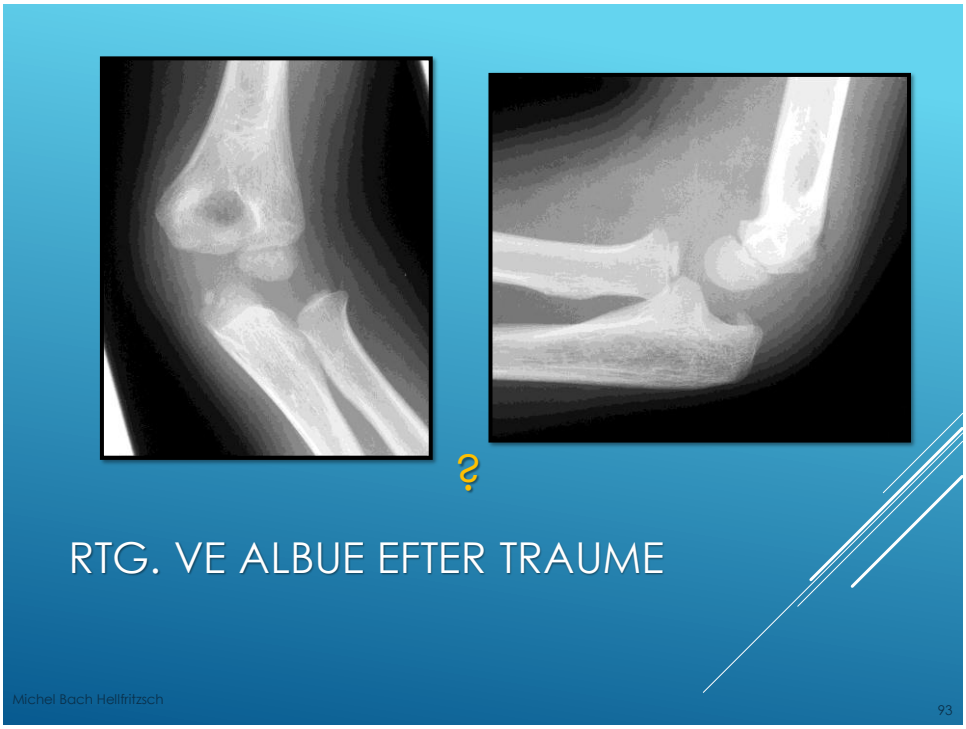
?
RTG. VE ALBUE EFTER TRAUME
Michel Bach Hellfritzsch
93

93


RTG. RASKE HØJRE ALBUE TIL SAMMENLIGNING
Michel Bach Hellfritzsch
94

94





RTG. RASKE HØJRE ALBUE TIL SAMMENLIGNING

Michel Bach Hellfritzsch

95

95





RTG. VE ALBUE POSTOPERATIVT

Michel Bach Hellfritzsch

96

96

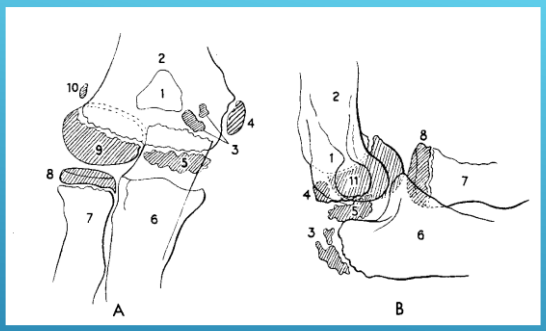

CRITOL
C: Capitulum humeri
R: Radial head
I: Internal epicondyle
T: Trochlea humeri
O: Olecarnon
L: Lateral epicondyle

ANLÆGGELSE AF EPI- OG APOFYSER I ALBUEN HOS BØRN.

Michel Bach Hellfritzsch

97

97



13-ÅRIG DRENG – SYMPTOMER FRA VENSTRE HOFTE GENNEM LÆNGERE TID

Michel Bach Hellfritzsch

98

98

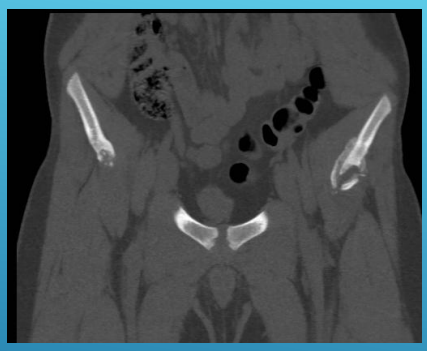



SPINA ILIACA ANTERIOR INFERIOR (SIAI) AVULSION UNDER OPHELING

99

- Mediale humerus epicondyl
- Spina iliaca anterior superior
- Spina iliaca anterior inferior
- Tuber ischiadicum

- Sportsaktive (sprint, fodbold, tennis..)
- Unge

EKSEMPLER PÅ STEDER MED APOFYSIOLYSE

100

Battered child

Michel Bach Hellfritzsch 101

101



8 mdr. dreng

Michel Bach Hellfritzsch 102

102

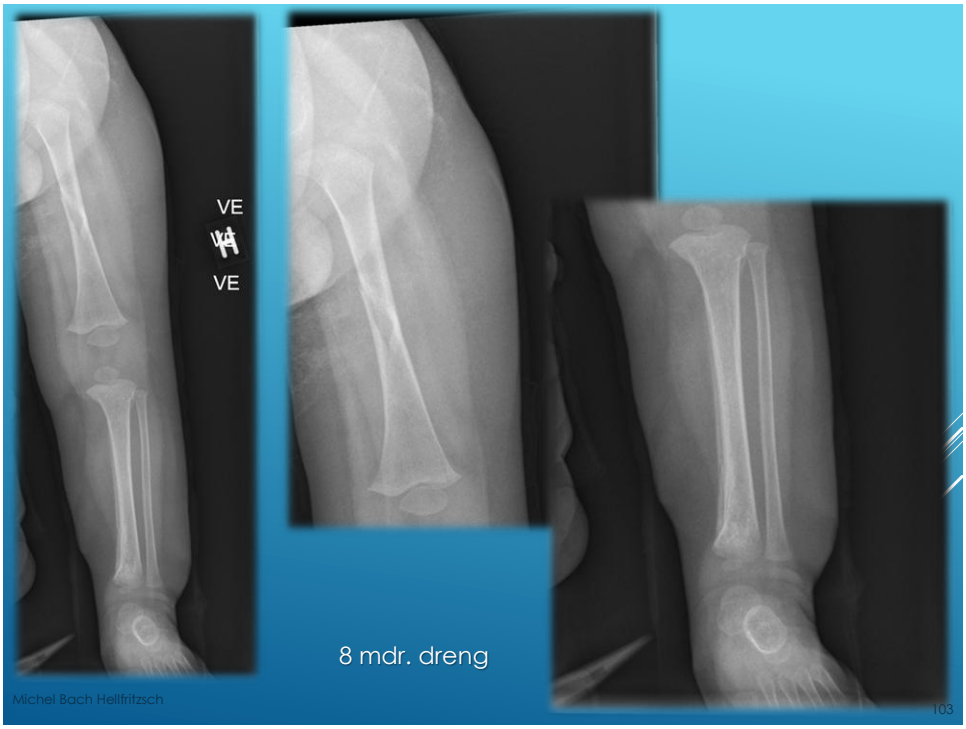
VE
VE
8 mdr. dreng
Michel Bach Hellfritzsch
103

103

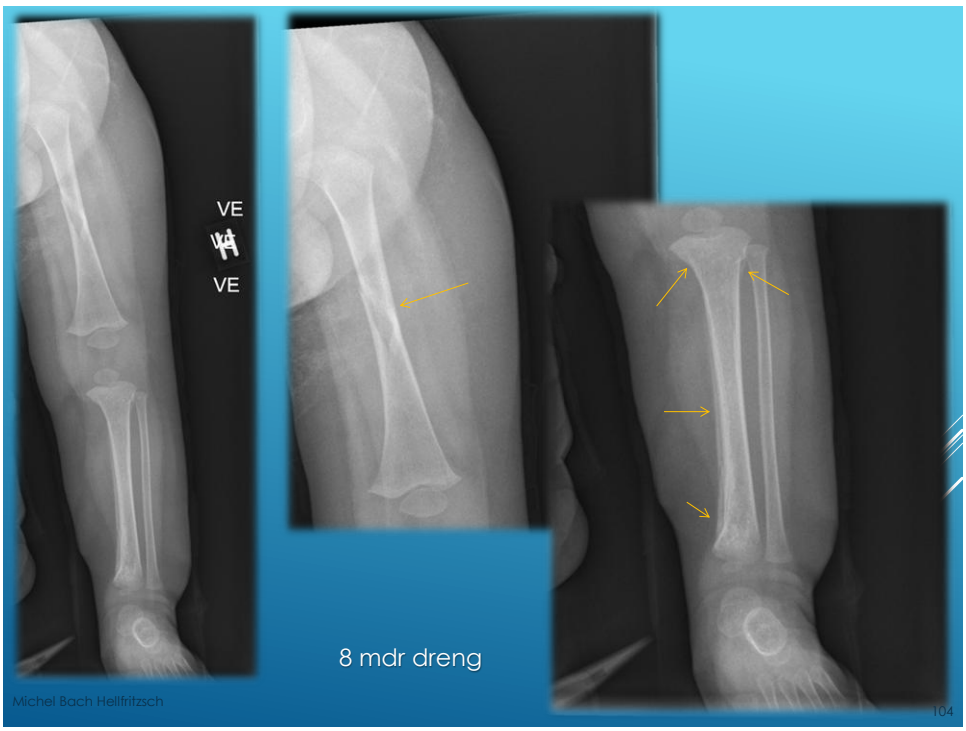
VE
VE
8 mdr dreng
Michel Bach Hellfritzsch
104

104

Fraktur heling og komplikationer

Michel Bach Hellfritzsch 105

105



- Beskrivelse af fraktur

FEMURFRAKTUR 2-ÅRIG: +0 DAGE

Michel Bach Hellfritzsch 106

106



TERMER

Beskrivelse af fraktur

- Lukket/åben
- Beliggenhed (herunder led involvering / fyse involvering)
- Komplet, fissur, infraktion
- Type: Tvær/skrå/indkilet/ komminut/kompression/ avulsion
- Forskydning/dislokation (knoglebredde/cm, retning)
- Vinkling (grader, retning)
- Rotation (svært/umuligt!)

Michel Bach Hellfritzsch

107

107





FRAKTURHELING
FEMUR FRAKTUR 2-ÅRIG: +0 DAGE

Michel Bach Hellfritzsch

108

108

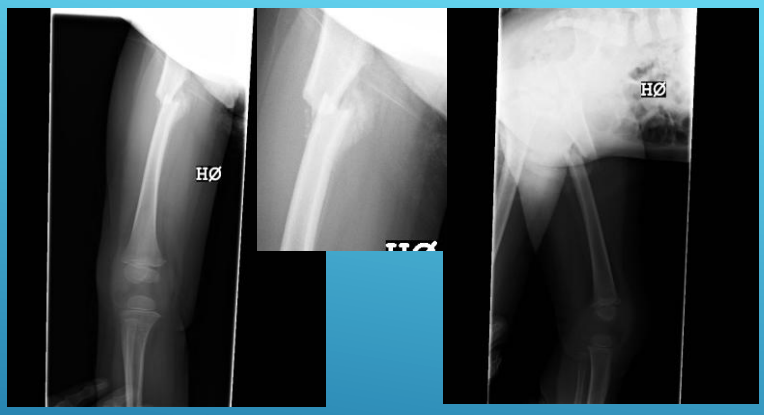

Problem at der er forkortning?

FEMUR FRAKTUR: +14 DAGE

109

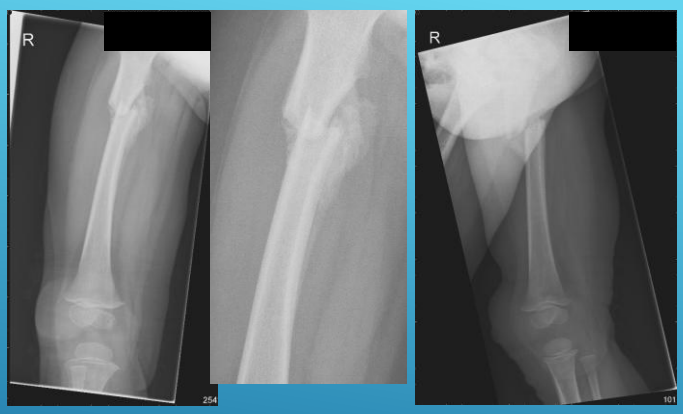

FEMUR FRAKTUR: +18 DAGE

110

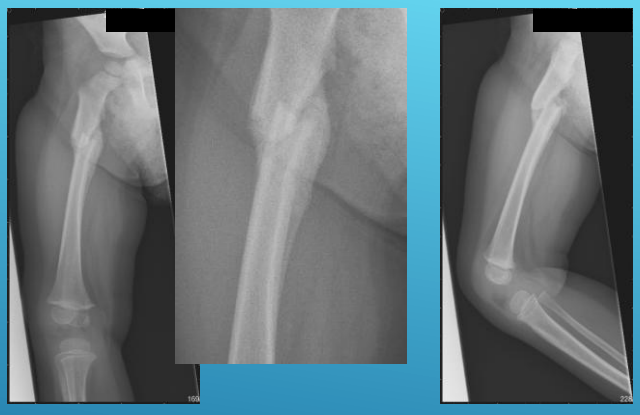

FEMUR FRAKTUR: +29 DAGE

Michel Bach Hellfritzsch

111

111

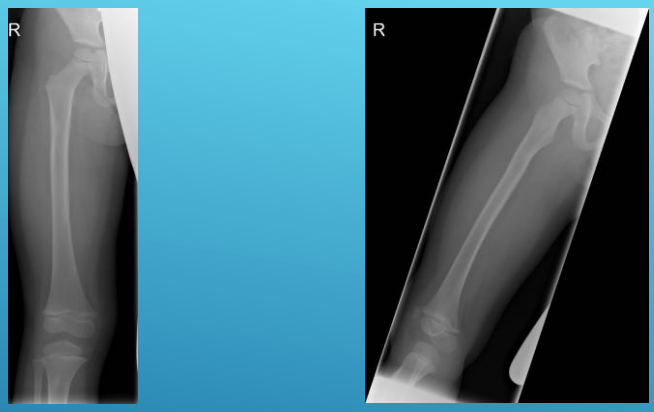

FEMURFRAKTUR: + 2 ÅR

Michel Bach Hellfritzsch

112

112





FRAKTURLUXATION:
8½ ÅR GAMMEL

Michel Bach Hellfritzsch

113

113





+ 4 MDR

Michel Bach Hellfritzsch

114

114

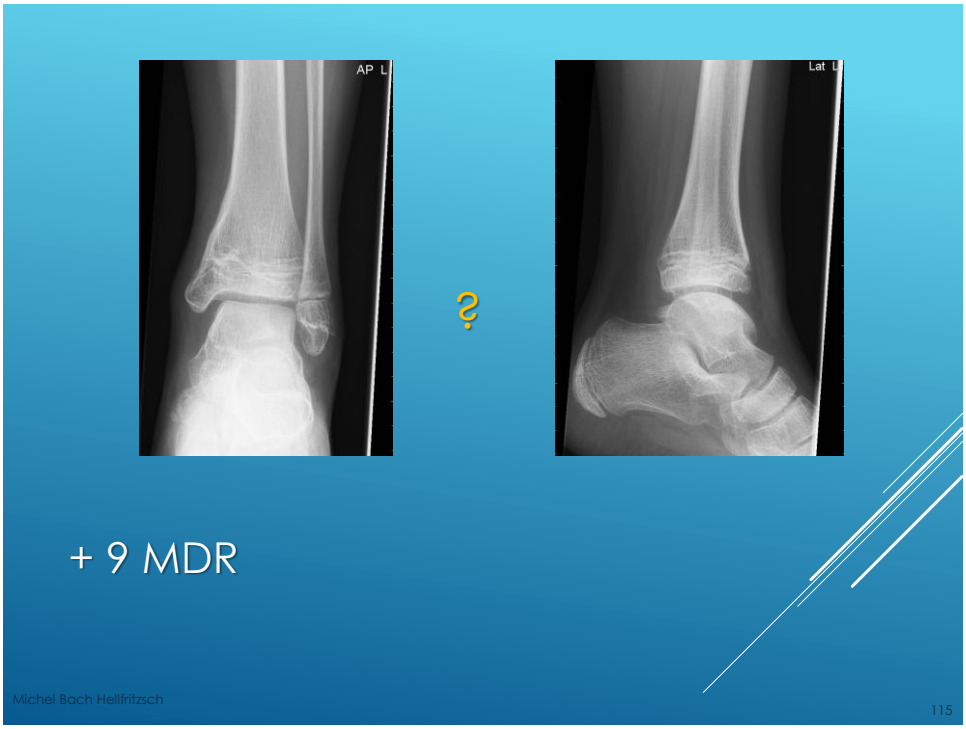
AP L
?
Lat L
+ 9 MDR
Michel Bach Hellfritzsch
115

115

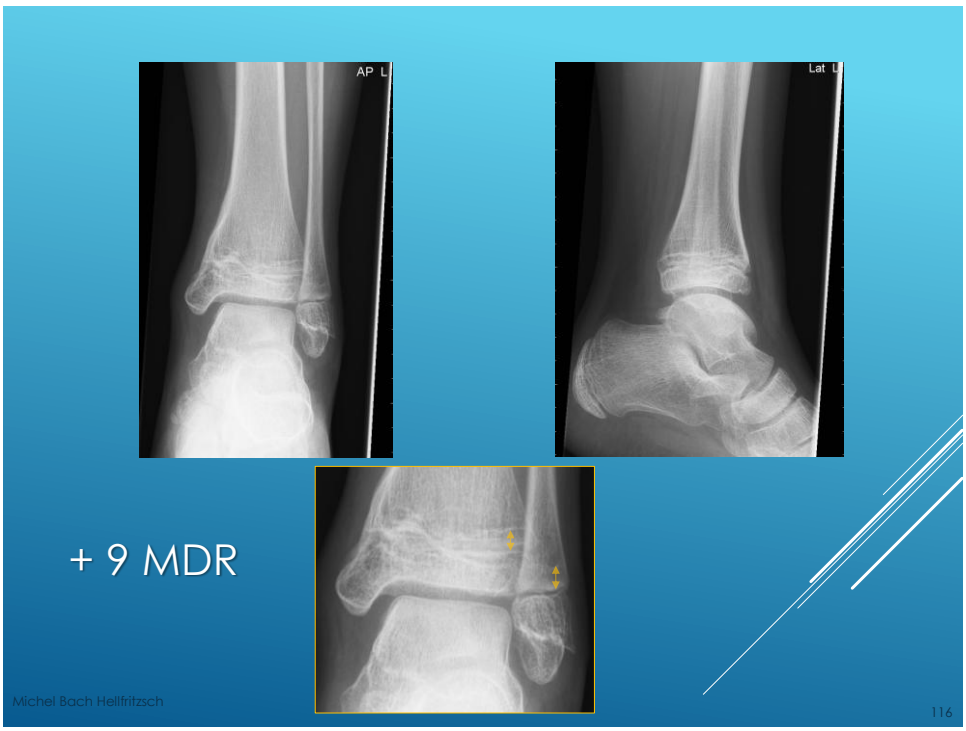
AP L
Lat L
+ 9 MDR
Michel Bach Hellfritzsch
116

116





T1

Brusksekvens (eg PD fs)

+9 MDR

Michel Bach Hellfritzsch

117

117





T1

Brusksekvens (eg PD fs)

+9 MDR

Michel Bach Hellfritzsch

118

118

Frakturer: Vigtige punkter

119

BØRNEFRAKTURER

- Infraktioner (inkomplette):
  - Torus fraktur (buckle fracture)
  - Greenstick fraktur
  - Bøjningsfraktur (bowing fracture)
- Vækstskive frakturer (Salter-Harris fraktur typer)
- Apofyse frakturer
- Påført skade/Battered child/NAI

120

- Vækstlinie:

Stødabsorberende

Svagere end ligamenterne

- Tyk periost:

Ud over at være tyk, også meget stærk

Nedsætter risikoen for frakturdislokation

Løsere bundet til knoglen – især hos mindre børn

- Anderledes biomekanik:

Mindre skrøbelige

Fleksible, elastiske og plastiske

KNOGLER: BØRN VS. VOKSNE

121

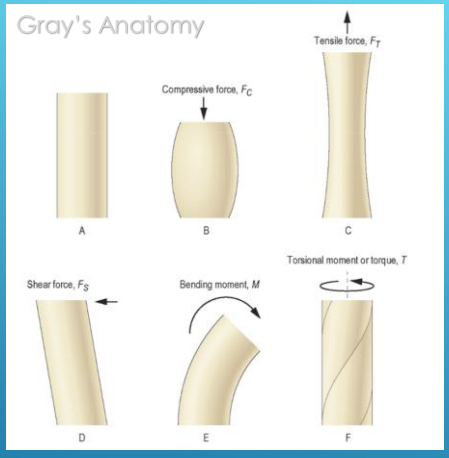

TRAUME MEKANISMER

122

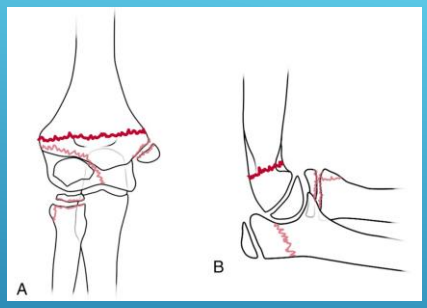

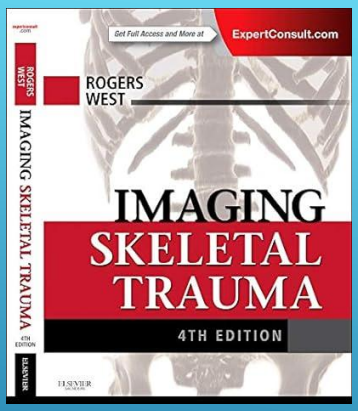

KENDSKAB TIL DE ALMINDELIGSTE FRAKTURSTEDER

Michel Bach Hellfritzsch

123

123

KNOGLETUMORER

Michel Bach Hellfritzsch

124

124

KNOGLE OG BLØDDELSTUMORER: DIFFERENTIAL DIAGNOSER – NORMAL ANATOMISKE VARIANTER

Der henvises i øvrigt til A-kursus i Muskuloskeletal radiologi

125

Tumor lignende forandringer og normal anatomiske varianter

126

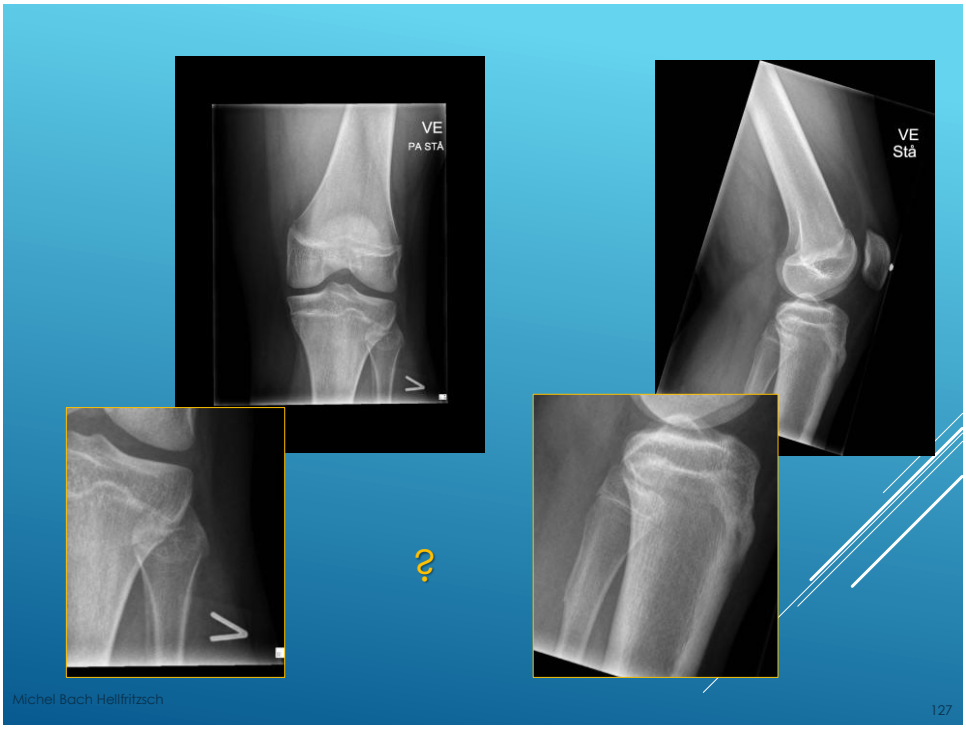
VE
PA STÅ
VE
Stå
?
Michel Bach Hellfritzsch
127

127

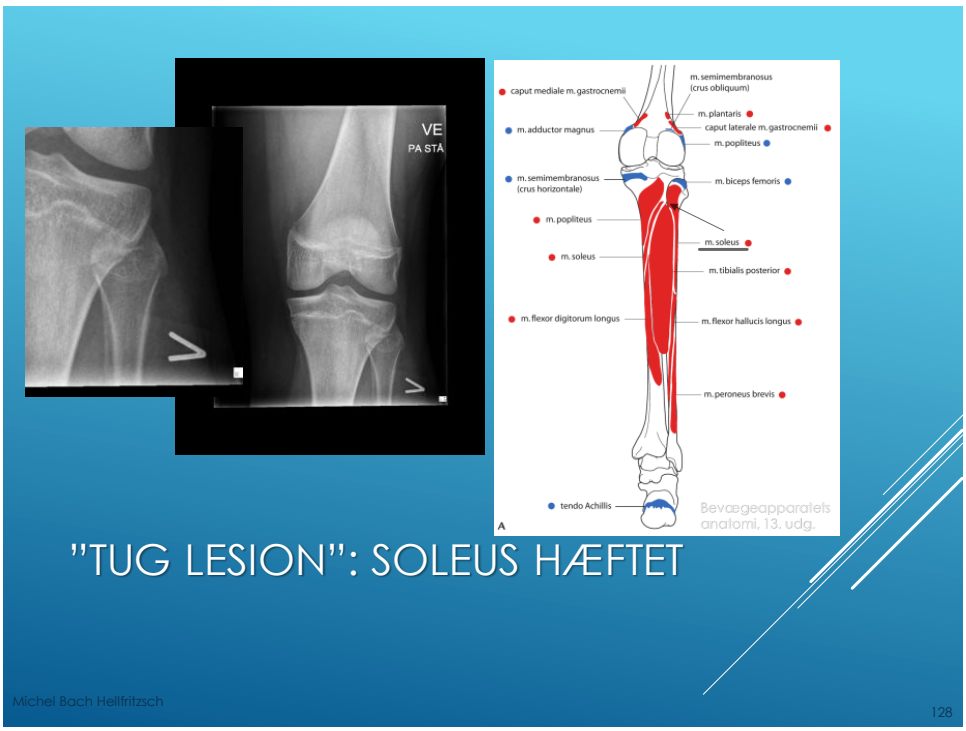
VE
PA STÅ
caput mediale m. gastrocnemii
m. adductor magnus
m. semimembranosus (crus horizontale)
m. popliteus
m. soleus
tendo Achillis
m. semimembranosus (crus obliquum)
m. plantaris
caput laterale m. gastrocnemii
m. popliteus
m. biceps femoris
m. soleus
m. tibialis posterior
m. flexor digitorum longus
m. flexor hallucis longus
m. peroneus brevis
A
Bevægeapparatets anatomi, 13. udg.
"TUG LESION": SOLEUS HÆFTET
Michel Bach Hellfritzsch
128

128


FORANDRINGER?
Michel Bach Hellfritzsch
129

129

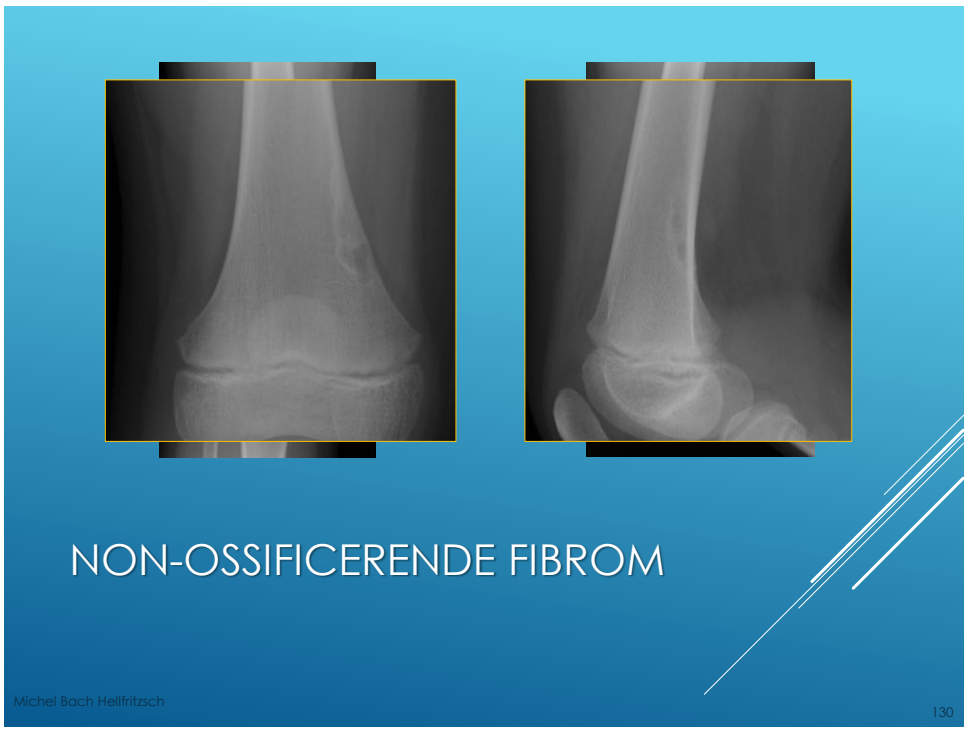
NON-OSSIFICERENDE FIBROM
Michel Bach Hellfritzsch
130

130





Kontrol to år senere

NON-OSSIFICERENDE FIBROM

Uden klinisk betydning, hvis meget store dog risiko for patologisk fraktur

131

- Stage A: Small, eccentric, cortically based lesions near the epiphysis with smooth, round borders.
- Stage B: Lesions become polycystic with clear but thin sclerotic borders, increasing in size and exhibiting variable distances from the epiphysis. The most significant growth typically occurs during this stage, transitioning from Stage A or within Stage B.
- Stage C: Lesions demonstrate increased sclerosis and reduced growth potential. The radiographic features in Stage C can be quite variable and can be a source of confusion [19].
- Stage D: Complete and homogeneous sclerosis is observed, with no further growth.

NON-OSSIFICERENDE FIBROMER: RITSCHL KLASSIFIKATION

WALKER ET AL: "NON-OSSIFYING FIBROMAS: A 2025 REVIEW", J. CLIN. MED. 2025, 14, 6428

132

- Cortical thickness < 2 mm on CT imaging
- Lesion involving > 50% of the bone diameter on orthogonal radiographs
- Size > 4 cm in weight-bearing bones
- Presence of "Pac-Man Sign" or "syndesmosis sign" in the distal tibia
- Ritschl Stage B lesions with persistent symptoms
- Pain with weight-bearing activities

ØGET FRAKTUR RISIKO HVIS MERE END ET AF DISSE TEGN ER TIL STEDE

WALKER ET AL: "NON-OSSIFYING FIBROMAS: A 2025 REVIEW", J. CLIN. MED. 2025, 14, 6428

Michel Bach Hellfritzsch

133

133

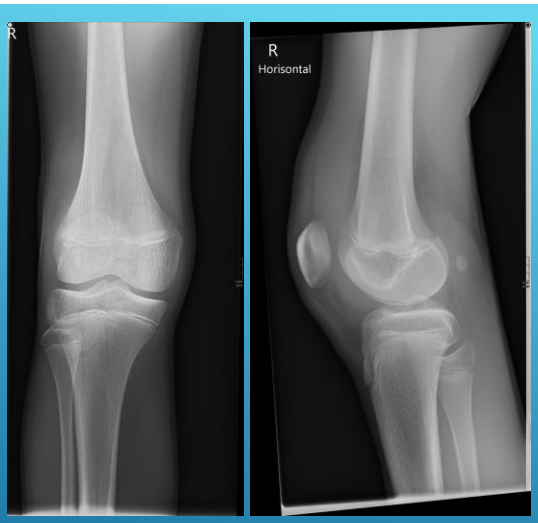

15-ÅRIG DRENG: SMERTER EFTER TRAUME.

Michel Bach Hellfritzsch

134

134

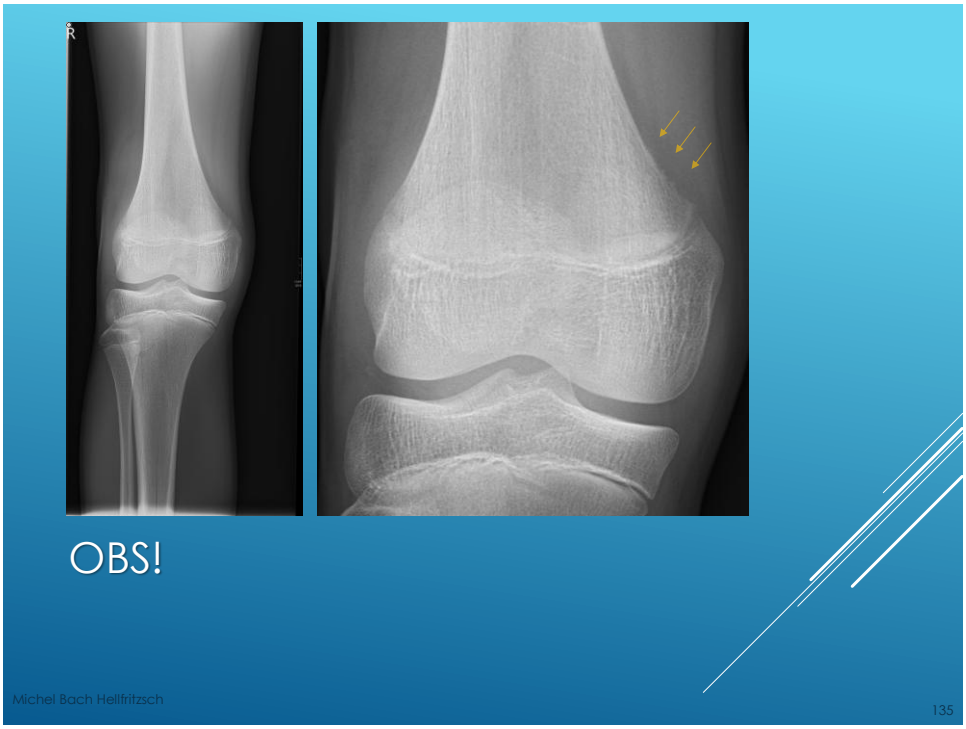
OBS!
Michel Bach Hellfritzsch
135

135


CT
Michel Bach Hellfritzsch
136

136

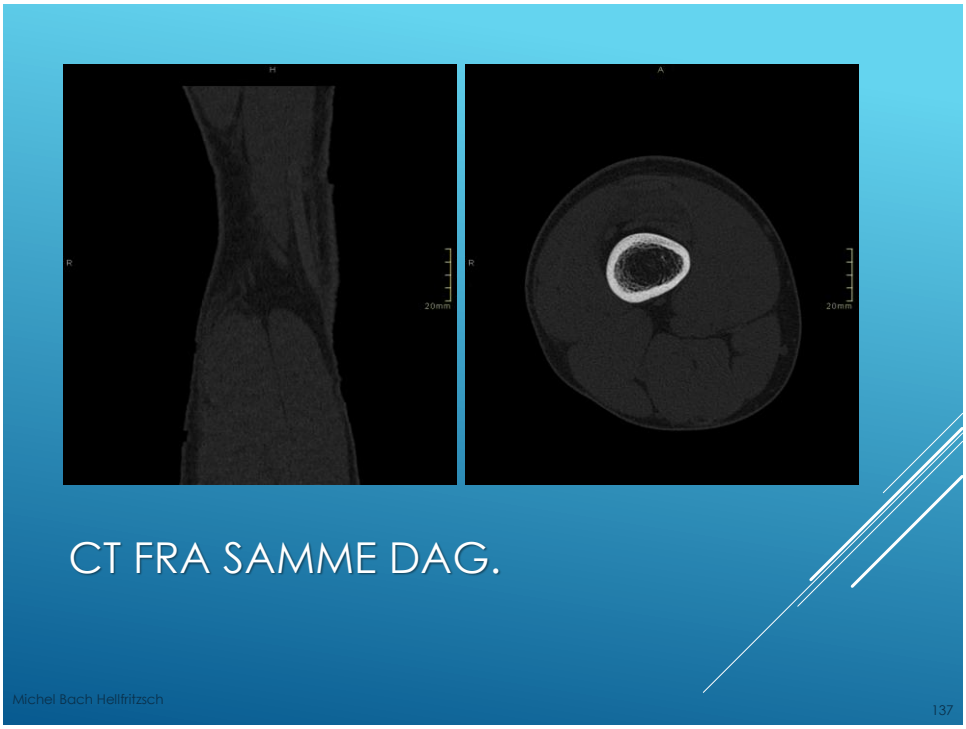
H
R
20mm
A
R
20mm
CT FRA SAMME DAG.
Michel Bach Hellfritzsch
137

137


KONGENITTE OG ERHVERVEDE FORANDRINGER
Michel Bach Hellfritzsch
138

138

HOFTELEDSDYSPLASI

139





DDH: ULTRALYDSKANNING

140

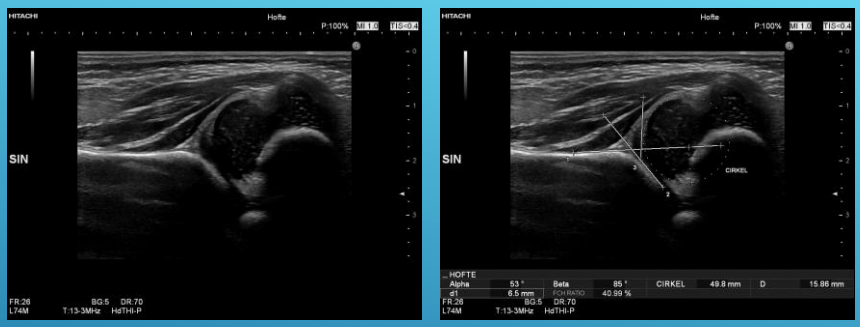

DDH: DYSPLASI OG LATERALISERING, PIGE 9 DAGE

141

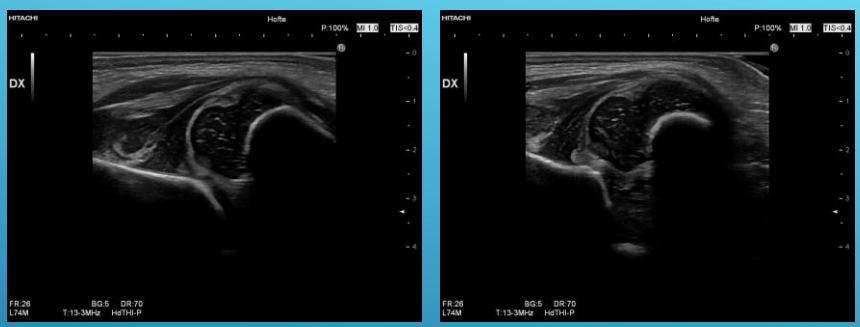

DDH: LUKSATION, DRENG 1 UGE

142

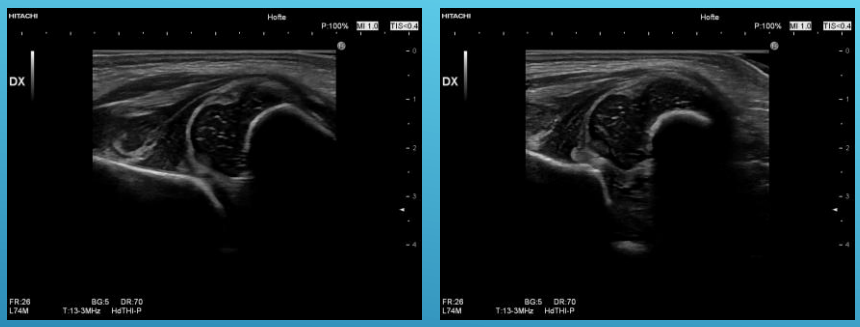

DDH: LUKSATION, DRENG 1 UGE
BEHANDLING: TIDL. DB-SKINNE I 6 UGER, SÅ UL KONTROL, NU PAVLIK SELE I 4-8-12 UGER SÅ KONTROL

143

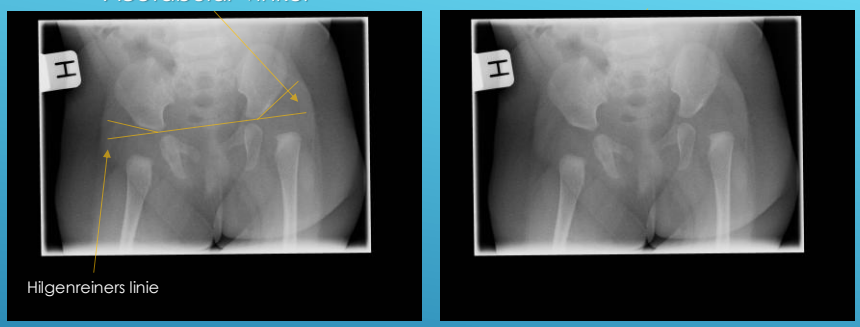

Kaldes ind imellem acetabular indeks: AI

ACETABULAR VINKEL/ACETABULAR INDEKS

144

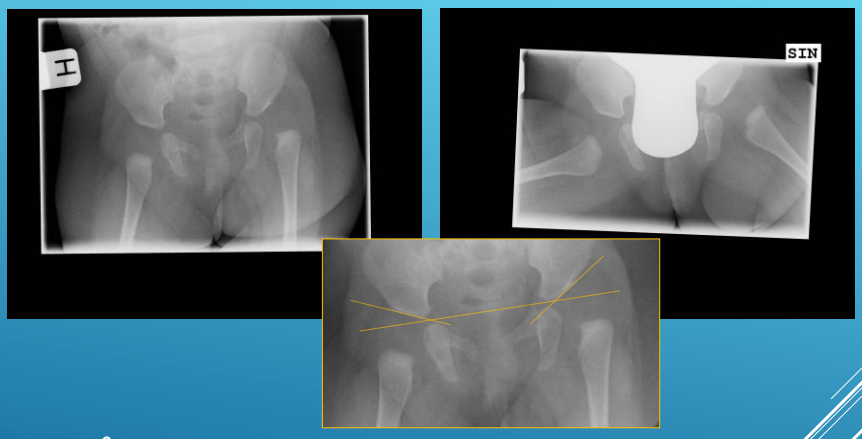

4 MÅNEDER GAMMEL BARN (VANLIGVIS UL TIL 5-6 MDR).

145

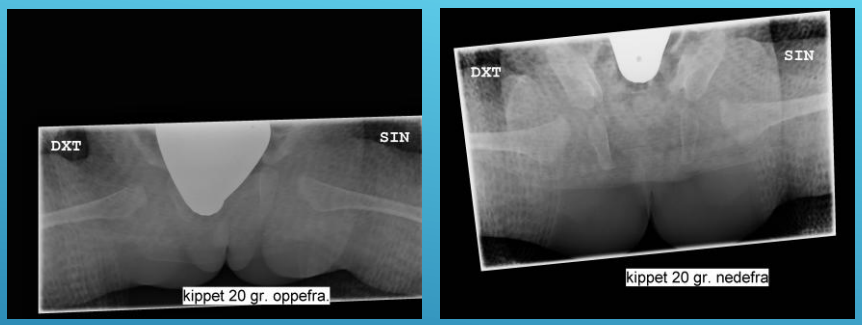

4 MÅNEDER GAMMEL BARN SPICA BEHANDLING, VELREPONERET (ÆLDRE US. DERFOR RTG. PRIMÆRT)

146

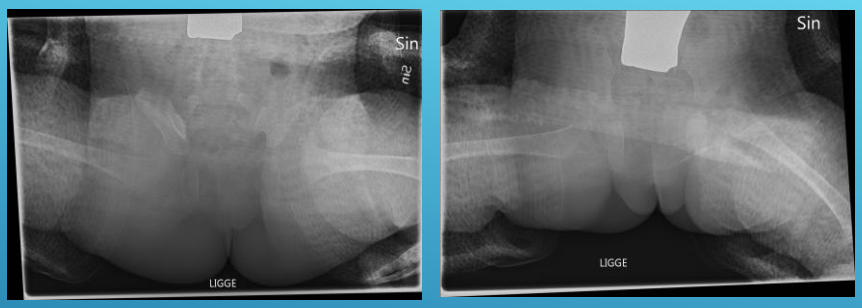

8 MÅNEDER GAMMEL PIGE: SPICA BEHANDLING, IKKE REPONERET

147

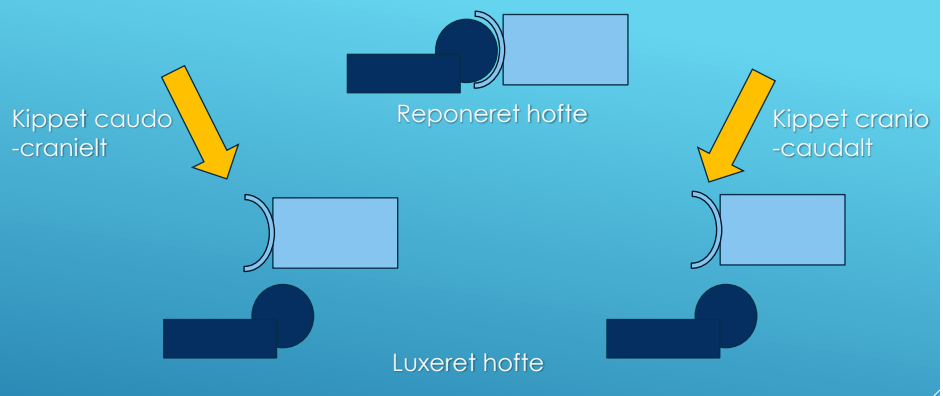

RØNTGEN VED SPICA ELLER UL (HVIS EJ KONKLUSIVT CT/MR)

148

5½ måned gammel barn.

Forkanten af os pubis og femur meta-diafysen ligger på linie

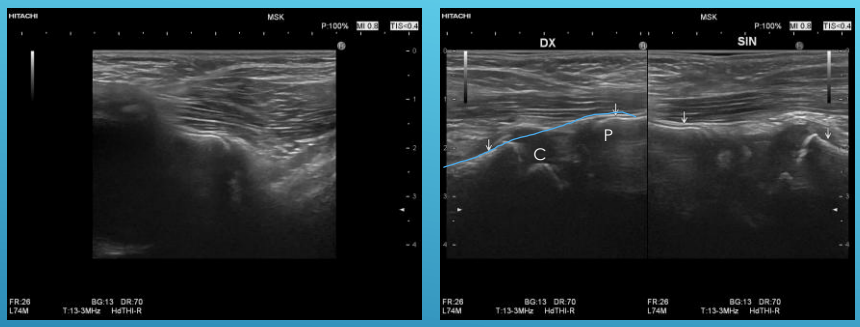

C: Caput femoris. P: Corpus ossis pubis

PER-OP REPONERING AF VENSTRE HOFTE, DYNAMISK UL

Michel Bach Hellfritzsch

149

149





CT (ELLER OPTIMALT MR) I UDVALGTE TILFÆLDE



Michel Bach Hellfritzsch

150

150



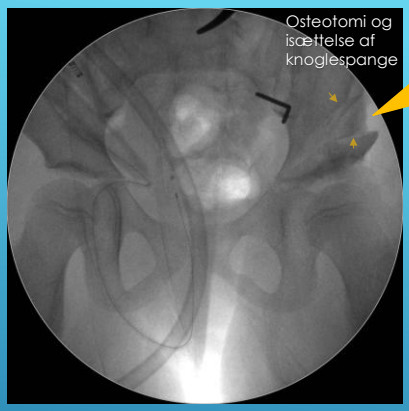

6-ÅRIG PIGE BEHANDLET MED PERIACETABULAR PEMBERTON OSTEOTOMI

151



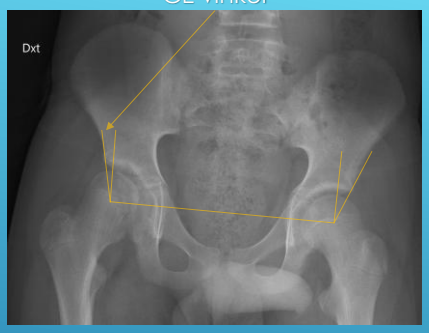

CE VINKEL

152

Acetabular vinkel

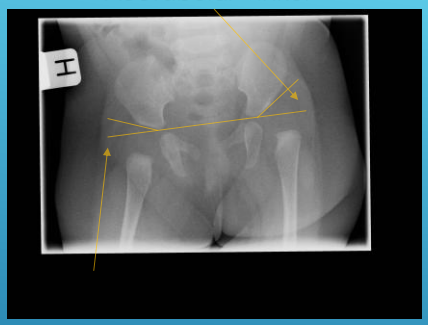

Mindre børn (<6-7 år)

CE vinkel

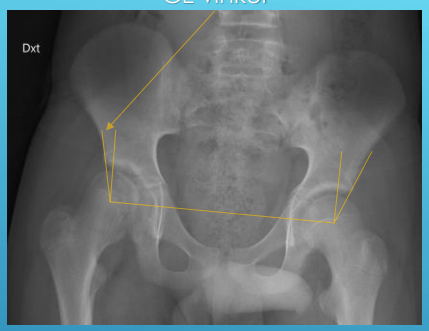

Større børn

UDMÅLING: INDIMELLEM KAN DET VÆRE SVÆRT – SKRIV DET SÅ I BESKRIVELSEN

Michel Bach Hellfritzsch

153

153

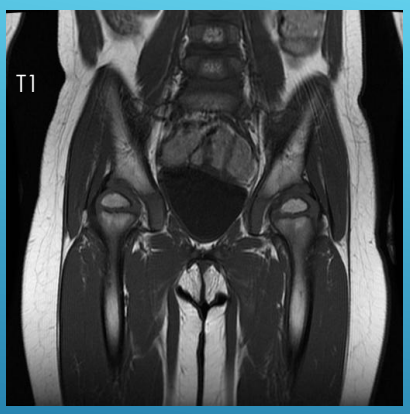

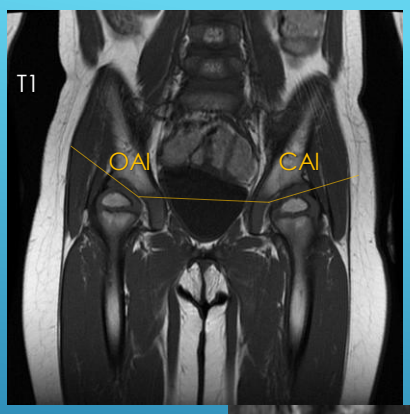

DYSPLASI VURDERING VED MR SKANNING AD MODUM LI: OAI OG CAI BESTEMMELSE



Michel Bach Hellfritzsch

154

154

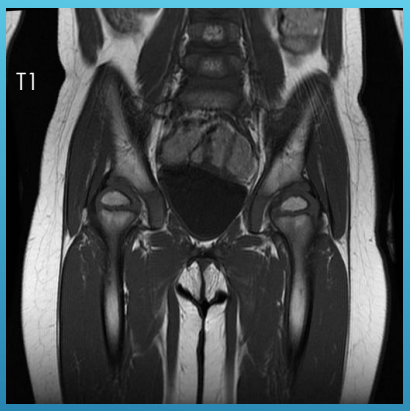

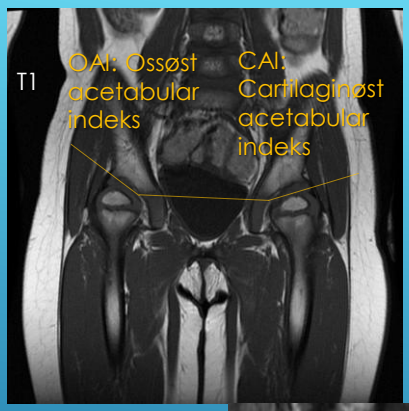

DYSPLASI VURDERING VED MR SKANNING AD MODUM LI: OAI OG CAI BESTEMMELSE

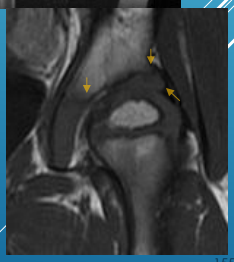

Michel Bach Hellfritzsch

155

155

- CPOP: Cerebral parese (og lignende tilstande) opfølgningsprogram, med kontrol af bl.a. (bevægeapparatet):
  - Hofter (Rtg)
  - Columna (Rtg hvis tegn til skoliose)

- Reimars index:
  - <33%: Kontrol
  - 33%-40%: Klinisk afgørelse
  - >40%: Normalt operation

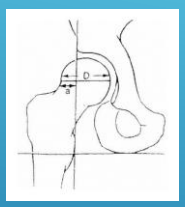

www.cpop.dk

CEREBRAL PARESE

Michel Bach Hellfritzsch

156

156

Gross Motor Function Classification System Expanded and Revised (GMFCS-E&R.

Generelle overskrifter for barnets gangfunktion og illustrationer

	Illustration 6-12 år	Illustration 12-18 år
Niveau I Går uden begrænsninger	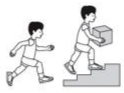	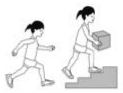
Niveau II Går med begrænsninger		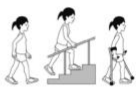
Niveau III Går ved hjælp af håndholdt gangredskab		
Niveau IV Kommer selvstændigt omkring med begrænsninger. Bruger evt. elektrisk køretøj		
Niveau V Transporteres i manuel kørestol	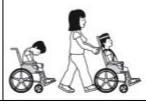	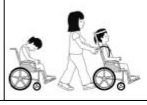

Illustrationer fra ww.canchild.ca

https://www.cpop.dk/wp-content/uploads/R%C3%B8ntgen-manual_22.1.2014.pdf

157

Barn med cerebral parese

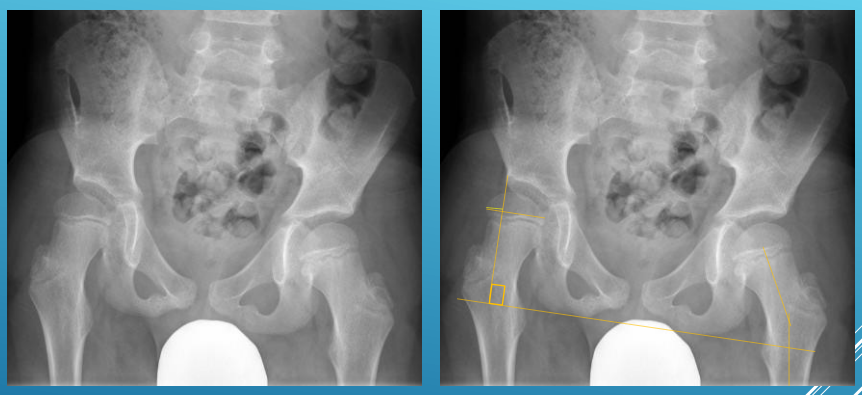

LATERALISERING, DYSPLASI OG COXA VALGA
REIMERS INDEX

158

SKELTAL DYSPLASI

Enkelte eksempler

159

- 90% pga. mutation i et af de to gener der koder for alfa-kæder i collagen type 1 (COL1A1 og COL1A2)
- Knogleskørhed med nedsat knoglemasse og abnormt bindevæv
- Ekstraskeletalt: blå sclerae, dentinogensis imperfecta, løshed i ligamenter og hud, nedsat hørelse
- Type 1-5: Stigende sværhedsgrad: 1,4,5, 3 og 2 (perinatal letal)
- Bemærk: Stor variation i præsentation fra in utero frakturer til milde former med få (eller ingen) frakturer i voksenalder

OSTEOGENESIS IMPERFECTA

160



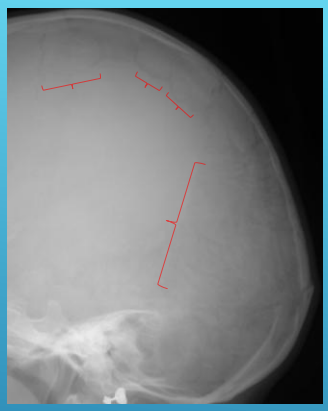

MULTIPLE OSSA WORMIANA

(SES OGSÅ VED EKSEMPELVIS CLEIDOCRANIEL DYSOSTOSE)

Michel Bach Hellfritzsch

161

161

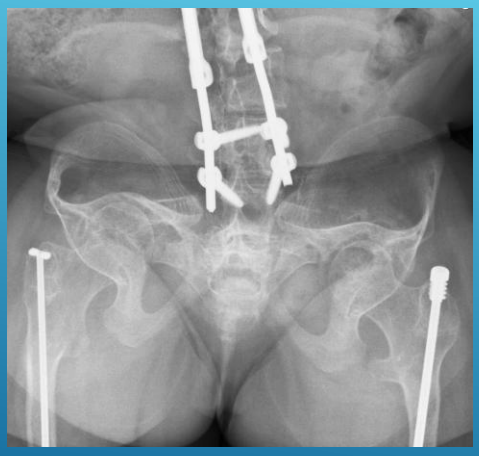

OSTEOGENESIS IMPERFECTA:
CENTRAL MIGRATION AF CAPUT FEMORIS BILATERALT

16-årig kvinde

Michel Bach Hellfritzsch

162

162

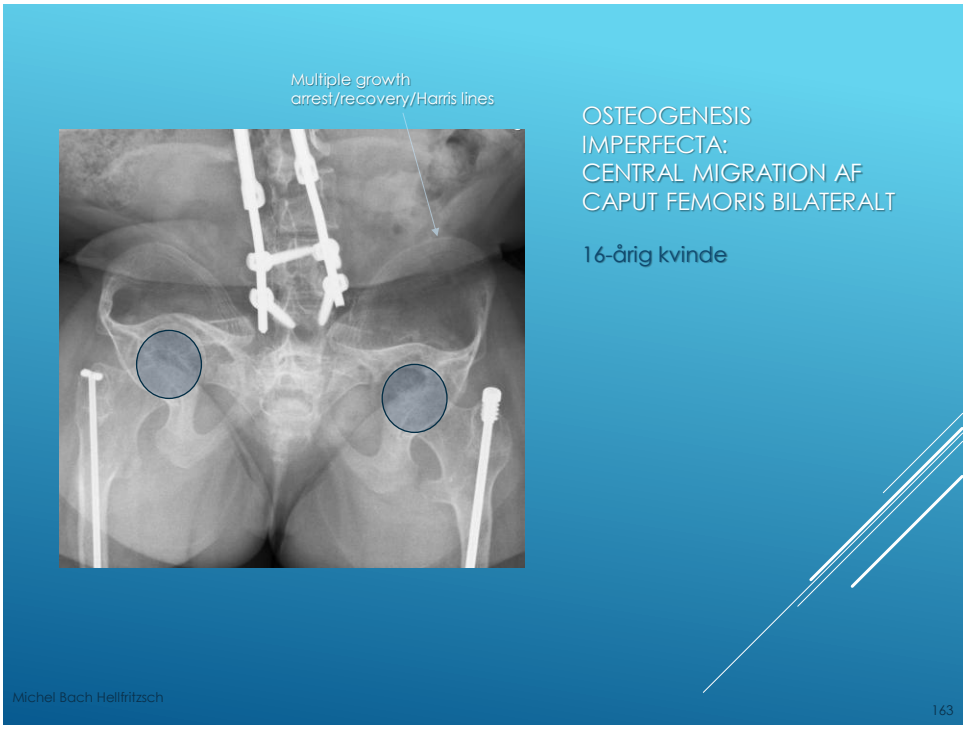
Multiple growth arrest/recovery/Harris lines
OSTEOGENESIS IMPERFECTA: CENTRAL MIGRATION AF CAPUT FEMORIS BILATERALT
16-årig kvinde
Michel Bach Hellfritzsch
163

163

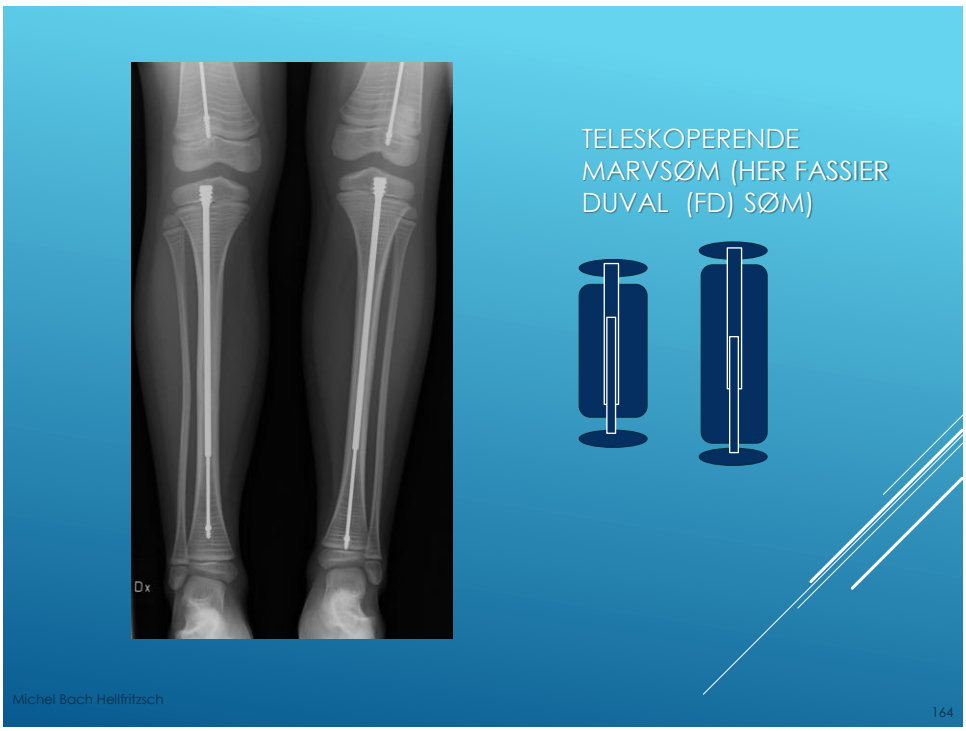
Dx
TELESKOPERENDE MARVSØM (HER FASSIER DUVAL (FD) SØM)
Michel Bach Hellfritzsch
164

164

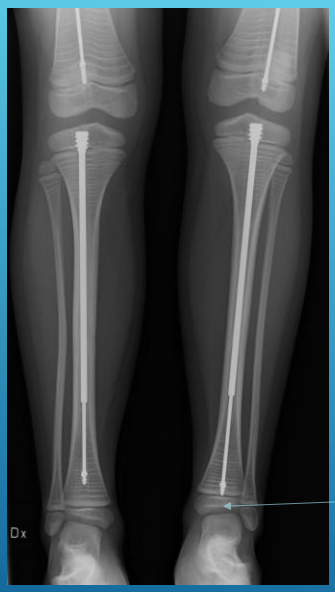

TELESKOPERENDE MARVSØM (HER FASSIER DUVAL (FD) SØM)

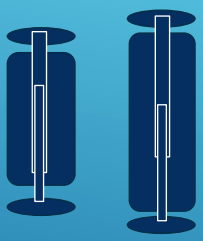

Optimalt skulle gevindet have været i epifysekernen, med den lille kugle på niveau med epifyselinien.

Michel Bach Hellfritzsch

165

165

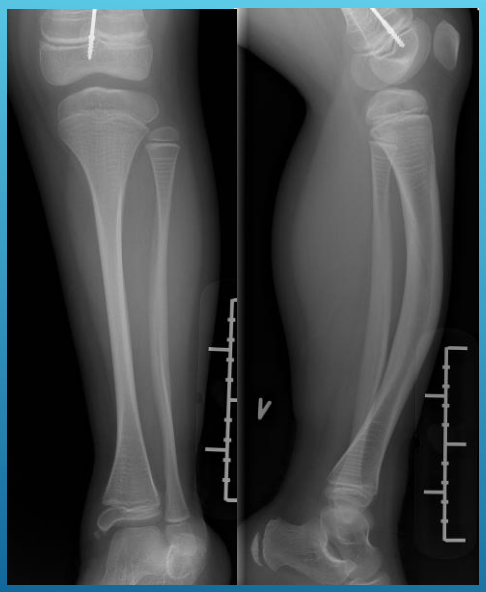

OSTEOGENESIS IMPERFECTA

Bøjning af vægtbærende knogler

Michel Bach Hellfritzsch

166

166



OSTEOGENESIS IMPERFECTA

Postoperative kontrol med isættelse af FD søm efter osteotomi i tibia.

Michel Bach Hellfritzsch

167

167

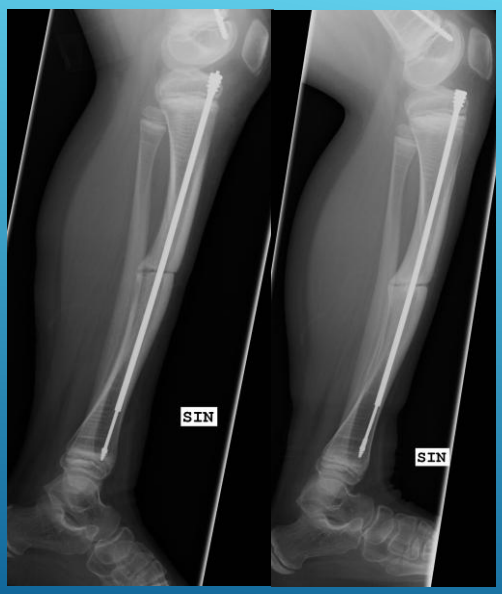

OSTEOGENESIS IMPERFECTA

Kontrol efter hhv. 3 og 9 måneder med forsinket heling.

Bemærk den proximale migration af den distale del af sømmet, der ikke var placeret i epifysekernen.

Michel Bach Hellfritzsch

168

168


R
3-ÅRIG PIGE: TRAUME OG KONTROL +15 DAGE.
Michel Bach Hellfritzsch
169

169


R
3-ÅRIG PIGE: TRAUME OG KONTROL +15 DAGE.
Michel Bach Hellfritzsch
170

170

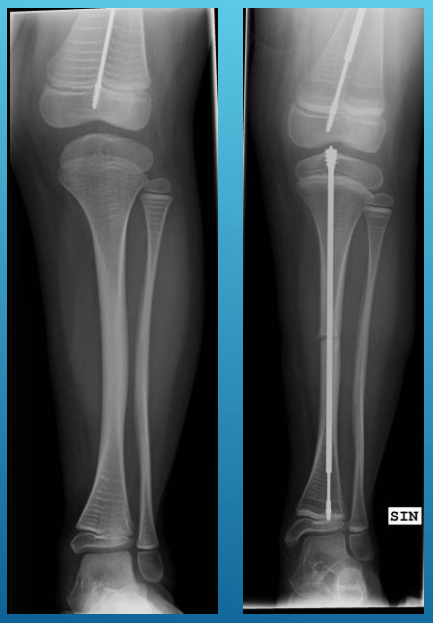

+2 år

RTG. MED TO ÅRS MELLEMRUM: KNOGLEFORANDRINGER?

Michel Bach Hellfritzsch

171

171





RTG. MED TO ÅRS MELLEMRUM

Michel Bach Hellfritzsch

172

172





RTG. MED TO ÅRS MELLEMRUM: BIFOSFONATBEHANDLING

Michel Bach Hellfritzsch

173

173

- Dværgvækst
- Fødselshyppighed: 1:10.000-30.000
- Autosomal dominant (FGFR3 mutation)
- Høj mutationsrate (80% har forældre med normal højde)

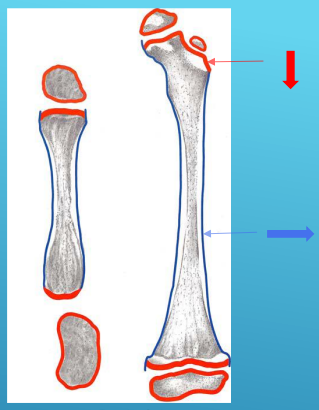

Oestreich

ACHONDROPLASI

Michel Bach Hellfritzsch

174

174



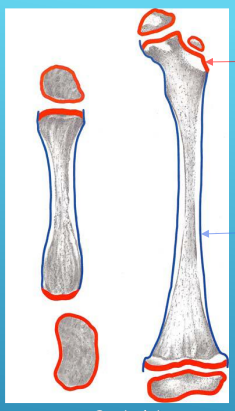

Oestreich

ACHONDROPLASI

Michel Bach Hellfritzsch

175

175

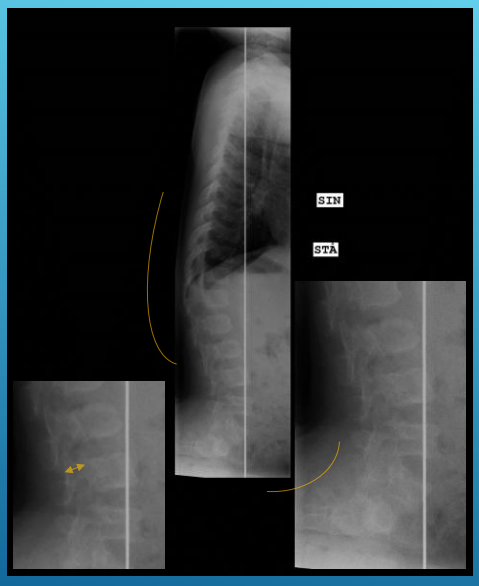

SKOLIOSEOPTAGELSE

Odontoid hypoplasi (få)

Udvikling af kyfose (nogle), samt smertegivende lændelordose

Kort pedikel og interpedikulær afstand. Neurologisk påvirkning af UE ved 20 års alderen hos 20 %

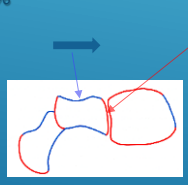

Oestreich

Michel Bach Hellfritzsch

176

176

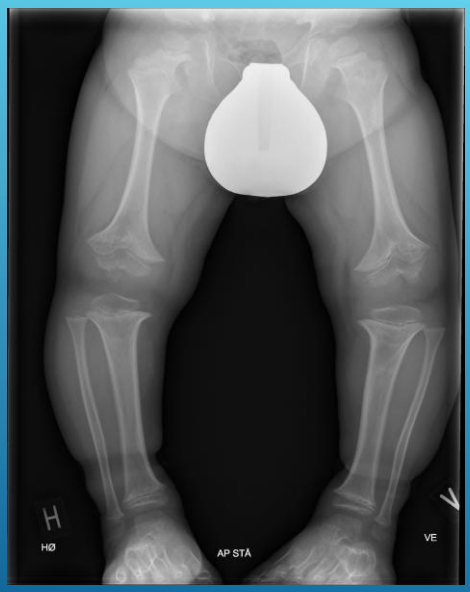

HKA OPTAGELSE

HKA: Hofte-Knæ-Ankel

Stående optagelse med stor FFA (gerne 3 m eller derover)

177

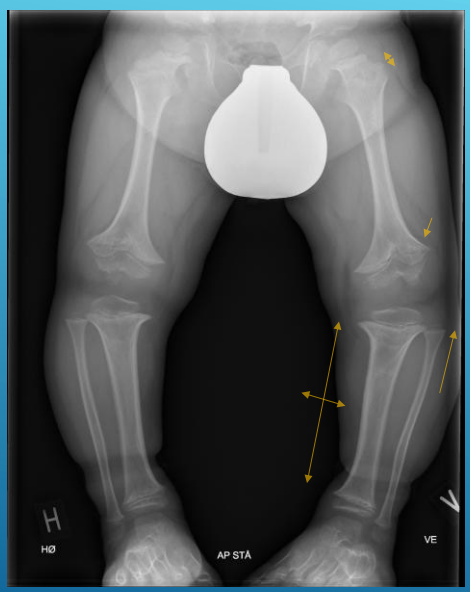

HKA OPTAGELSE

Øget diameter i forhold til længde (dysproportional)

Kort collum femoris

Metafysære uregelmæssigheder

Fibulær overvækst

Genu varum



Oestreich

178

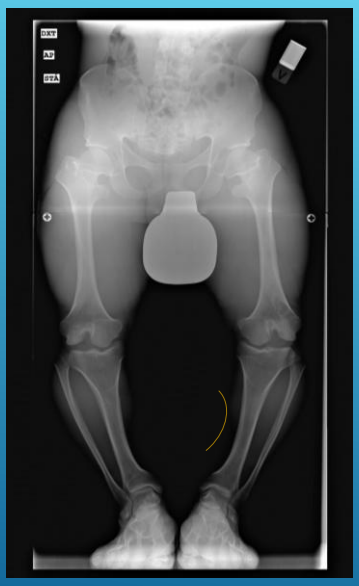

HKA OPTAGELSE

16-årig mand

Michel Bach Hellfritzsch

179

179

MUCOPOLY-SACCHARIDOSER (MPS)

- Lysosomal sygdom
- 4-6/100.000 nyfødte
- Mange subtyper: MPS-I-IX (ikke V eller VIII).
- Fraset MPS-II, autosomal recessiv.
- Normal ved fødsel (progressiv sygdom)
- Skeletalt: Dysostosis multiplex
  - Forsinket vækst/ophør
  - Håndforandringer
  - Columna forandringer
  - Hofteforandringer
  - Tykke korte diafyser og hypopalstiske epifyser

MORQUIO SYNDROM (MUCOPOLYSACCHARIDOSIS IV)

Michel Bach Hellfritzsch

180

180

MORQUIO SYNDROM (MUCOPOLYSACCHARIDOSIS IV)



J-FORMET SELLA
ODONTOID HYPOPLASI (?)

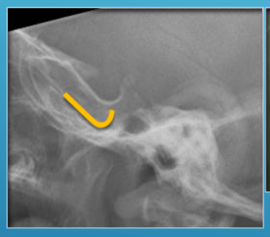



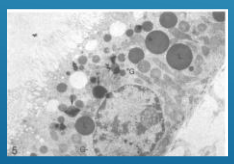

EM billede af proximal tubulus celle: Lysosomer

Michel Bach Hellfritzsch

181

253000

181

MORQUIO SYNDROM (MUCOPOLYSACCHARIDOSIS IV)

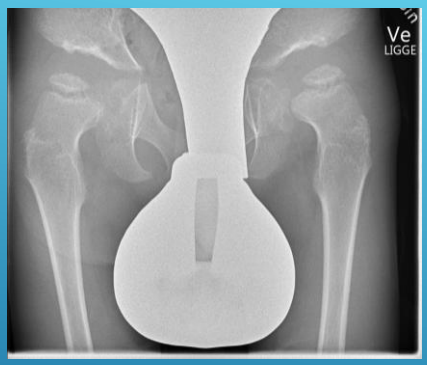

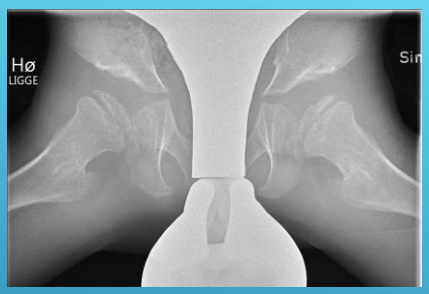



HOFTEDYSPLASI
CAPUT FORANDRINGER

Michel Bach Hellfritzsch

182

182

MORQUIO SYNDROM (MUCOPOLYSACCHARIDOSIS IV)

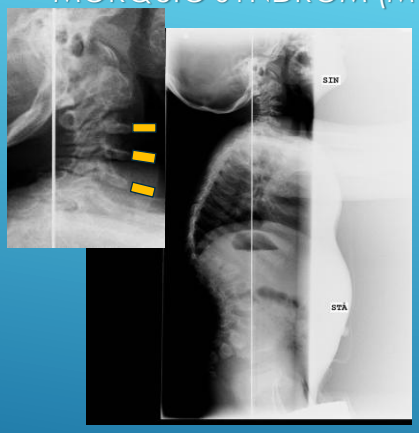

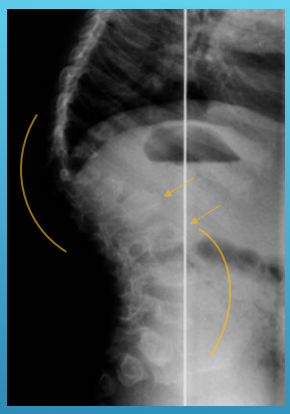

PLATYSPONDYLI
KYFOSE PÅ THORACOLUMBALE OVERGANG
HYPERLORDOSE LUMBALT

183

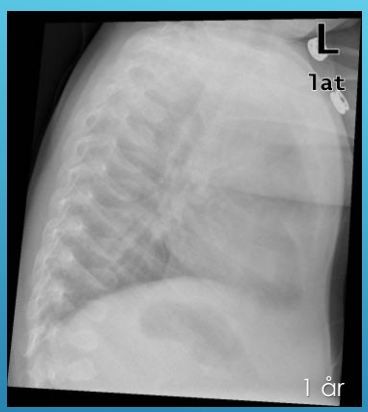

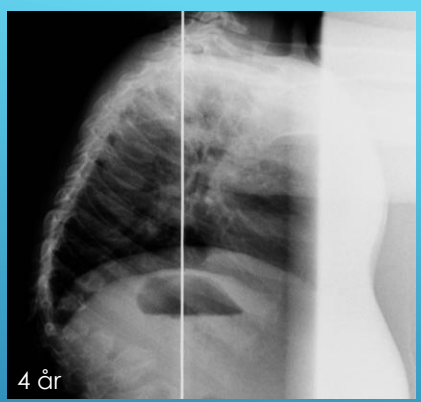

PROGRESSION AF FORANDRINGER (PROGRESSIV SYGDOM)

184

- Systemiske sygdomme og syndromer kan præsentere sig:
- Med tydelige og entydige fund
- Med diskrete forandringer

- Det er vigtigt altid at analysere hele undersøgelsen og evt. tidligere undersøgelser
- Det er vigtigt at have et godt kenskab til den radiologiske normal anatomi
- MDT-konferencer er ofte nødvendige.

SYNDROMER OG DYSPLASIER

SPECIALISTOPGAVE – MEN FOR ALLE VIGTIGT AT KUNNE SE AFVIGELSER FRA DET NORMALE

Michel Bach Hellfritzsch

185

185

DET HALTENDE BARN

Michel Bach Hellfritzsch

186

186

?

- 7-årig dreng.
- Spontant opstået smerter i venstre hofteregion, for få dage siden.
- Ligger med hoften flekteret.
- Afebril

Michel Bach Hellfritzsch

187

187

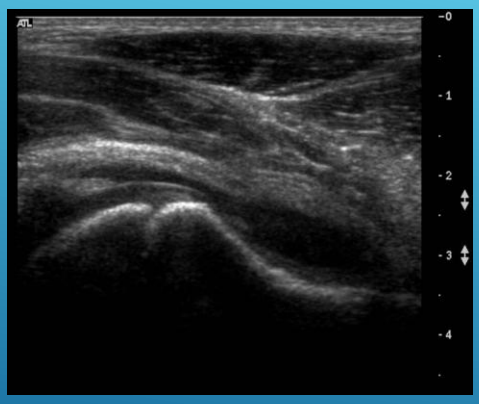

ULTRALYD

Kort anamnese – serøs coxit?

Længere anamnese (> 1 uge?), eller recidiverende symptomer: Rtg. bækken AP+Lauensteins projektion.

Michel Bach Hellfritzsch

188

188

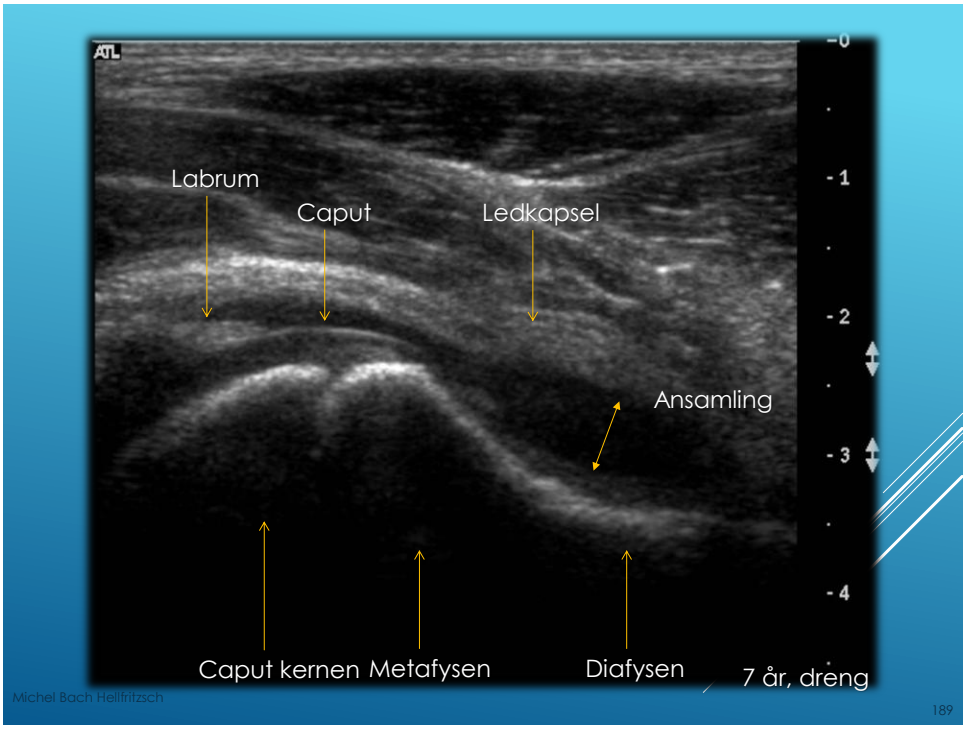
Labrum
Caput
Ledkapsel
Ansamling
Caput kernen
Metafysen
Diafysen
7 år, dreng
Michel Bach Hellfritzsch
189

189

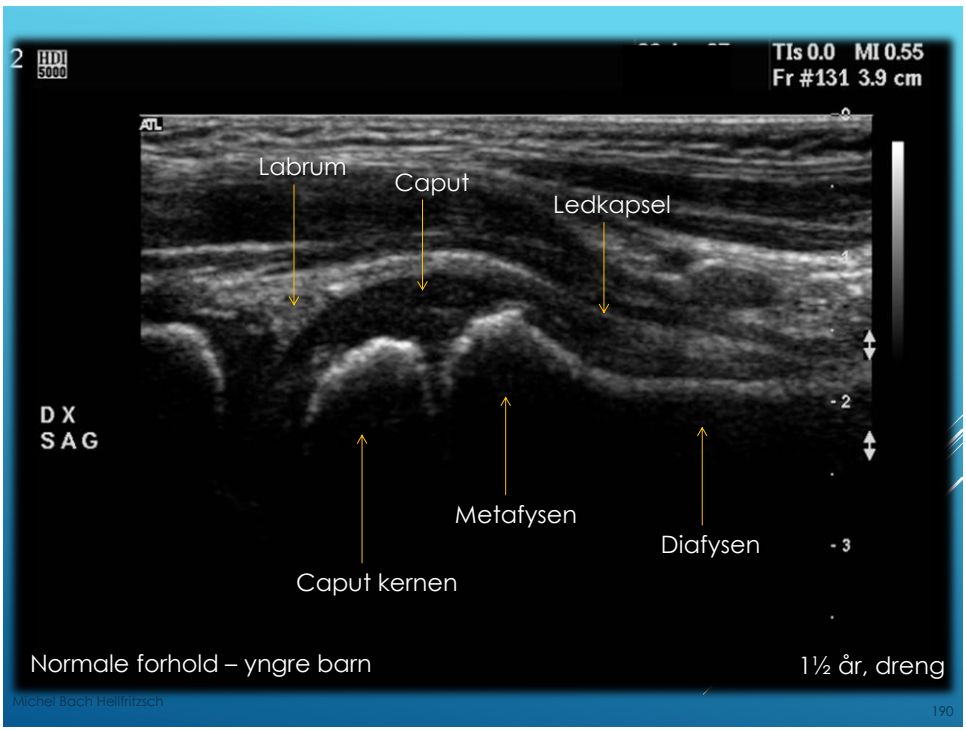
TIs 0.0 MI 0.55
Fr #131 3.9 cm
Labrum
Caput
Ledkapsel
DX
SAG
Metafysen
Diafysen
Caput kernen
Normale forhold – yngre barn
1½ år, dreng
Michel Bach Hellfritzsch
190

190

DET HALTENDE BARN

M. rectus femoris skade

Michel Bach Hellfritzsch

191

191

BILLEDDIAGNOSTIK?

- 9-årig dreng med ømhed og hævelse gennem 1½ måned i højre lår anteriort.
- Klinisk mistanke om tumor.

Michel Bach Hellfritzsch

192

192

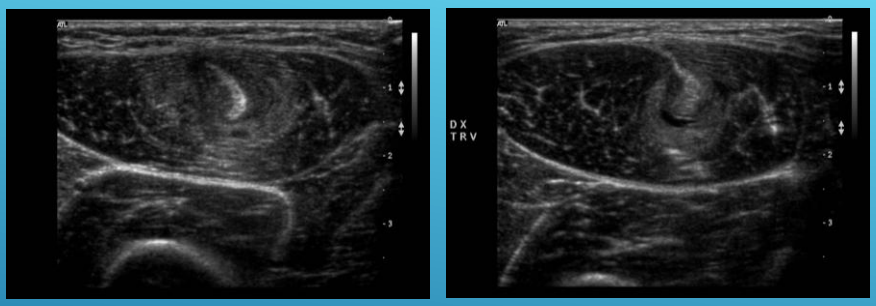

SKANNING HHV. PROXIMALT OG DISTALT VED HÆVELSEN

Michel Bach Hellfritzsch

193

193

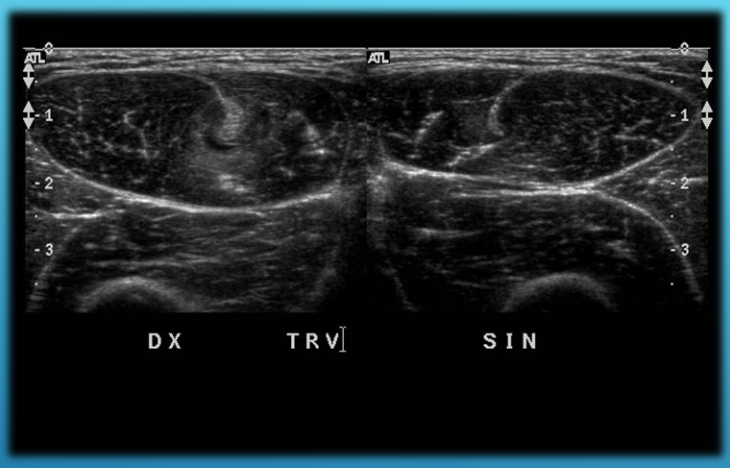

SAMMENLIGNING MED MODSATTE SIDE

Michel Bach Hellfritzsch

194

194

Rectus fem. læsion M 9 år

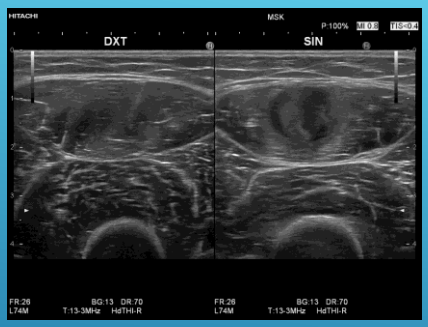

Bakers cyste M 4½ år

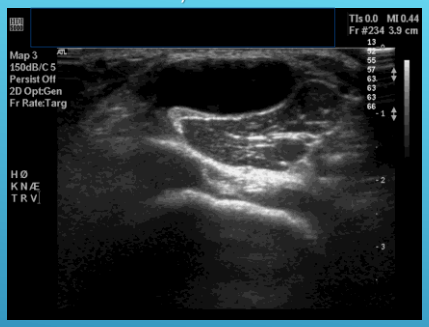

BLØDDELSTUMORER: OVERVEJ OM UL KUNNE VÆRE RELEVANT SOM FØRSTE MODALITET.

Michel Bach Hellfritzsch

195

195

DET HALTENDE BARN

Knæsmerter: Referred pain og lokal årsag

Michel Bach Hellfritzsch

196

196

5 ÅRIG DRENG MED VENSTRESIDIGE KNÆSMERTER.

Michel Bach Hellfritzsch

197

197

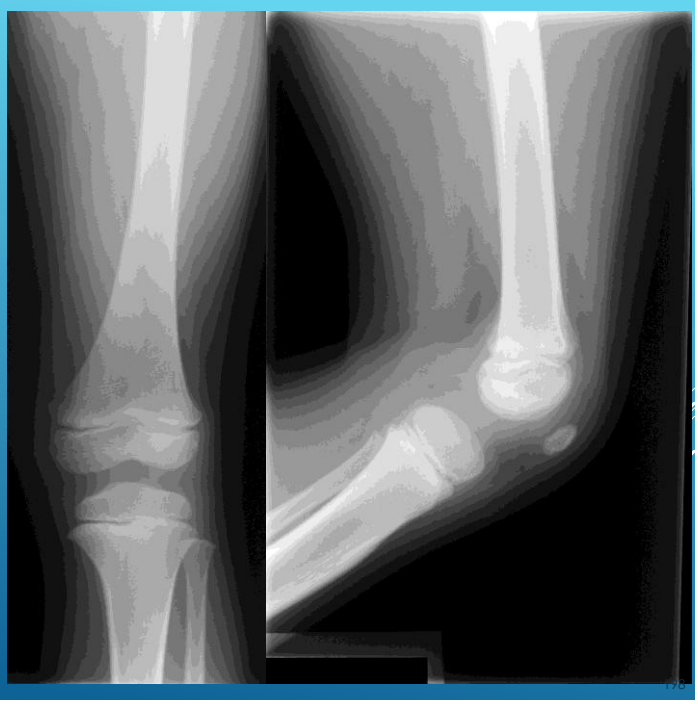

Michel Bach Hellfritzsch

198

198

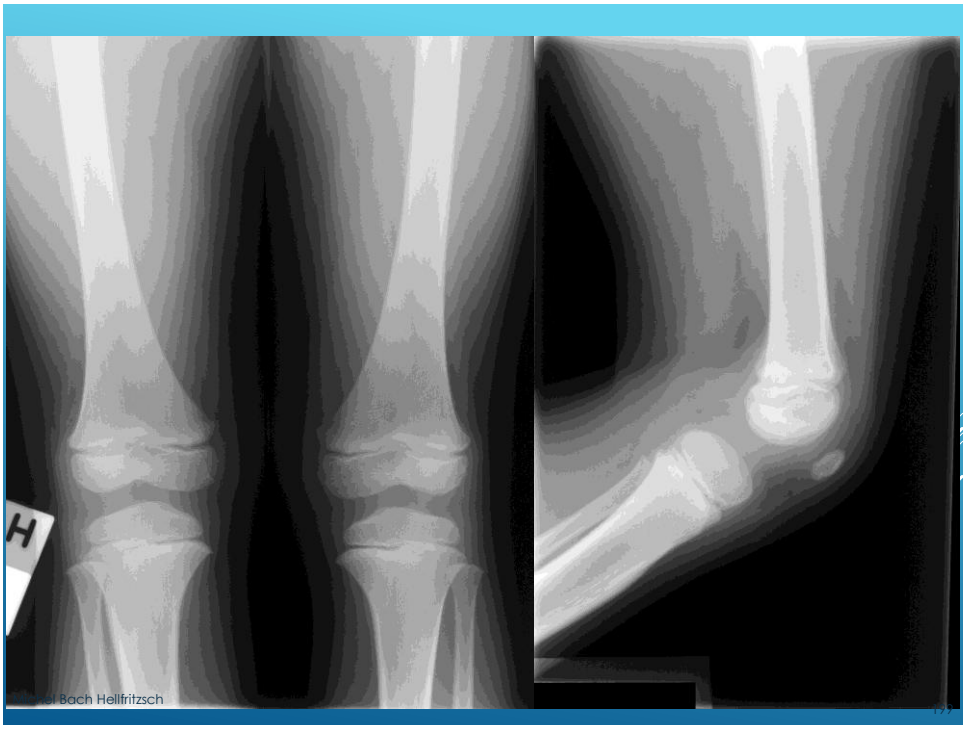

199

DRENGEN NU 6 ÅR GAMMEL (11 MÅNEDER SENERE), SMERTER FRA VENSTRE HOFTE.

200





PROJICEREDE SMERTER FRA HOFTEN

Michel Bach Hellfritzsch

201

201





10-ÅRIG PIGE: KNÆSMERTER

Michel Bach Hellfritzsch

202

202





10-ÅRIG PIGE: DISCOID LATERAL MENISK

Michel Bach Hellfritzsch

203

203

DET HALTENDE BARN

SCFE: Diagnostik, behandling og komplikationer

Michel Bach Hellfritzsch

204

204

11-ÅRIG PIGE, VÆLTET PÅ CYKEL.
SMERTER FRA VENSTRE HOFTE.

Michel Bach Hellfritzsch

205

205

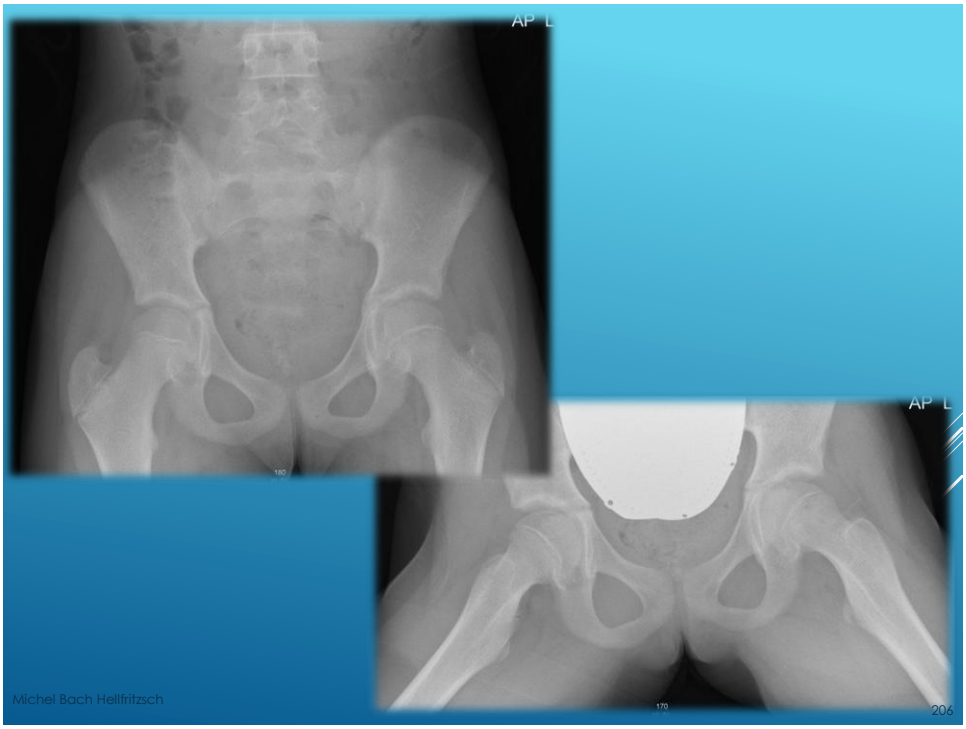

206

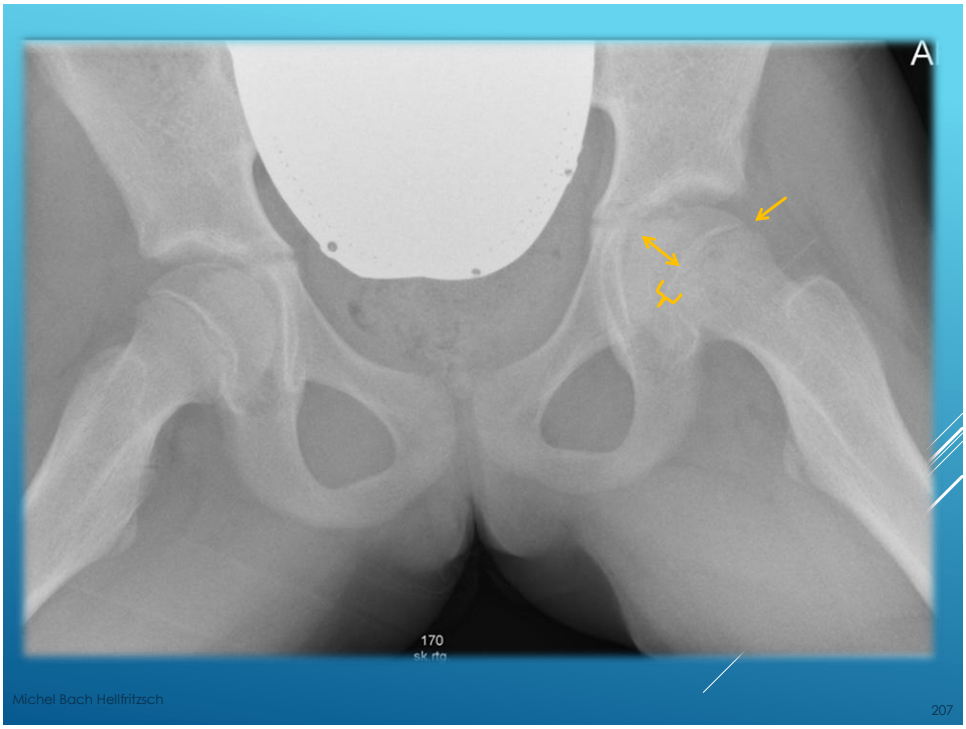
A
170
Michel Bach Hellfritzsch
207

207

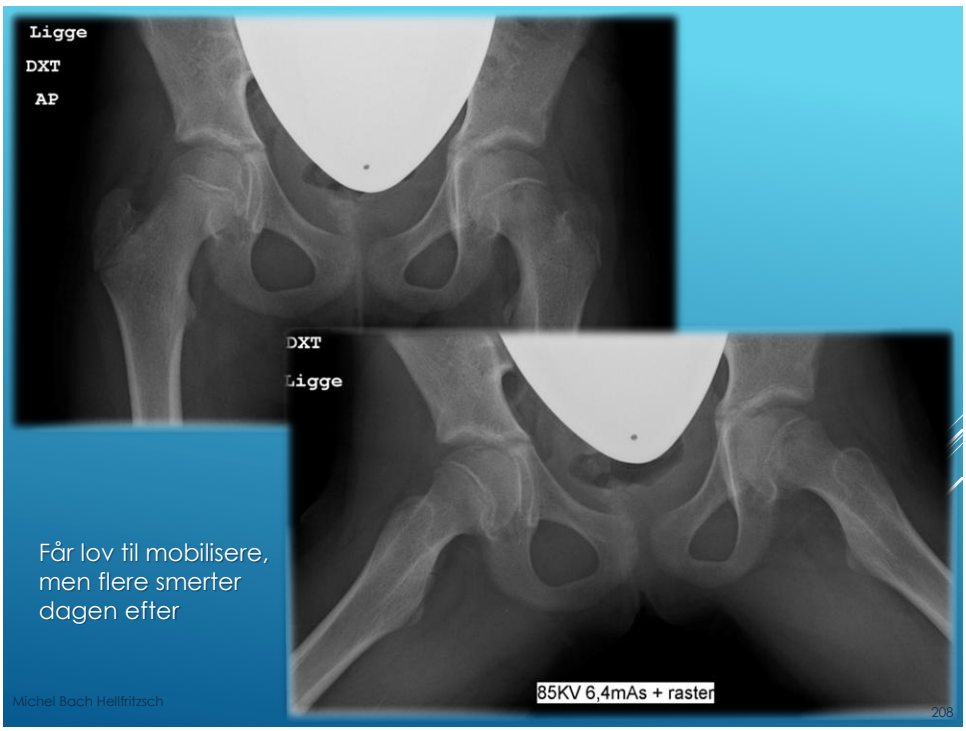
Ligge
DXT
AP
DXT
Ligge
Får lov til mobilisere, men flere smerter dagen efter
85KV 6,4mAs + raster
Michel Bach Hellfritzsch
208

208

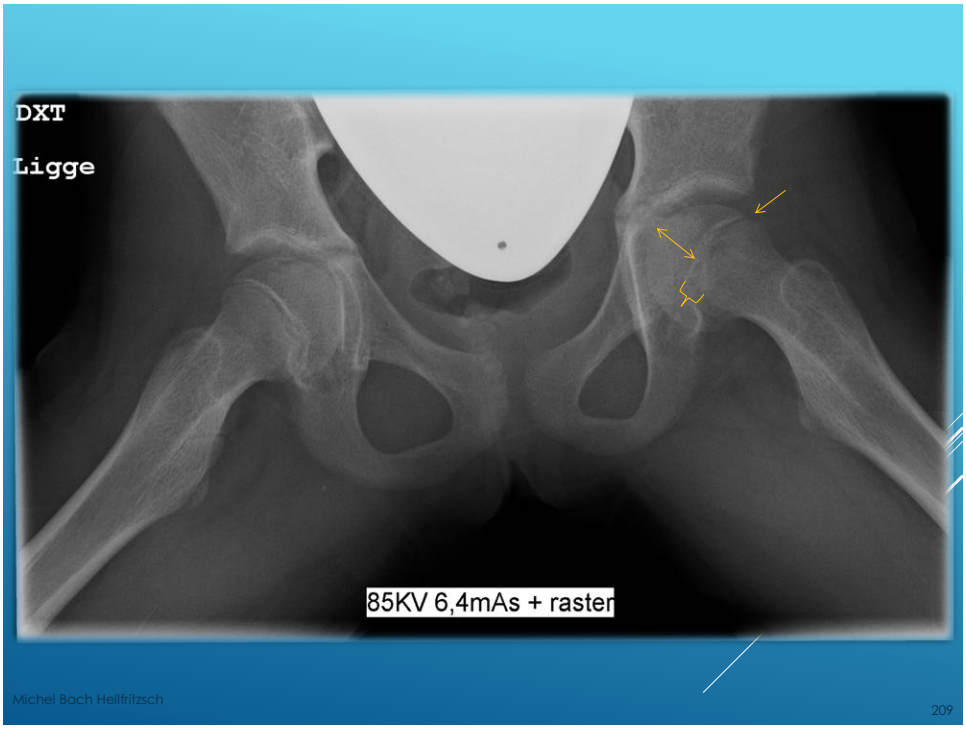
DXT
Ligge
85KV 6,4mAs + raster
Michel Bach Hellfritzsch
209

209

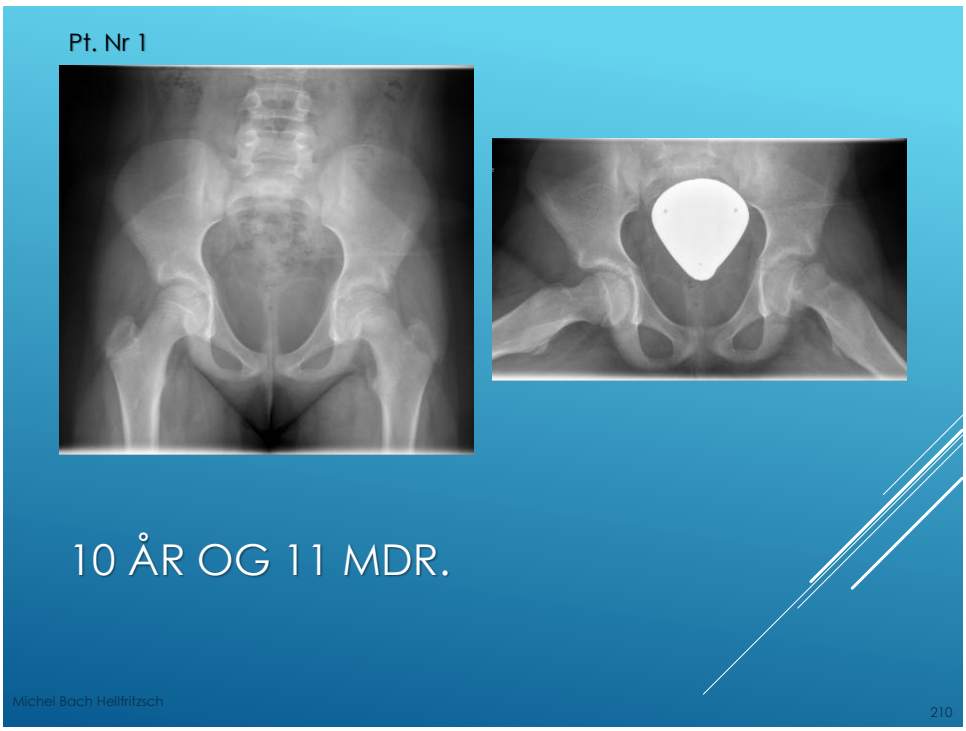
Pt. Nr 1
10 ÅR OG 11 MDR.
Michel Bach Hellfritzsch
210

210

Pt. Nr 1

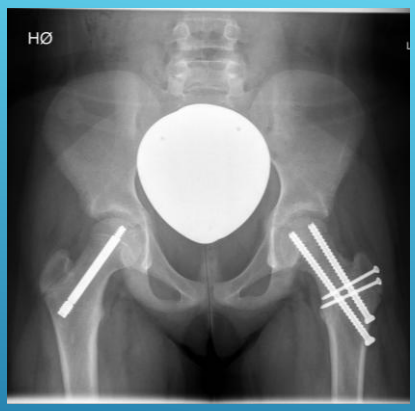

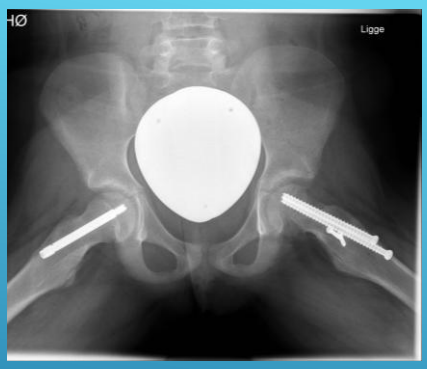

11 ÅR 4 MDR.

211

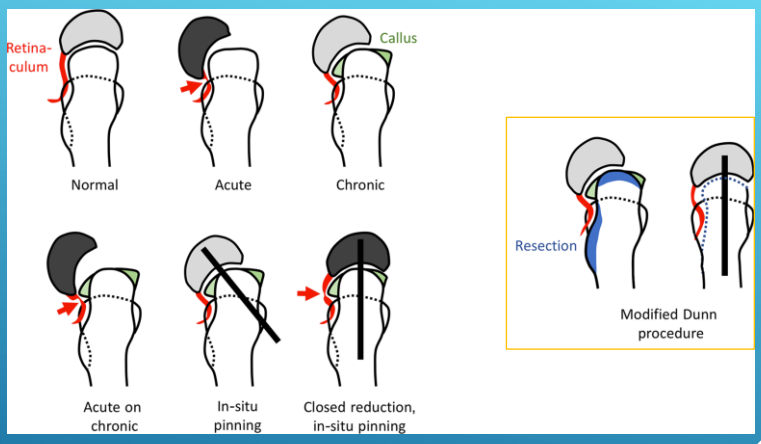

Tannast M, Jost LM, Lerch TD, Schmaranzer F, Ziebarth K, Siebenrock KA. The modified Dunn procedure for slipped capital femoral. *J Child Orthop* 2017;11:138-146. DOI 10.1302/1863-2548.11.170046

212

Pt. Nr 1

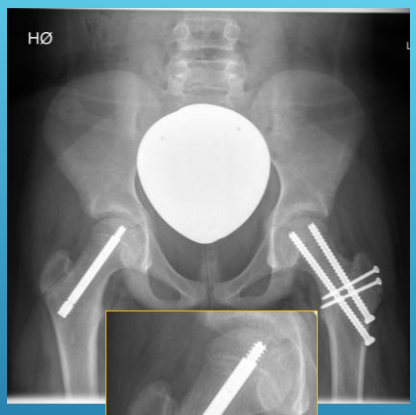



11 ÅR 4 MDR. + 12 ÅR 0 MDR.

Michel Bach Hellfritzsch

213

213

Pt. Nr 2





KONTROL 11DAGE EFTER OP (12ÅR OG 2 MDR.) SAMT KONTROL EFTER 5½ MDR.

Michel Bach Hellfritzsch

214

214

Pt. Nr 2





KONTROL 11DAGE EFTER OP (12ÅR OG 2 MDR.) SAMT KONTROL EFTER 5½ MDR.

Michel Bach Hellfritzsch

215

215

Pt. Nr 3

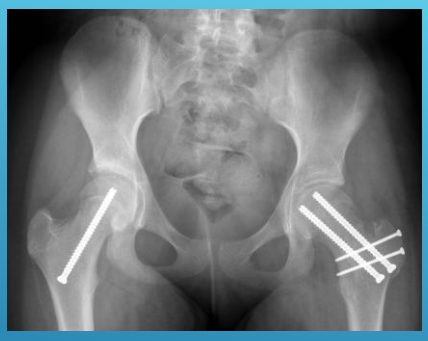

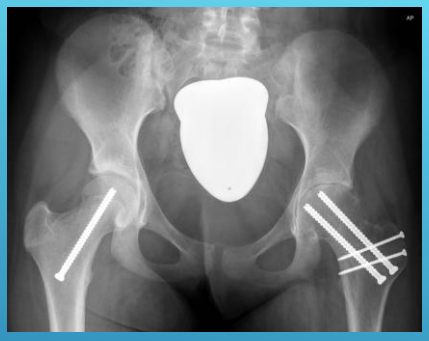

12 ÅR 11 MDR. OG 13 ÅR 6 MDR.

Michel Bach Hellfritzsch

216

216

Pt. Nr 3

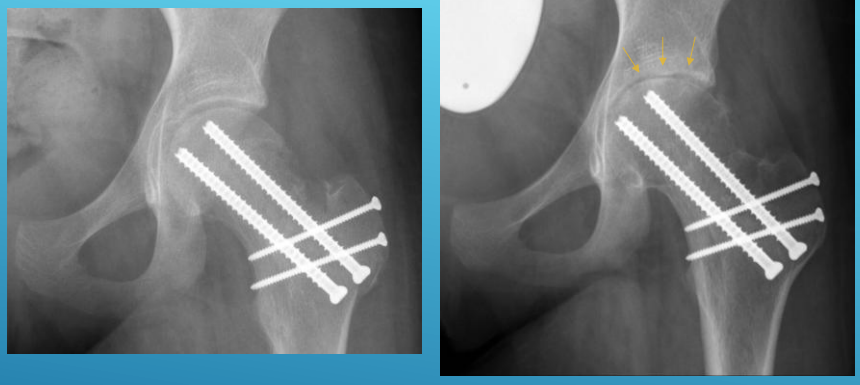

12 ÅR 11 MDR. OG 13 ÅR 6 MDR. CHONDROLYSE

Michel Bach Hellfritzsch

217

217

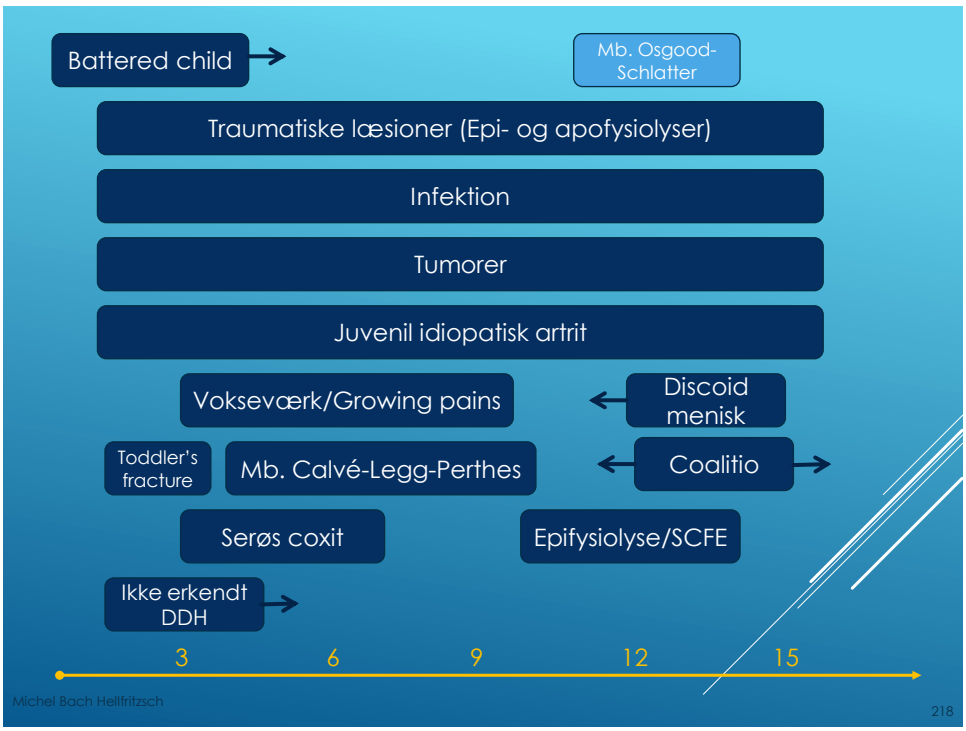

218

LITTERATUR

219



220

BØGER

- Accident & Emergency Radiology – Raby et al., Saunders Elsevier 2015
- Atlas of Normal Roentgen Variants that may simulate Disease – Keats et al, Elsevier 2012
- Bone Dysplasias. An atlas of Genetic Disorders of Skeletal Development – Spranger et al., Oxford University Press 2018
- Borderlands of Normal and Early Pathologic Findings in Skeletal Radiography (Köhler/Zimmer) – Schmidt et al., Thieme 1993 (Findes i 2003 udgave)
- Growth of the Pediatric Skeleton – Oestreich, Springer 2008
- Epiphyseal Growth Plate Fractures – Peterson, Springer 2007

221

BØGER

- Hip Sonography – Graf, Springer 2006
- Imaging skeletal trauma – Rogers et al., Elsevier 2015
- Measurements and Classifications in Musculoskeletal Radiology – Waldt et al., Thieme, 2014
- Pediatric and Adolescent Musculoskelatal MRI – Kan et al., Springer 2010
- Pediatric Orthopedic Imaging – Stein-Wexler et al., Springer 2015
- Radiographic Atlas of Skeletal Maturation – Kahn et al., Thieme 2012
- Skeletal injury in the child – Ogden, Springer 2000

222

ARTIKLER

- Allen et al.: Periosteal pathologic conditions: Imagine findings and pathophysiology, RadioGraphics 2023; 43(2):e220120 - https://doi.org/10.1148/rg.220120
- Anh-Vu et al.: Skeltal Dysplasias: Radiologic Approach with Common and Notable Entities, Semin Musculoskelet Radiol 2018; 22: 66-80
- Chan et al.: MR Imaging of Pediatric Bone Marrow, RadioGraphics 2016; 36:1911-1930
- Dighe et al.: Fetal Skeletal Dysplasia: Am Approach to Diagnosis with Illustative Cases, RadioGraphics 2008; 28: 1061-1077
- Itri et al.: Fundamentals of diagnostic error I imaging, Radiographics 2018; 38: 1845-1861
- Laor and Jaramillo: MR Imaging Insights into Skeletal Maturation, Radiology, Volume 250: No 1January 2009

223

ARTIKLER

- Laor and Jaramillo: It's time to recognize the perichondrum. Pediatric Radiology 2019 https://doi.org/10.1007/s00247-019-04534-x
- Li et al.: Development of the osseous and cartilaginous acetabular index in normal children and those with developmental dysplasia of the hip, J Bone Joint Surg Br 2012; 94-B: 1625-31
- Nguyen et al.: Imaging of Pediatric Growth Plate Disturbances, RadioGraphics 2017; 37:1791–1812 https://doi.org/10.1148/rg.2017170029
- Rana et al.: Periosteal Reactions, AJR 2009; 193: 259-272

224

- Tsai et al.: High-resolution CT with histopathological correlates of the classic metaphyseal leasion of infant abuse. Pediatr Radiol (2014) 44: 124-140
- Zbojniewicz et al.: Focal Periphyseal Edema (FOPE) Zone on MRI of the adolescent Knee: A potentially painful manifestation of physiologic physeal fusion?. ARJ 2011; 197: 998-1004

ARTIKLER

225

- http://omim.org (Syndromer)
- https://www.orthorad.de/index.php/orthorad/pedbone (Normal anatomi - Røntgenbilleder)
- http://cpop.dk (Cerebral parese opfølgningsprogram)

LINKS

226


AO
SURGERY
REFERENCE
Pedbone
APP'S
Michel Bach Hellfritzsch
227

227